

Ultrasound evaluation of forearm arteries in patients undergoing percutaneous coronary intervention via radial artery access: results of one-year follow-up

Jan Przemysław Peruga¹, Jan Zbigniew Peruga², Jarosław D. Kasprzak², Radosław Kręcki², Łukasz Jankowski², Piotr Zając², Michał Plewka²

¹Cardiac Catheterisation Laboratory, Cardiology Unit, Ludwik Perzyna Voivodship Regional Hospital, Kalisz, Poland

²Chair and Department of Cardiology, Medical University of Lodz, Lodz, Poland

Abstract

Background: A proven advantage of radial over femoral arterial access has led to an increase in the number of interventions performed via radial artery access in patients with acute coronary syndromes. Both assessment of the pulse volume and the Allen's test are subjective and subject to investigator bias. An ultrasound examination of the forearm arteries provides important information about the anatomy of the forearm vessels, and indirectly also about the efficiency of collateral blood supply to the hand. It also enables determination of the relevant vessel diameter before the planned intervention, and may be used to assess local complications.

Aim: To assess the morphology of forearm blood vessels and measure the diameter of both radial and ulnar arteries at the cannulation site using ultrasound imaging. We also aimed to identify potential vascular anomalies and local complications associated with radial artery puncture.

Methods: The study included 109 patients with cardiologic indications for coronary angiography or coronary angioplasty. An ultrasound evaluation of forearm arteries was performed prior to the intervention, and the vascular anatomy was later verified by angiography during the procedure. Ultrasound measurements of the vessel diameter were also performed and local complications of the cannulation were assessed. Measurements were performed immediately after the procedure and at 30 days and 12 months.

Results: Fifty-nine right and 50 left forearm arteries were evaluated. Women were 29% of the study population. The mean patient age was 59.2 ± 7.9 years. The mean diameter of the right radial artery was 2.17 ± 0.54 mm, and the mean diameter of the left radial artery was 2.25 ± 0.43 mm. The measurements revealed gender-related differences in forearm artery diameter ($p = 0.003$). Vascular anomalies of the radial artery were identified by ultrasound examination in 10% of subjects. A significant dilatation of the cannulated blood vessel was observed which lasted up to 12 months. An occlusion of the cannulated artery was demonstrated in 6.4% of patients.

Conclusions: Ultrasound imaging is a reliable method to evaluate the diameter of forearm arteries and track their course in patients undergoing invasive cardiovascular procedures via radial artery access. The diameter of the radial artery by ultrasound evaluation is larger compared to that of the ulnar artery. The diameter of forearm arteries in women is smaller compared to men. A dilatation of the radial artery which may last up to 12 months develops following its percutaneous cannulation. Ultrasound imaging allows detection and monitoring of local complications such as radial artery occlusion. An unfavourable ratio of blood vessel diameter to the size of the used introducer sheath is a predictor of radial artery occlusion. Ultrasound imaging enables reliable evaluation of vascular anomalies involving the radial artery, especially within the distal forearm.

Key words: radial artery, cannulation, ultrasound

Kardiol Pol 2015; 73, 7: 502–510

Address for correspondence:

Michał Plewka, MD, PhD, Chair and Department of Cardiology, Medical University of Lodz, ul. Kniaziewiczza 1/5, 91–347 Łódź, Poland, tel/fax: +48 42 653 99 09, e-mail: plewka@ptkardio.pl

Received: 09.05.2014

Accepted: 15.12.2014

Available as AOP: 03.02.2015

Copyright © Polskie Towarzystwo Kardiologiczne

INTRODUCTION

Radial access is the preferred vascular approach for coronary angiography and angioplasty in the current guidelines on the management of acute coronary syndromes (class IIa recommendation, level of evidence B) [1]. Increasing popularity of the radial access is mostly related to the reduced rate of local vascular complications [2]. The multicentre Radial Vs femoral access for coronary intervention trial (RIVAL), using the radial access for the invasive treatment of myocardial infarction (MI), confirmed benefits of this approach in terms of reduced all-cause mortality, strokes, and recurrent MI in a subgroup with ST segment elevation (*post-hoc* analysis) [3]. Similarly in the HORIZONS-AMI study [4], use of the radial access (in 200 patients among 3340 who underwent percutaneous coronary intervention [PCI]) was associated with a reduced rate of bleeding complications and improved outcomes compared to the conventional femoral access. It has also been highlighted that use of the radial access reduces duration of patient immobilisation, with an effect on hospitalisation costs, mid-level staff workload, and increased patient comfort in the periprocedural period [5]. Reported study findings are encouraging, leading to a large increase in the number of procedures. Recently, a Polish randomised OCEAN-RACE study was reported that compared outcomes of angioplasty via the radial vs. femoral approach in ST segment elevation MI (STEMI) patients treated in a reference centre [6].

It has been noted that potential differences with obtaining vascular access using this approach are related not only to operator experience and quality of the equipment used but also to vascular anatomy. Ultrasound evaluation of forearm

arteries may help obtain optimal vascular access, reduce the number of postprocedural complications, and allow their earlier detection.

The aim of this study was to perform population ultrasound evaluation of radial and ulnar artery diameter and the presence and types of vascular anomalies, and to evaluate post-cannulation complications found by transcatheter ultrasound during 1-year follow-up in a group of patients undergoing coronary angiography and angioplasty using the radial access.

METHODS

We studied patients treated in a hospital in Kalisz, in whom coronary angiography and/or PCI was recommended following non-invasive investigations. Right- or left-sided cannulation was chosen randomly to allow evaluation of the anatomical variants. Among 110 patients selected for the study, 1 patient required conversion to the femoral access and was not included in the statistical analysis. Thus, the success rate of obtaining radial vascular access was 99%. The final analysis included 109 patients who fulfilled the criteria and gave their informed consent for participation in the study. The study protocol was approved by the Bioethics Committee at the Medical University of Lodz (approval No. RNN/176/13/KE).

The study group included 32 (29%) women and 77 (71%) men. Basic demographic data and selected risk factors for coronary artery disease and atherosclerosis are shown in Tables 1 and 2. Differences in selected risk factors for atherosclerosis between patients cannulated using the right- or left-sided access were not significant.

Table 1. Demographic characteristics of the study group

Demographic variables	Mean	Minimum	Maximum	Standard deviation
Age	59.2	31	78	± 7.9
Height	166.3	148	186	± 9.0
Weight	83.9	51	142	± 17.3
Body mass index	30.6	20	54	± 5.7

Table 2. Risk factors for coronary artery disease in the study group

Risk factor for atherosclerosis/ /coronary artery disease	Prevalence in the overall study group	P (men vs. women)	Prevalence in the right radial artery subgroup	Prevalence in the left radial artery subgroup	P (left vs. right)
Current smoking	18 (16.7%)	0.4	12 (20%)	6 (12%)	0.24
Previous smoking	66 (60.6%)	0.89	35 (59%)	31 (62%)	0.78
Hypercholesterolaemia	85 (78%)	0.89	46 (78%)	39 (78%)	0.99
Hypertension	91 (83.5%)	0.15	50 (85%)	50 (100%)	0.70
Positive family history	27 (24.8%)	0.38	16 (27%)	11 (22%)	0.54
Diabetes	31 (28.4%)	0.86	19 (32%)	12 (24%)	0.34
Previous cardiovascular event	54 (49.5%)	0.33	30 (51%)	24 (48%)	0.77

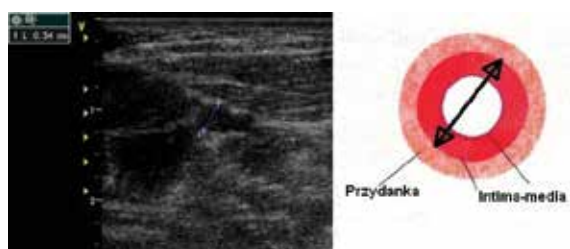


Figure 1. Measurement of the forearm artery diameter

Ultrasound evaluation

Arterial ultrasound evaluation was performed using a ViViD 7 GE system (General Electronic Medical System, 2004) with a vascular linear 9–12 MHz probe. All examinations were performed by the same ultrasonographer (J.P.). Analysis included 59 right-sided and 50 left sided forearm arteries. Radial and ulnar artery transverse diameter was measured at about 1–3 cm from the wrist joint line. Measurements were performed with consideration of the hypoechoic vascular area in the transverse cross-section (Fig. 1), and morphological evaluation was undertaken in transverse, longitudinal, and complex views until junction with the ulnar artery.

To provide uniform conditions of vessel diameter measurement, eliminate diameter changes related to the degree of vasodilatory endothelial function, and obtain maximal diameter values, evaluation was performed during flow-mediated dilatation after limb ischaemia. We used a standard test to evaluate arterial vasodilatation in response to ischaemia which is employed to assess endothelial function [7]. Blood pressure cuff was placed on an arm and inflated to 50 mm Hg over the systolic blood pressure for 5 min. Diameter measurements were performed immediately after cuff release. Anatomical evaluation involved searching for vascular anomalies, such as high origin of the radial artery and its early division, i.e., mostly commonly origin of the palmar superficial branch above the wrist line, and origin of the radial artery from the brachial artery above the elbow joint line [8]. The diagnosis of a vascular anomaly was verified angiographically during artery cannulation. Ultrasound measurements of forearm vessels were performed before the cannulation (P0), within 24 h after the cannulation (P1), and at 30 days (P2) and 12 months after the procedure (P3). We also evaluated occurrence of radial artery occlusion (RAO) during 12-month follow-up after the cannulation.

Radial artery cannulation

Angiography was performed using an Artis ZEE system (Siemens). All procedures were performed by the same operator (J.P.) with experience in radial artery cannulation (about 6000 procedures). Radial artery cannulation for coronary angiography was performed using 5 F and 6 F Terumo introducer sheaths (external diameter 2.28 mm and 2.62 mm,

respectively). The choice of introducer sheath size was made by the operator based on arterial pulse palpation and the expected procedure type. Overall, 20 angioplasty and 89 coronary angiography procedures were performed using 53 5 F introducer sheaths and 56 6 F introducer sheaths. Unfractionated heparin was given intravenously during the procedures (initial dose 5000 U, with subsequent dosing based on activated clotting time measurements).

Haemostasis was provided with a haemostatic band (TR Band, Terumo Interventional Systems). Band pressure release procedure and the duration of compression were the same in all patients.

Statistical analysis

The Shapiro-Wilk test was used to verify normal distribution of the quantitative variables in the study. Normally distributed variables were reported as mean values \pm standard deviation. Qualitative variables were reported as numbers and percentages. $P < 0.05$ was considered statistically significant.

RESULTS

Results of serial measurements of the radial artery diameter at the site typical for cannulation are summarised separately for the left and right side in Table 3. Measurement of the ulnar artery diameter are summarised in Table 4.

A significant increase in the radial artery diameter by ultrasound evaluation was found after the procedure compared to baseline values, with the highest diameter obtained at P1 measurement (within 24 h after the procedure, $p < 0.0001$) followed by P2 ($p < 0.0001$) and P3 ($p = 0.0057$) measurements. Figures 2 and 3 show the mean vessel diameter at P0, P1, P2, and P3. The left and right ulnar artery diameter at P0 was lower compared to the radial artery ($p = 0.0114$ for the right side and $p = 0.0004$ for the left side). The diameter of forearm arteries in subsequent measurements is shown in Figure 4.

The study group was evaluated in subgroups defined based on demographic variables including female gender, presence of diabetes, hypertension, and body mass index (BMI) ≥ 30 kg/m². The radial artery diameter was significantly lower in the studied women ($p = 0.0003$).

In a separate analysis for right and left forearm arteries, the relation between lower vessel diameter and gender was significant for the right radial artery ($p = 0.0001$) and the left ulnar artery ($p = 0.0260$). The diameter of the right radial artery in relation to the remaining demographic variables is shown in Table 5.

Table 6 shows the numbers and proportions of radial arteries with the diameter measured by ultrasonography that was theoretically adequate for 5 F, 6 F, and 7 F (2.95 mm) introducer sheaths. In our study, 5 F introducer sheath was suitable in 25 (23%) patients, and 6 F introducer sheath in only 16 (15%) patients. During 68 (62%) procedures the diameter

Table 3. Diameter of the right and left radial artery at the cannulation site

Timing of measurement	Overall	Mean	SD	Lower quartile	Upper quartile
Right side					
P0	59	2.17	± 0.54	1.8	2.5
P1	59	2.64	± 0.49	2.3	2.9
P2	59	2.54	± 0.47	2.3	2.8
P3	59	2.31	± 0.53	2.1	2.6
Left side					
P0	50	2.25	± 0.43	1.9	2.6
P1	50	2.71	± 0.46	2.4	3.0
P2	50	2.68	± 0.44	2.4	2.9
P3	50	2.47	± 0.44	2.2	2.8

P0 — baseline measurement before the invasive procedure; P1 — measurement within 24 h after the procedure; P2 — measurement at 1 month; P3 — measurement at 12 months; SD — standard deviation

Table 4. Ulnar artery diameter

Timing of measurement	Overall	Mean	SD	Upper quartile	Lower quartile
Right side					
P0	59	1.93	± 0.47	1.6	2.3
P1	59	2.01	± 0.44	1.8	2.4
P2	59	1.95	± 0.44	1.6	2.2
P3	59	1.98	± 0.44	1.6	2.2
Left side					
P0	50	1.96	± 0.37	1.7	2.2
P1	50	2.00	± 0.38	1.8	2.2
P2	50	2.04	± 0.34	1.8	2.2
P3	50	2.05	± 0.35	1.8	2.3

P0 — baseline measurement before the invasive procedure; P1 — measurement within 24 h after the procedure; P2 — measurement at 1 month; P3 — measurement at 12 months; SD — standard deviation

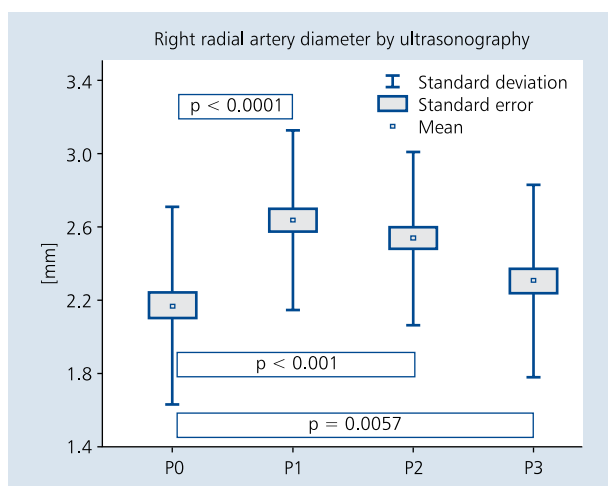


Figure 2. Right radial artery diameter in subsequent measurements; P0 — baseline measurement before the invasive procedure; P1 — measurement within 24 h after the procedure; P2 — measurement at 1 month; P3 — measurement at 12 months

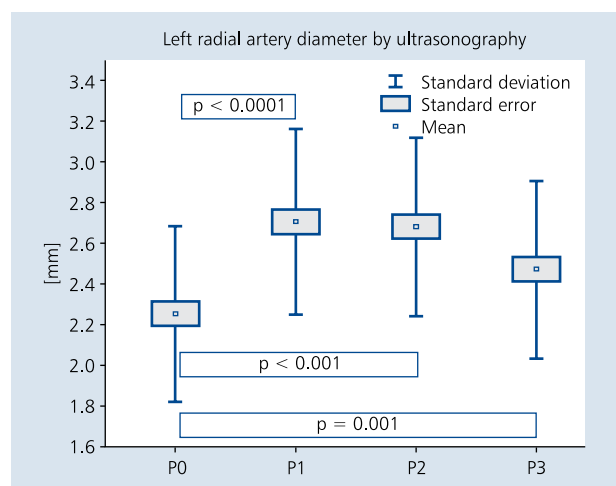


Figure 3. Left radial artery diameter in subsequent measurements; P0 — baseline measurement before the invasive procedure; P1 — measurement within 24 h after the procedure; P2 — measurement at 1 month; P3 — measurement at 12 months

of the radial artery did not exceed the external diameter of the introducer sheath. With theoretical choice of the introducer sheath based on the ultrasound measurement of the vessel diameter, only 37 (33.9%) patients would not fulfil the criterion for a 5 F introducer sheath. The procedure would be theoretically safe with the use of a 7 F introducer sheath in only 6 (5%) patients.

We also evaluated the increase in the vessel diameter in relation to the size of the introducer sheath used (5 F or 6 F)

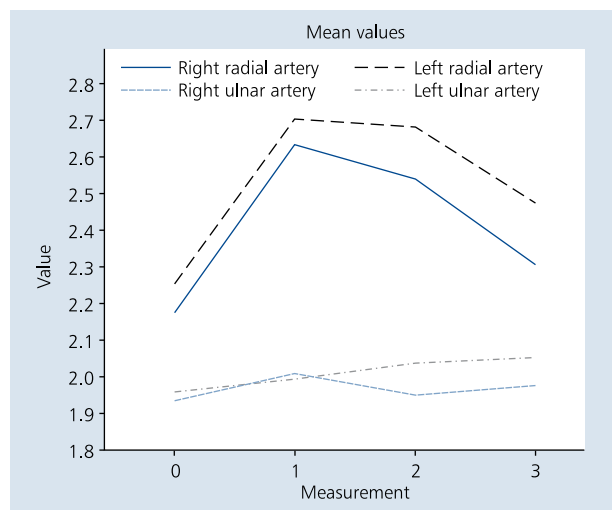


Figure 4. Diameter changes (values in mm) at subsequent measurements 0, 1, 2, and 3

(Table 7). We did not show a larger postprocedural increase in the vessel diameter following use of standard 6 F introducer sheaths compared to smaller 5 F introducer sheaths.

Ultrasonography identified 3 cases of vascular anomalies in a form of a high origin of the superficial palmar branch from the radial artery within the forearm (Fig. 5). All these anomalies were confirmed by angiography. Based on ultrasound evaluation, a high origin of the radial artery was diagnosed in 7 cases, and angiography identified one more case of this anomaly (n = 8).

Ultrasound evaluation showed 7 cases of post-cannulation RAO at P1, with spontaneous recanalisation in 1 patient

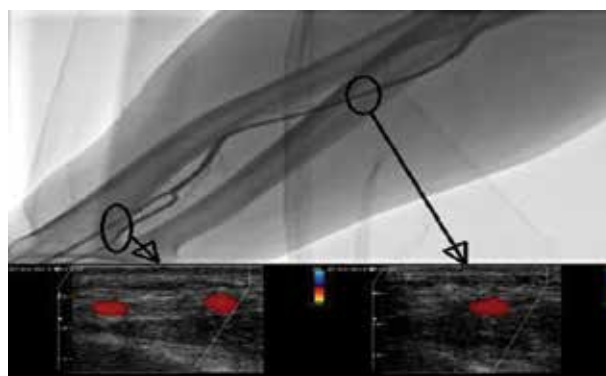


Figure 5. High origin of the superficial ulnar artery within the forearm. Angiographic image (upper panel) and corresponding transverse sections in ultrasonography (lower panel)

Table 5. Right and left radial artery diameter at P0 measurement in patient subgroups

Variable	Right-sided cannulation	P	Left-sided cannulation	P	Cannulation overall	P
Female gender	21 (1.82 mm)	0.0001	12 (2.05 mm)	0.0718	33 (1.90 mm)	0.0003
Diabetes	19 (2.15 mm)	0.5872	12 (2.0 mm)	0.1673	31 (2.09 mm)	0.34415
Hypertension	50 (2.16 mm)	0.6417	41 (2.25 mm)	0.7028	91 (2.20 mm)	0.70046
Body mass index $\geq 30 \text{ kg/m}^2$	30 (2.10 mm)	0.4473	21 (2.22 mm)	0.4671	51 (2.15 mm)	0.44737

Table 6. Theoretical possibilities of fitting an introducer sheath used during cannulation in relation to the vessel diameter by ultrasonography

Number of arteries smaller than 5 F size	Number of arteries with the size of at least 5 F	Number of arteries with the size of at least 6 F	Number of arteries with the size of at least 7 F
37 (33.9%)	72 (66.1%)	16 (14.6%)	6 (5.5%)

Table 7. The increase in vessel diameter in mm in relation to the size of the introducer sheath used (5 F or 6 F)

	5 F introducer sheath	6 F introducer sheath	P
Increase in the diameter (P1 minus P0) of the right radial artery	0.5172	0.4167	0.2443
Increase in the diameter (P1 minus P0) of the left radial artery	0.4667	0.4400	0.8125

Table 8. Clinical and ultrasonographic characteristics of 8 patients with the diagnosis of radial artery occlusion (RAO)

Patient	P1	P2	P3	Pain at the cannulation site	Vascular anomaly	Vessel diameter/ /introducer sheath ratio
1	RAO	Recanalisation	Recanalisation	Yes	No	0.53
2	RAO	RAO	Recanalisation	No	No	1.00
3	–	RAO	RAO	No	Yes	1.09
4	RAO	RAO	RAO	Yes	Yes	0.72
5	RAO	RAO	RAO	Yes	No	1.06
6	RAO	RAO	RAO	No	No	0.61
7	RAO	RAO	RAO	Yes	No	0.64
8	RAO	RAO	RAO	No	No	0.57

P0 — baseline measurement before the invasive procedure; P1 — measurement within 24 h after the procedure; P2 — measurement at 1 month; P3 — measurement at 12 months

at P2 and in another one at P3. Overall, temporary vessel occlusion occurred in 7.3% of patients, and permanent vessel occlusion at 12 months of follow-up was identified in 5.5% of patients. Clinical and ultrasonographic characteristics of the 8 patients with RAO are summarised in Table 8.

Half of patients with RAO did not report pain at the site of radial artery cannulation. In 6 patients, the size of standard introducer sheath used was greater than or equal to the artery diameter measured by ultrasonography.

We calculated the odds ratio (OR) of RAO and the mismatch between vessel diameter and introducer sheath size (OR 0.66) and other known prognostic factors analysed in the present study: diabetes (OR 0.36) and cigarette smoking (OR 0.38). We did not assess the effect of duration and intensity of postprocedural haemostatic compression due to the fact that these factors were the same in all patients. The distribution of the analysed anomalies and RAO was similar on both sides, with RAO on the right side in 4 patients and on the left side in 4 patients. High origin/early division was seen on the right side in 6 patients and on the left side in 5 patients. Duration of fluoroscopy and total procedure duration did not differ between the procedures performed via the right-sided vs. left-sided radial access ($p = 0.828$ and $p = 0.927$, respectively).

Local complications including pseudoaneurysm, arteriovenous fistula, and haematoma within the muscular compartment following arterial perforation were not observed in the study group by both clinical and ultrasound evaluation.

DISCUSSION

The study reports results of ultrasound evaluation of forearm arteries in patients undergoing PCI via radial artery access. According to our knowledge, it is the first comprehensive publication reporting on this issue in Polish patients.

Population studies indicate that the mean diameter of the radial artery at the typical cannulation site may show geographic variation. In a large group ($n = 846$) of Chinese

referred for cardiac invasive procedures via radial artery access, the mean diameter of previously uncannulated radial artery was 2.37 ± 0.55 mm [9]. The mean age of these patients was 53.7 ± 12.8 years, 62.6% of them were men, and the mean BMI was 26 kg/m^2 . In the study by Velasco et al. [10] in young volunteers in Texas, the right radial artery was evaluated in 100 subjects (40% men) at the mean age of 35 years and with the mean BMI of 27 kg/m^2 . The mean vessel diameter was 2.22 ± 0.35 mm. A larger vessel diameter was shown to correlate with higher BMI and the male gender. In a population study in Pakistan, reported by Ashraf et al. [11], the mean diameter of the right and left radial artery was 2.3 ± 0.4 mm and 2.2 ± 0.4 mm, respectively. In a study from Singapore, the mean diameter of the radial artery was 2.45 ± 0.45 mm, and in a Korean study it was 2.60 ± 0.41 mm [12, 13].

In our study, the mean diameter was 2.17 ± 0.53 mm for the right radial artery, 2.25 ± 0.43 mm for the left radial artery, 1.93 ± 0.47 mm for the right ulnar artery, and 1.9 ± 0.37 mm for the left ulnar artery, and thus these vessels were smaller compared to the Asian population. We found that the diameter of the right radial artery and the right ulnar artery was related to gender, with a similar trend for the left radial artery. It is possible that a small proportion of women among patients undergoing left-sided cannulation ($n = 12$) resulted in a decreased statistical power of the effect of gender on the diameter of left forearm arteries. The presence of risk factors for atherosclerosis had no significant effect. Of note, we did not see a difference in the radial artery size among patients with BMI above 30 kg/m^2 .

In the present study, we observed a significant postprocedural enlargement of the vessel diameter by ultrasound compared to baseline values. The highest values were seen at P1, followed by P2 and some diameter reduction at P3 (12 months after the procedure). Compared to baseline values, the vessel diameter after the procedure was increased by about 22%. The phenomenon of vessel dilatation following introduction of a catheter has not been fully elucidated. It is

believed that due to ischaemia, the release of and susceptibility to nitric oxide (NO) is reduced, related to an increase in shear stress [14]. Vessel size and function changes following cannulation are also explained by mechanical damage to the endothelium and media. The pathophysiology of this phenomenon is believed to resemble vessel remodelling following coronary angioplasty. Studies using intravascular ultrasound confirmed postprocedural intimal hypertrophy in 67% of cases, and optical coherence tomography showed intimal tears and dissection of the media in 36% of cases [15]. Radial artery remodelling involving thickening of the intima-media complex, altered response of the damaged endothelium to vasodilatory drugs (nitroglycerin), and reduced flow-mediated dilatation were already shown in previous studies [16]. Vessel dilatation as seen by ultrasound may result from an increase in the external diameter of the measured vessel, with thickening of the intima-media complex and maintaining the previous size of the vessel lumen.

Increased vessel size may be related to activation of the endothelial NO synthase (eNOS) gene, resulting in a permanent increase in NO level. Increased inflammatory response related to an increase in acute phase proteins was shown, which may confirm the importance of mechanical vessel damage following radial artery cannulation [17].

This phenomenon may involve the entire radial artery and sometimes also brachial artery, resulting from intravascular exchange of catheters of similar sizes [18].

Although no effect of this pathology on the success rate of future procedures, quality of life, and hand dexterity was shown, it has a negative effect on the long-term patency of a previously cannulated radial artery used as a bypass graft [19].

In the present study, we diagnosed 8 cases of RAO following coronary angiography or PCI. Six of these patients (75%) were characterised by an unfavourable ratio of the vessel diameter to the introducer sheath size, with ultrasound measurements indicating that the vessel diameter was smaller than or equal to the size of routinely used introducer sheath. It may be expected that using a smaller introducer sheath, selected based on ultrasound measurements, might decrease the risk of postprocedural vessel occlusion.

This was confirmed by the study of Saito et al. [20] who showed that RAO was more frequent among those subjects in whom baseline vessel diameter was smaller than the size of the used introducer sheath. The role of factors increasing the risk of intravascular coagulation following cannulation has also been highlighted, including diabetes, smoking, prolonged procedure duration, and prolonged local compression to provide local haemostasis. In the present study, the same protocol of obtaining haemostasis by using a dedicated compression band was used in all patients, which may limit the applicability of our findings for the general population, as

the use of haemostatic bands has not been a standard clinical practice in all centres.

Based on the literature data, the incidence of RAO is 5–30% [2], and in our study it was 6.4%. Ultrasound examination allowed identification of this complication. It was shown that the early diagnosis of postprocedural vessel occlusion and initiation of low molecular weight heparin treatment according to the present recommendations increases the recanalisation rate to 55.6% compared to 13.5% ($p < 0.001$) in case of spontaneous recanalisation [21].

For prevention of RAO, it is possible to determine the radial artery diameter before the procedure and use an appropriately sized introducer sheath. It is even acceptable to use 7 F and 8 F introducer sheaths, if allowed based on the vessel size evaluated by ultrasonography or angiography [22]. In our study, 62% of patients did not fulfil the criterion of vessel size for the routinely used introducer sheath.

The prevalence of radial artery anomalies has been estimated at 4.3–9% [23]. The most common variant, seen in up to 7% of subjects, is a high origin of the radial artery at the level of the humerus or even in the subclavian area [24]. In such cases, the artery runs subcutaneously above or directly under the arm and forearm fascia. Use of ultrasound imaging allowed 100% identification of a vascular anomaly of the distal forearm, involving a high origin of the superficial palmar branch from the radial artery already within the forearm, which was diagnosed in 2.7% of cases ($n = 3$). The distribution of RAO and radial artery anomalies on the left and right side was similar. The sensitivity of ultrasound imaging in the diagnosis of a high origin of the radial artery was high (87%). This is of importance, as an elongated course of the radial artery predisposes to its tortuosity and is considered one of the most common causes of radial access failure, along with vasospasm [25].

CONCLUSIONS

Ultrasound imaging is a reliable method to evaluate the diameter of forearm arteries and track their course in patients undergoing invasive cardiovascular procedures via radial artery access. The diameter of the radial artery by ultrasound evaluation is larger compared to that of the ulnar artery. The diameter of forearm arteries in women is smaller compared to men. A dilatation of the radial artery which may last up to 12 months develops following its percutaneous cannulation. Ultrasound imaging allows detection and monitoring of local complications such as radial artery occlusion. An unfavourable ratio of blood vessel diameter to the size of the used introducer sheath is a predictor of radial artery occlusion. Ultrasound imaging enables reliable evaluation of vascular anomalies involving the radial artery, especially within the distal forearm.

Conflict of interest: none declared

References

1. Steg PG, James SK, Atar D et al. Wytyczne ESC dotyczące postępowania w ostrym zawale serca z przetrwałym uniesieniem odcinka ST. *Kardiologia Polska*, 2012; 70 (suppl. VI): 255–318.
2. Agostoni P, Biondi-Zoccai GG, de Benedictis ML et al. Radial versus femoral approach for percutaneous coronary diagnostic and interventional procedures; systematic overview and meta-analysis of randomized trials. *J Am Coll Cardiol*, 2004;44: 349–356.
3. Jolly SS, Yusuf S, Cairns J et al. Radial versus femoral access for coronary angiography and intervention in patients with acute coronary syndromes (RIVAL): a randomised, parallel group, multicentre trial. *Lancet*, 2011; 377: 409–420.
4. Génèreux Ph, Mehran R, Palmerini T et al. Radial access in patients with ST-segment elevation myocardial infarction undergoing primary angioplasty in acute myocardial infarction: the HORIZONS-AMI trial. *EuroIntervention*, 2011;7: 905–916.
5. Amoroso G, Sarti M, Bellucci R et al. Clinical and procedural predictors of nurse workload during and after invasive coronary procedures: the potential benefit of a systematic radial access. *Eur J Cardiovasc Nurs*, 2005; 4: 234–241.
6. Kołtowski L, Filipiak KJ, Kochman J, et al. Access for percutaneous coronary intervention in STEMI: radial vs. femoral — prospective, randomized clinical trial — OCEAN RACE trial. *Kardiologia Polska*, 2014; 72: 604–611.
7. Moens AL, Goovaerts I, Claeys MJ et al. Flow-mediated vasodilatation: a diagnostic instrument, or an experimental tool? *Chest*, 2005; 127: 2254–2263.
8. McCormack LJ, Cauldwell EW, Anson BJ et al. Brachial and antebrachial arterial patterns; a study of 750 extremities. *Surg Gynecol Obstet*, 1953; 96: 43–54.
9. Nie B, Zhou YJ, Yang Q, et al. Safety and feasibility of repeated percutaneous transradial coronary intervention in the same route. *Chin Med J (Engl)*, 2012; 125: 221–225.
10. Velasco A, Ono C, Nugent K et al. Ultrasonic evaluation of the radial artery diameter in a local population from Texas. *J Invasive Cardiol*, 2012; 24: 339–341.
11. Ashraf T, Panhwar Z, Habib S et al. Size of radial and ulnar artery in local population. *J Pak Med Asso*, 2010; 60: 817–819.
12. Loh YJ, Nakao M, Tan WD et al. Factors influencing radial artery size. *Asian Cardiovasc Thorac Ann*, 2007; 15: 324–326.
13. Yan ZX, Zhou YJ, Zhao YX et al. Anatomical study of forearm arteries with ultrasound for percutaneous coronary procedures. *Circ J*, 2010; 74: 686–692.
14. Mitchell G.F., Parise H., Vita J.A. et al. Local shear stress and brachial artery flow-mediated dilatation: the Framingham Heart Study. *Hypertension*, 2004; 44: 134–139.
15. Yonetsu T, Kakuta T, Lee T et al. Assessment of acute injuries and chronic intimal thickening of the radial artery after transradial coronary intervention by optical coherence tomography. *Eur Heart J*, 2010; 31: 1608–1615.
16. Madssen E, Haere P, Wiseth R. Radial artery diameter and vasodilatory properties after transradial coronary angiography. *Ann Thorac Surg*, 2006; 82: 1698–1702.
17. Di Serafino L, Pyxaras S, Mangiacapra F et al. Influence of transradial versus transfemoral diagnostic heart. *EuroIntervention*, 2013; 8: 1252–1258.
18. Heiss C, Balzer J, Hauffe T et al. Vascular dysfunction of brachial artery after transradial access for coronary catheterization. *J Am Coll Cardiol Cardiovasc Interv*, 2009; 11: 1067–1073.
19. Kamiya H, Ushijima T, Kanamori T et al. Use of the radial artery graft after transradial catheterization: is it suitable as a bypass conduit? *Ann Thorac Surg*, 2003; 58: 1505–1509.
20. Saito S, Ikei H, Hosokawa G, Tanaka S. Influence of the ratio between radial artery inner diameter and sheath outer diameter on radial artery flow after transradial coronary intervention. *Catheter Cardiovasc Interv*, 1999;46: 173–178.
21. Uhlemann M, Möbius-Winkler S, Mende M et al. The Leipzig prospective vascular ultrasound registry in radial artery catheterization: impact of sheath size on vascular complications. *J Am Coll Cardiol Cardiovasc Interv*, 2012; 5: 36–43.
22. Rao SV, Ou FS, Wang TY et al. Trends in the prevalence and outcomes of radial and femoral approaches to percutaneous coronary intervention: a report from the National Cardiovascular Data Registry. *J Am Coll Cardiol Cardiovasc Interv*, 2008; 4: 379–386.
23. Uglietta JP, Kadir S. Arteriographic study of variant arterial anatomy of the upper extremities. *Cardiovasc Intervent Radiol*, 1989; 12: 145–148.
24. Icten N, Süllü Y, Tuncer I. Variant high-origin radial artery: a bilateral case. *Surg Radiol Anat*, 1996; 18: 63–66.
25. Pristipino C, Roncella A, Trani C et al. Prospective Registry of Vascular Access in Interventions in Lazio region (PREVAIL) study group. Identifying factors that predict the choice and success rate of radial artery catheterisation in contemporary real world cardiology practice. *EuroIntervention*, 2010; 6: 240–246.

Ocena ultrasonograficzna tętnic przedramienia u chorych kwalifikowanych do przezskórnych zabiegów wieńcowych z dostępu promieniowego: obserwacja jednoroczna

Jan Przemysław Peruga¹, Jan Zbigniew Peruga², Jarosław D. Kasprzak², Radosław Kręcki²,
Łukasz Jankowski², Piotr Zając², Michał Plewka²

¹Pracownia Hemodynamiki, Oddział Kardiologiczny, Wojewódzki Szpital Zespolony im. Ludwika Perzyny, Kalisz

²Katedra i Klinika Kardiologii, Uniwersytet Medyczny w Łodzi, Łódź

Streszczenie

Wstęp: Wykazanie przewagi dostępu promieniowego nad udowym u chorych z ostrymi zespołami wieńcowymi leczonych przezskórną angioplastyką wieńcową spowodowało wzrost liczby procedur wykonywanych tym sposobem. Ocena tętna i przeprowadzenie testu Allena są obarczone błędem wynikającym z subiektywnej oceny badacza. Ultrasonografia tętnic przedramienia przynosi informację o anatomii naczyń przedramienia i sprawności podwójnego ukrwienia dłoni, pozwala uzyskać dane o średnicy naczyń przed planowanym zabiegiem oraz rozpoznać i monitorować powikłania miejscowe.

Cel: Celem pracy była ocena ultrasonograficzna morfologii naczyń przedramienia z pomiarem średnicy tętnicy promieniowej i łokciowej w miejscu ich kaniulacji oraz poszukiwanie anomalii naczyniowych i powikłań miejscowych po nakłuciu tętnicy promieniowej, ocenianych ultrasonograficznie.

Metody: Do badania zakwalifikowano 109 pacjentów ze wskazaniami kardiologicznymi do wykonania koronarografii lub koronaroplastyki. U wszystkich przeprowadzono ocenę ultrasonograficzną tętnic przedramienia poprzedzającą zabieg oraz zweryfikowano anatomię w angiogramie w czasie zabiegu. Po kaniulacji oceniano ultrasonograficznie średnicę naczyń i obecność powikłań. Badania wykonywano bezpośrednio po zabiegu, po 30 dniach i po 12 miesiącach.

Wyniki: Przebadano 59 prawych i 50 lewych tętnic przedramienia. W całej grupie średnia wieku wynosiła $59,2 \pm 7,9$ roku, 29% stanowiły kobiety. Uzyskano parametry populacyjne średnicy prawej tętnicy promieniowej — $2,17 \pm 0,54$ mm i lewej tętnicy promieniowej — $2,25 \pm 0,43$ mm. Wykazano zależność średnicy tętnic przedramienia od płci ($p = 0,003$). W 10% za pomocą badania ultrasonograficznego wykazano anomalie naczyniowe tętnicy promieniowej. Zaobserwowano istotne poszerzenie naczyń użytego do zabiegu utrzymujące się do 12 miesięcy. U 6,4% pacjentów stwierdzono zamknięcie tętnicy poddanej kaniulacji.

Wnioski: Ultrasonografia jest wiarygodną metodą pozwalającą na ocenę średnicy i przebiegu tętnic przedramienia u chorych poddawanych zabiegom kardiologii inwazyjnej z dostępu promieniowego. Średnica tętnicy promieniowej ocenianej ultrasonograficznie jest większa niż tętnicy łokciowej. Średnica tętnic przedramienia po stronie prawej jest mniejsza u kobiet niż u mężczyzn. Po zabiegu kaniulacji tętnicy promieniowej dochodzi do jej poszerzenia, utrzymującego się do 12 miesięcy. Ocena ultrasonograficzna pozwala wykryć i monitorować powikłania miejscowe pod postacią okluzji tętnicy promieniowej. Predyktorem okluzji tętnicy promieniowej jest niekorzystny stosunek średnicy naczyń do użytej koszulki naczyniowej. Ultrasonografia pozwala wiarygodnie ocenić anomalie naczyniowe tętnicy promieniowej, zwłaszcza dystalnego odcinka przedramienia.

Słowa kluczowe: tętnica promieniowa, kaniulacja, ultrasonografia

Kardiol Pol 2015; 73, 7: 502–510

Adres do korespondencji:

dr hab. n. med. Michał Plewka, Klinika Kardiologii, Katedra Kardiologii, Uniwersytet Medyczny w Łodzi, Szpital im. Wł. Biegańskiego, ul. Kniaziewiczka 1/5, 91-347 Łódź, tel/faks: +48 42 653 99 09, e-mail: plewka@ptkardio.pl

Praca wpłynęła: 09.05.2014 r.

Zaakceptowana do druku: 15.12.2014 r.

Data publikacji AoP: 03.02.2015 r.