

Idiopathic ventricular arrhythmia in children and adolescents: early effectiveness of radiofrequency current ablation

Maria Miszczak-Knecht¹, Łukasz Szumowski², Maria Posadowska³, Monika Brzezińska-Paszke¹, Katarzyna Pręgoska³, Franciszek Walczak², Anna Turska-Kmieć¹, Katarzyna Bieganowska⁴

¹Department of Cardiology, Children's Memorial Health Institute, Warsaw, Poland

²Department of Cardiac Arrhythmia, Institute of Cardiology, Warsaw-Anin, Poland

³Children's Memorial Health Institute, Warsaw, Poland

⁴Clinical Electrophysiology Laboratory, Children's Memorial Health Institute, Warsaw, Poland

Abstract

Background and aim: The aim of the study was to evaluate early effectiveness of radiofrequency (RF) current ablation for idiopathic ventricular arrhythmia (iVA) in children and to identify factors affecting treatment results.

Methods: Among over 600 children, 30 ablation procedures were performed for iVA. Patient age ranged from 2.0 to 17.9 years (mean 14.7 ± 3.1). We analysed arrhythmia recurrences at 24 h and the effect of patient age, arrhythmia location, type of anaesthesia, and the presence of spontaneous arrhythmia during the procedure on the treatment results.

Results: Sixteen (53%) children had right ventricular (RV) arrhythmia, including RV outflow tract arrhythmia in 9 of them (56%). In 14 (47%) children, arrhythmia was located in the left ventricle (LV), including LV outflow tract in 2 children, and the posterior fascicle in 4 children. The procedure was effective in 13 (81%) children in the RV arrhythmia group and in 11 (78%) children in the LV arrhythmia group, including all children with fascicular tachycardia. The only variable that affected the treatment results was the presence of spontaneous arrhythmia during the procedure ($p = 0.012$). No procedural complications were noted.

Conclusions: RF current ablation of iVA is a safe procedure with high early effectiveness. The only variable that affected the treatment results was the presence of spontaneous arrhythmia during the procedure.

Key words: idiopathic ventricular arrhythmia, children, CARTO ablation

Kardiol Pol 2014; 72, 11: 1148–1155

INTRODUCTION

In children and adolescents, ventricular arrhythmia is often identified during physician examination during health supervision visits or before vaccinations. Cardiac causes of ventricular arrhythmia in children include genetic diseases (long QT syndrome, catecholaminergic polymorphic ventricular tachycardia), cardiomyopathies, cardiac tumours, and congenital heart disease. However, ventricular arrhythmia is idiopathic in nature in about 50% of children and adolescents. Among adult patients, in whom ventricular arrhythmia is mostly related to ischaemic heart disease, only 10–20% of cases are idiopathic [1]. Idiopathic ventricular arrhythmia (iVA)

in children is mostly asymptomatic and thus its prevalence in the general population is difficult to establish. Screening resting electrocardiographic (ECG) studies in asymptomatic school-age Japanese children, reported by Iwamoto et al. [2] in 2005, estimated the prevalence of ventricular arrhythmia at 2–8 per 100,000 children. Among patients presenting to outpatient or inpatient cardiology services, who are a selected group of children with normal cardiac anatomy and symptoms of arrhythmia, irregular heartbeat found during physician examination, or established cardiovascular pathology, in whom the risk of ventricular arrhythmia is increased, the incidence of ventricular arrhythmia is 1.1 per 100,000 children per year [3].

Address for correspondence:

Maria Miszczak-Knecht, MD, PhD, Department of Cardiology, Children's Memorial Health Institute, al. Dzieci Polskich 20, 04–730 Warszawa, Poland, e-mail: knechtmaria@gmail.com

Received: 14.08.2013

Accepted: 20.03.2014

Available as AOP: 11.06.2014

Copyright © Polskie Towarzystwo Kardiologiczne

Invasive treatment is indicated for in symptomatic arrhythmia [4]. In routine practice, however, some patients are referred for ablation due to participation in competitive sports, or plans to engage in high-risk professions that would require elimination of potentially malignant arrhythmia.

The aim of this study was to evaluate early effectiveness of radiofrequency (RF) current ablation using the CARTO electroanatomical system to treat iVA in children and adolescents, and to identify factors affecting treatment success.

METHODS

Among 600 children treated with ablation in our Clinical Electrophysiology Laboratory, iVA was the indication for treatment in 59 patients. The present study included 30 children and adolescents who underwent RF current ablation of iVA using the CARTO electroanatomical system in 2010–2012.

Patient selection for ablation

Indications for ablation in children included iVA that was symptomatic and/or comprised more than 30% of the cardiac rhythm during a 24-h ECG Holter recording, and/or ventricular tachycardia (VT). VT was defined as 3 or more consecutive ventricular beats at a rate of > 120 bpm [5]. The diagnosis of iVA was made by excluding other causes of arrhythmia including congenital heart disease, cardiomyopathy, myocarditis, and a genetic disorder as evaluated using non-genetic testing. For this purpose, all patients underwent non-invasive cardiac evaluation that included history (including family history of sudden deaths), physical examination, standard 12-lead ECG, Holter recording, exercise test, echocardiography, and cardiac magnetic resonance imaging (MRI) in 1 patient. Electrophysiologic testing and ablation were performed after obtaining a written consent from parents or patients older than 16 years according to the protocol established in our Clinical Electrophysiology Laboratory.

Methodology

Antiarrhythmic drugs were withheld for at least 5 plasma half-times before the procedure. To avoid arrhythmia suppression during anaesthesia, ablation was preferentially performed under sedation with midazolam and fentanyl. In younger children and patients with a high level of anxiety, the procedure was performed under general anaesthesia. Depending on availability, a Navi-Star or ThermoCool Nav (Biosense Webster, Diamond Bar, Ca, USA) ablation catheter was introduced by right femoral vein puncture, with an additional sensing and pacing lead introduced into the coronary sinus in some cases. In case of arrhythmia originating from the left ventricle (LV), the ablation catheter was introduced using a retrograde approach by right femoral artery puncture. Heparin was administered at 50 U/kg after artery cannulation. Following catheter introduction, an activation map of the respective cardiac chamber was recorded using bipolar electrograms during ventricular beats

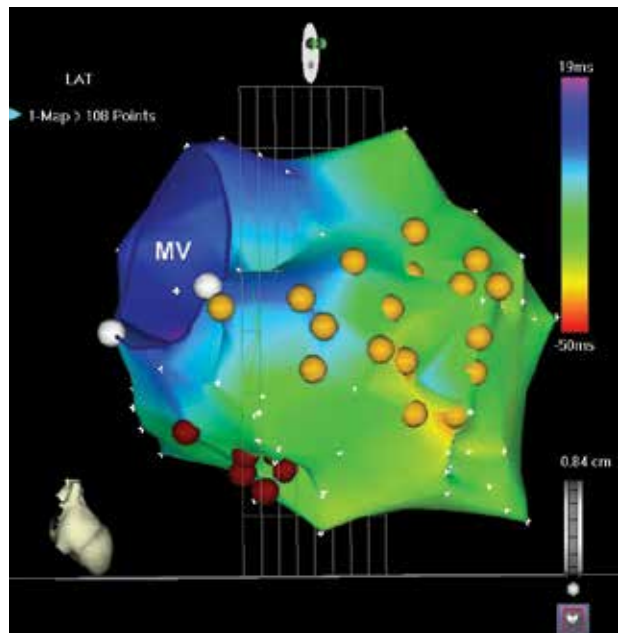


Figure 1. Left ventricular activation map created using the CARTO system, right anterior oblique view. Red dots indicate radiofrequency current application sites within the inferior wall at the septum; MV — mitral valve

or VT (Fig. 1). If spontaneous arrhythmia was not present during the examination, appropriate pacing sequence was used (8 beats at 130 bpm or 150 bpm with 1 or 2 additional impulses and/or burst stimulation). If pacing did not induce arrhythmia, isoproterenol bolus and infusion was administered and/or pacing sequence was repeated. Concordance of the induced arrhythmia with ventricular arrhythmia observed clinically was verified using 12-lead ECG. In 2 patients in whom arrhythmia was not induced, ablation site was chosen after pacing mapping confirmed 12/12 ECG lead concordance with the ventricular arrhythmia observed clinically (Fig. 2). To induce fascicular tachycardia, isoproterenol infusion and pacing was necessary in all children, including atrial pacing in 3 patients and ventricular pacing in 1 patient. The ablation site was chosen using the established criteria [6–12] when local activation preceded the QRS complex by 20–50 ms, and at the same time QS morphology was seen in the unipolar recording from the catheter tip (Fig. 3). We used a temperature of 50°C and a power of 50 W, and for cooled catheters 45°C and 35 W, respectively. In 2 patients with LV outflow tract arrhythmia, coronary angiography was additionally performed to evaluate the location of the planned ablation site in relation to a coronary artery.

Evaluation of procedural success

The procedure was considered successful when no arrhythmia was induced by pacing (in some patients also during isoproterenol infusion) during 15 min after the last RF current application. Procedural success was confirmed by 12-lead Holter

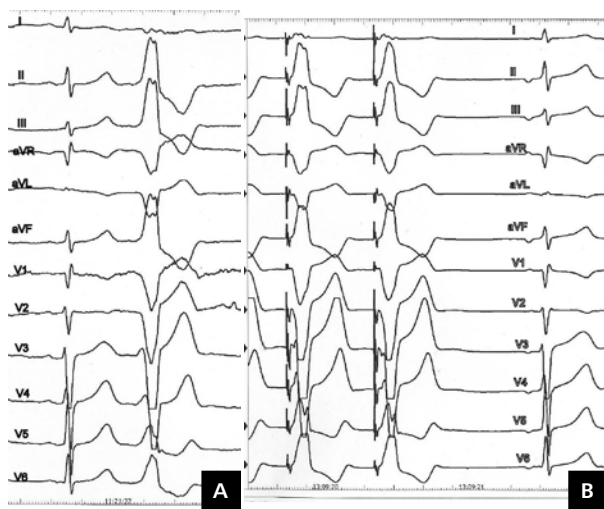


Figure 2. A. Clinically noted ventricular ectopy in a 12-lead electrocardiogram (ECG) tracing; B. A 12-lead ECG tracing during pacing mapping of right ventricular outflow tract arrhythmia. Comparison of both tracings shows QRS morphology concordance (12/12 leads) between clinical arrhythmia and paced QRS complexes

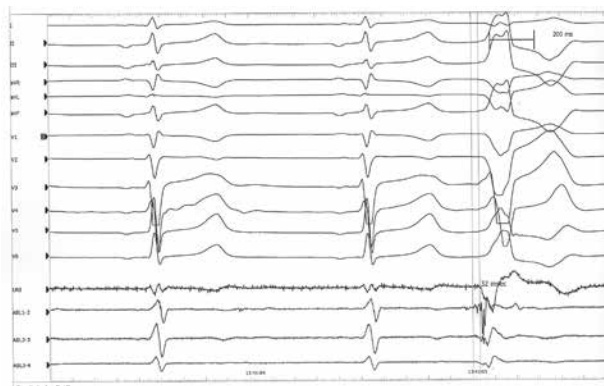

Figure 3. A 15-year-old patient. A 12-lead standard electrocardiogram (ECG) tracing and ECG recording from the ablation catheter. ECG paper speed 100 mm/s. Activation mapping within the right ventricular outflow tract, interval 32 ms

recording at 24 h. Complete procedural success was defined as the absence of arrhythmia at the end of ablation procedure and in the Holter recording at 24 h. Partial procedural success was defined as the presence of single ventricular beats (with 12/12 lead morphological concordance with the ablated VT) but no VT at the end of ablation procedure, and ventricular arrhythmia but no VT comprising no more than 5% of the Holter recording at 24 h.

Statistical analysis

In the study group, we evaluated age at the time of the diagnosis, age at the time of ablation, diagnostic modalities

used to establish the diagnosis, symptoms, and the number of medications used. The results were expressed as mean values and standard deviations.

The change in the number of ventricular beats in the post-ablation Holter recording compared to the pre-ablation recording was evaluated using the Wilcoxon test for paired samples. The rates of VT in pre- and post-ablation Holter recordings were compared using the proportion test.

Evaluation of the success of RF current ablation using the CARTO system in the treatment of iVA and its early recurrences included the effect of the type of anaesthesia (general vs. local), arrhythmia induction (spontaneous VT or ventricular beats vs. induced arrhythmia or pacing mapping), age at the time of ablation, and location of the arrhythmia on the procedural success. Statistical analysis was performed using a cumulative logistic regression model for ordinal responses. Multivariate analysis was not performed due to a small patient sample.

RESULTS

Patient characteristics

The study group included 14 girls and 16 boys. The mean age at the time of ablation was 14.7 ± 3.1 years (range 2.0–17.9 years). Typical or less typical symptoms were present in 14 (46%) children. Among asymptomatic patients, additional indications for RF current ablation included participation in competitive sports in 3 patients and a planned policeman career in 1 patient. In 13 of 16 (81%) patients with right ventricular (RV) arrhythmia, the diagnosis was made incidentally during physician examination for other reasons. Among patients with LV arrhythmia, symptoms were present in all 4 patients with fascicular tachycardia and in 4 of the remaining 10 (40%) children. The predominant symptom was palpitation (20%), often with coexisting presyncope (16%). In 1 child with LV arrhythmia who survived a cardiac arrest due to VT that degenerated to ventricular fibrillation, ECG tracing was available. Heart failure developed in 2 children with LV arrhythmia (Table 1). Cardiovascular pathology was excluded by non-invasive testing in 29 children. Echocardiography showed dilated cardiomyopathy in 1 patient. In this case, extended diagnostic work-up included MRI and metabolic testing which yielded normal results.

Drug therapy with 1 to 5 (mean 1.8 ± 1.19) antiarrhythmic drugs was used in all children but was unsuccessful in all of them. The mean duration of drug treatment was 3.4 years.

Comparison of ventricular arrhythmia in pre- and post-ablation Holter recordings in the RV and LV arrhythmia groups is shown in Figures 4 and 5, respectively. After the ablation procedure, ventricular arrhythmia was significantly suppressed in both groups ($p < 0.0001$). VT was present before ablation in 11 of 16 children with RV arrhythmia, compared to 3 patients after the ablation procedure. In the LV arrhythmia group, VT was present in 8 of 10 children before ablation compared to 3 children after the ablation procedure. No significant differ-

Table 1. Patient characteristics

	Right ventricular arrhythmia	Left ventricular arrhythmia	
		Focal arrhythmia	Fascicular tachycardia
Number of patients	16	10	4
Mean age at the time of diagnosis [years] (range)	12 (4.3–16)	9.5 (2–15.5)	13.2 (10.3–16.5)
Mean age at the time of ablation [years] (range)	15.2 (11–17.9)	13.7 (2–17.5)	14.9 (12.3–17.8)
Female/male gender	9/7	4/6	1/3
Incidental arrhythmia finding	13 (81%)	6 (60%)	0
Asymptomatic arrhythmia	10 (62%)	6 (60%)	0
Palpitations	2 (12,5%)	0	4 (100%)
Syncope	0	1 (10%)	0
Chest discomfort	1 (6%)	0	0
Other symptoms (presyncope, scotoma)	3 (18%)	2 (20%)	0
Cardiac arrest	0	1 (10%)	0
Heart failure	0	2 (20%)	0

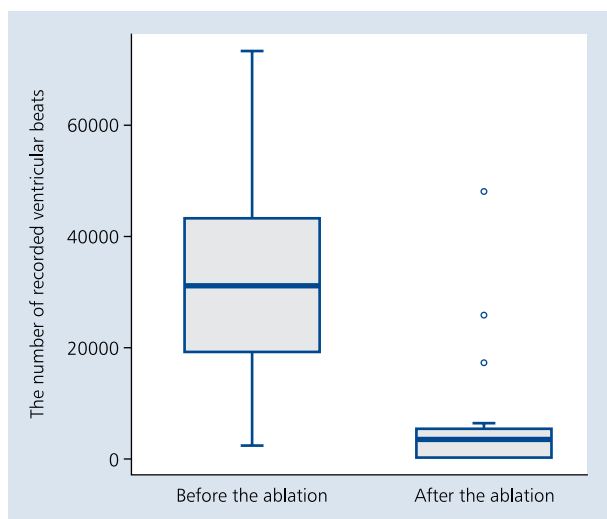


Figure 4. Box graphs showing the number of ventricular beats in Holter recording before and 24 h after ablation in the right ventricular arrhythmia group. Thick horizontal line indicates median values (31,305 before the ablation vs. 3,546 after the ablation). Bars indicate most extreme results, and box heights indicate the interquartile range ($p < 0.001$)

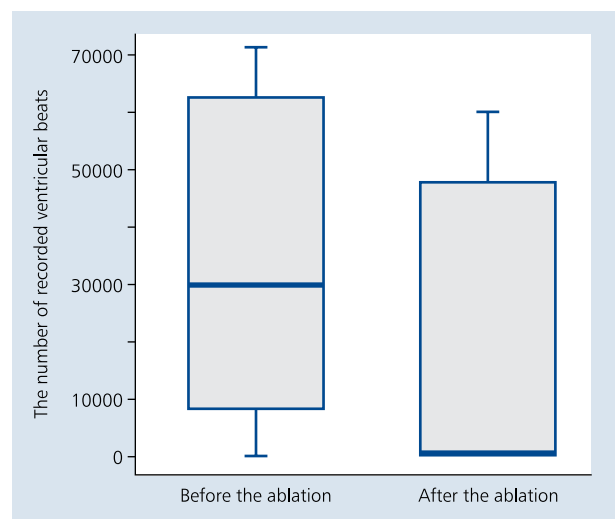


Figure 5. Box graphs showing the number of ventricular beats in Holter recording before and 24 h after ablation in the left ventricular arrhythmia group. Thick horizontal line indicates median values (30,020 before the ablation vs. 311 after the ablation). Bars indicate most extreme results, and box heights indicate the interquartile range ($p < 0.001$)

ence was seen in the RV and LV arrhythmia groups although the result was borderline.

Among children with fascicular tachycardia, no ventricular arrhythmia was seen in Holter monitoring. During arrhythmia, QRS complexes showed right bundle branch block morphology with pathological left axis deviation suggesting an origin from the area of the posterior fascicle.

Right ventricular arrhythmia

Right ventricular arrhythmia was noted in 16 (53%) children, including RV outflow tract arrhythmia in 9 (56%) children.

The remaining locations included the anterior wall, below the tricuspid annulus, and the His bundle area. In 2 children with RV arrhythmia, RF current ablation using the CARTO system was followed a prior unsuccessful attempt of conventional RF current ablation. In the RV arrhythmia group, the procedure was performed under local anaesthesia in 11 children and under general anaesthesia in 5 children. Spontaneous arrhythmia occurred during the procedure in 11 children. The mean fluoroscopy duration was 18.73 ± 7.18 min, and the mean duration of RF current application was 322.5 ± 150.8 s. At the end of ablation, complete procedural success was noted

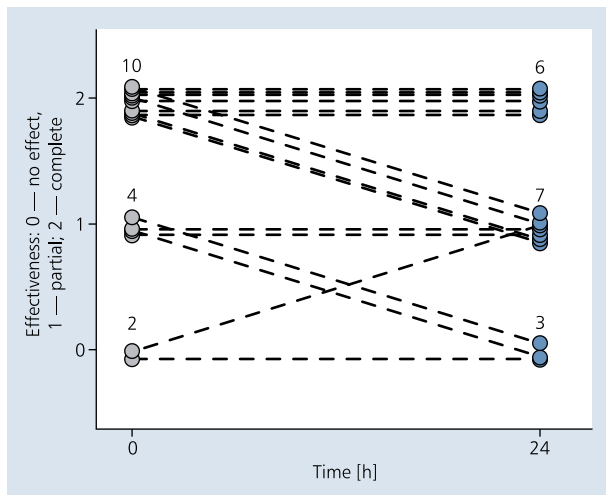


Figure 6. Ablation effectiveness immediately after the procedure and at 24 h in the right ventricular arrhythmia group. Values on the graph indicate patient numbers

in 10 (62%) patients, and partial procedural success in 4 (25%) patients. Ablation was unsuccessful in 2 patients, and we did not proceed with ablation in 1 patient due to location of the arrhythmic focus close to the His bundle, with the patient awaiting cryoablation. In Holter recording at 24 h, complete procedural success was noted in 6 (37%) patients, and partial procedural success in 7 (44%) patients. Lack of procedural success was shown in 3 patients (Fig. 6). One patient underwent another RF current ablation procedure, with the arrhythmic focus identified in the pulmonary artery.

Left ventricular arrhythmia

Left ventricular arrhythmia occurred in 14 patients. Two patients underwent previous conventional RF current ablation procedures. In 10 patients, the arrhythmic focus was identified in the following location: LV outflow tract, below the mitral annulus, in the lower interventricular septum, in the upper interventricular septum, at the posterior fascicle, at the apex, and within the anterolateral wall. In this patient group, the procedure was performed under local anaesthesia in 7 children and under general anaesthesia in 3 children. Spontaneous arrhythmia was present in 6 children. The mean fluoroscopy duration was 15.7 ± 3.9 min, and the mean duration of RF current application was 437.4 ± 316.9 s. At the end of ablation, complete procedural success was noted in 6 (60%) patients, and partial procedural success in 2 (20%) patients. Ablation was unsuccessful in 2 patients. In Holter recording at 24 h, an arrhythmia recurrence was noted in 1 patient with partial procedural success (Fig. 7). One patient underwent successful repeated ablation procedure, 1 patient was transferred to adult cardiology service, and 1 patient is awaiting epicardial ablation.

In 3 of 4 patients with fascicular tachycardia, the procedure was performed under local anaesthesia, while the

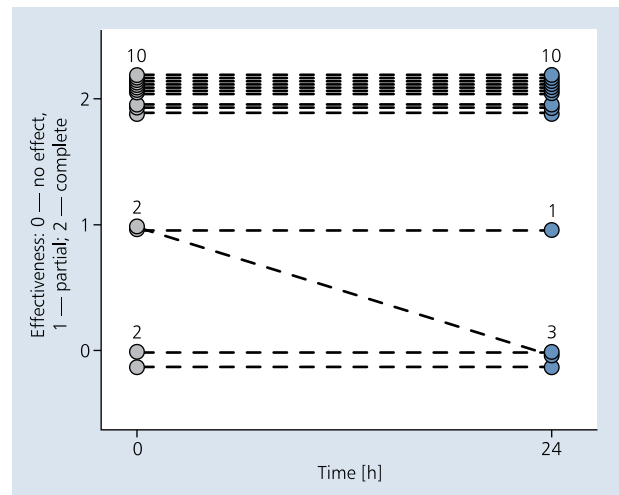


Figure 7. Ablation effectiveness immediately after the procedure and at 24 h in the left ventricular arrhythmia group. Values on the graph indicate patient numbers

remaining patient underwent ablation under general anaesthesia. Complete procedural success both immediately and after 24 h was noted in all these patients.

Overall, procedural success at 24 h was 80%, including 81% for RV arrhythmia and 78% for LV arrhythmia. Among 2 patients in whom RF current ablation was based on pacing mapping, complete and partial success was noted in 1 patient each.

In both groups, no significant effect of the type of anaesthesia, patient age at the time of ablation, and arrhythmia location on procedural success both immediately and after 24 h. Comparison of spontaneous versus induced arrhythmia showed a highly significant effect of spontaneous arrhythmia on the effectiveness of ablation in the RV arrhythmia group ($p < 0.0001$). In the LV arrhythmia group, no effect of spontaneous arrhythmia on the effectiveness of ablation was shown. Overall, spontaneous arrhythmia had a significant effect on the effectiveness of ablation ($p = 0.012$) but this was due to a highly significant effect in the RV arrhythmia group.

No procedural complications were noted in any of the children.

DISCUSSION

Idiopathic ventricular arrhythmia usually runs a mild clinical course and resolves spontaneously in 48–65% of children during long-term follow-up. This arrhythmia may develop already in the neonatal period and persist for many years, with remissions and recurrences [2, 13–18]. It presents as single monomorphic ventricular beats that sometimes comprise up to 50% of the cardiac rhythm during 24-h recordings, or as complex forms including VT. Deaths due to this arrhythmia were reported in some children, particularly with impaired ventricular function [14, 19]. Studies in adult patients showed

that long-term repetitive single ventricular ectopy may impair LV systolic and diastolic function [20]. The effect of repetitive single ventricular ectopy on cardiac function in children is unknown but it may be predicted that chronic ventricular arrhythmia may impair LV function also in this population. In our study group, the diagnosis of ventricular arrhythmia was often made incidentally during physician evaluation for other reasons. In a multicentre study by Harris et al. [17] on the clinical course of RV outflow tract arrhythmia in children and adolescents, the diagnosis was made incidentally in 82% of patients. At the same time, as many as 46% of patients confirmed the presence of symptoms when asked about them during the first visit at a cardiology clinic. In our study group, the diagnosis was made incidentally in 19 of 30 (63%) patients (including 13 of 16 [81%] patients in the RV arrhythmia group). During history taking, symptoms were reported by 14 children. Atypical presentations of arrhythmia, e.g. cough, were not taken into account both in our study and in the study by Harris et al. [17]. The presence of these symptoms changes patient selection for ablation treatment, as arrhythmia considered asymptomatic becomes a symptomatic one [21]. Thus, it is important to direct history on typical, less typical, and atypical symptoms of ventricular arrhythmia. The study by Harris et al. [17] showed no correlation between symptoms and the severity of arrhythmia. In our study, we did not correlate symptoms with the severity of arrhythmia but typical symptoms of arrhythmia (palpitations, presyncope, syncope, cardiac arrest) were absent in most patients with idiopathic RV arrhythmia. A higher frequency of haemodynamic symptoms in children and adolescents with LV arrhythmia was confirmed also in other studies [19].

The diagnosis of even mild iVA is a cause of concern for many patients, their families, and physicians, resulting in limitation of life activities of young people. It sometimes leads to a competitive sport participation ban or giving up a planned career. As a result, parents and children often insist on a permanent cure of the arrhythmia. Although mild iVA is a class III indication for ablation in children [4, 22], in practice cardiac electrophysiologists sometimes ablate this arrhythmia in individual cases. Experimental studies show that post-RF current ablation scar expands with the growing heart [23], and its long-term effect on the development of arrhythmia is not known. For these reasons, knowledge of treatment outcomes and factors affecting effectiveness of ablation is of crucial importance when selecting patients for invasive treatment and discussing it with their parents.

The role of RF current ablation in the treatment of atrioventricular nodal reentrant tachycardia and atrioventricular reentrant tachycardia in children and adolescents has been well documented [22]. The literature on iVA ablation in children and adolescents is small and most often includes single case reports and small series, with only 3 studies reporting on more than 30 patients [24–29]. In the previous studies,

ablation was performed using various techniques, and no studies compared the effectiveness of various ablation techniques. The CARTO electroanatomical system allows creation of an activation map even with a small number of ventricular extrasystoles and for this reason it was used in our study group. In 4 our patients, ablation using the CARTO system was another successful attempt following previous unsuccessful attempts of conventional ablation. In our study group, the effectiveness of RF current ablation using the CARTO system was high, which is consistent with the literature data [24–29]. Arrhythmia recurrences following an initially successful treatment were reported [25, 27, 29]. Two facts are of note in our study group: persistence of single ventricular ectopy which was morphologically consistent with the ablated arrhythmia (particularly RV arrhythmia), and the possibility of arrhythmia cessation or recurrence during a short time after an unsuccessful procedure. No data are available in the literature regarding persistence of single ventricular beats after RF current ablation of iVA in children and adolescents. In our study, it comprised only < 5% of the cardiac rhythm recorded during 24 h, had no clinical importance and was seen only in patients with RV arrhythmia. A frequent reason to withhold RF current application is an unfavourable location of the arrhythmic focus [25], most frequently close to the His bundle. In our study, this was noted in only 1 child who is currently awaiting cryoablation. Location close to the sinus of Valsalva is also considered a higher risk location [25]. The risk of complications may be reduced by performing aortography to visualise coronary arteries before RF current application.

The only variable found to affect the final result of the procedure was the presence of spontaneous arrhythmia during the electrophysiological study. The most common mechanism of iVA is triggered automatism [26]. It is affected by autonomic tone, and thus general anaesthesia may be expected to reduce spontaneous arrhythmia but this was not substantiated by our findings. The type of anaesthesia also had no effect on the treatment effectiveness. Similar conclusions were reported by Morwood et al. [25].

The 2013 EHRA/AEPC statement on drug and non-drug therapy of arrhythmia in children highlighted a high effectiveness of the RF current ablation in the treatment of ventricular arrhythmia (particularly fascicular tachycardia) and an effect of modern mapping systems on the effectiveness of these procedures. However, the authors also noted a need for careful, individual selection of children and adolescents for ablation, and performing these procedures only in symptomatic patients [22].

Limitations of the study

A small patient sample was the most important limitation of our study. As patients with ventricular arrhythmia comprise only about 1.8% of paediatric patients undergoing ablation [22], it is difficult to obtain larger single-centre cohorts.

Advanced statistical methods were necessary to evaluate the effect of multiple variables on the effectiveness of ablation in a relatively small patient group. For this purpose, a cumulative logistic regression model was chosen.

Ablation procedures were performed using both cooled and non-cooled catheters. The use of cooled catheters might have resulted in an increased effectiveness of the ablation procedure. A small patient sample precluded an evaluation of the effect of the catheter type used on the effectiveness of ablation. We also did not compare the effectiveness of the ablation procedures using the CARTO electroanatomical system and conventional ablation.

CONCLUSIONS

1. Ablation of iVA in children and adolescents is a successful and safe procedure for most arrhythmia locations.
2. The only variable found to affect procedural success both immediately and after 24 h was the presence of spontaneous ventricular arrhythmia during the electrophysiological study and ablation procedure in patients with focal arrhythmia.

The study was supported by the grant No. NCN N407 414836.

Conflict of interest: none declared

References

1. Badhwar N, Scheinman MM. Idiopathic ventricular tachycardia: Diagnosis and Management. *Curr Probl Cardiol*, 2007; 32: 7–43.
2. Iwamoto M, Niimura I, Shibata T et al. Long-term course and clinical characteristics of ventricular tachycardia detected in children by school-based heart disease screening. *Circ J*, 2005; 3: 273–276.
3. Roggen A, Pavlovic M, Pfammater JP. Frequency of spontaneous ventricular tachycardia in pediatric population. *Am J Cardiol*, 2008; 101: 852–854.
4. Friedman R, Walsh E, Silka M et al. NASPE Expert consensus conference: radiofrequency catheter ablation in children with and without congenital heart disease. Raport of Writing Committee. *PACE*, 2002; 25: 1000–1017.
5. Baranowski R, Wojciechowski D, Maciejewska M et al. Zalecenia dotyczące rozpoznania elektrokardiograficznych. *Kardiologia Pol*, 2010; 68 (suppl. IV).
6. Miller J, Pezeshkian N, Yadav A et al. Catheter mapping and ablation of right ventricular outflow tract ventricular tachycardia. *J Cardiovasc Electrophysiol*, 2006; 17: 800–802.
7. Klein L, Shih H, Hackett K et al. Radiofrequency catheter ablation of ventricular tachycardia in patients without structural heart disease. *Circulation*, 1992; 85: 1666–1674.
8. Azegami k, Wilber D, Arruda H et al. Spatial resolution of pacemapping and activation mapping in patients with idiopathic right ventricular outflow tract tachycardia. *J Cardiovasc Electrophysiol*, 2005; 16: 823–829.
9. Ouyang F, Cappato R, Ernst S et al. Electroanatomic substrate of idiopathic left ventricular tachycardia: unidirectional block and macroreentry within the Purkinje network. *Circulation*, 2002; 105: 662.
10. Ouyang F, Fotuhi P, Yen Ho S et al. Repetitive monomorphic ventricular tachycardia originating from the aortic sinus cusp. *J Am Coll Cardiol*, 2002; 39: 500–508.
11. Aliot E, Stevenson W, Almendral-Garode J et al. EHRA/HRS expert consensus on catheter ablation of ventricular arrhythmias. *Heart Rhythm*, 2009; 6: 886–931.
12. Arya A, Haghjoo M, Emkanjoo Z et al. Comparison presystolic Purkinje and late diastolic potentials for selection of ablation site in idiopathic verapamil sensitive left ventricular tachycardia. *J Interv Card Electroph*, 2004; 11: 135–141.
13. Beaufort-Krol G, Dijkstra S, Bink-Boelkens M et al. Natural history of ventricular premature construction in children with structural normal hearts: does origin matter? *Europace*, 2008; 10: 998–1003.
14. Song M, Baek J, Kwon B et al. Clinical spectrum and prognostic factors of pediatric ventricular tachycardia *Circ J*, 2010; 74: 1951–1958.
15. Pfammater JP, Paul T. Idiopathic ventricular tachycardia in infancy and childhood: a multicenter study on clinical profile and outcome. *J Am Coll Cardiol*, 1999; 33: 2076–2082.
16. Tsuji A, Nagashina M, Hasegare S et al. Long-term follow up of idiopathic ventricular arrhythmias in otherwise normal children *Jpn Circ J*, 1995; 59: 654–662.
17. Harris K, Potts J, Fournier A et al. Right ventricular outflow tachycardia in children. *J Pediatr*, 2006; 149: 822–826.
18. Wang S, Zhu W, Hamilton R, Kirsh J et al. Diagnosis-specific characteristics of ventricular tachycardia in children with structurally normal hearts. *Heart Rhythm*, 2010; 7: 1725–1731.
19. Deal B, Miller S, Scagliotti D et al. Ventricular tachycardia in a young population without overt heart disease. *Circulation*, 1986; 73: 1111–1118.
20. Lelakowski J, Dreher A, Majewski J, Bednarek J. Effects of catheter ablation of idiopathic ventricular ectopic beats on left ventricular function and exercise capacity. *Kardiologia Pol*, 2009; 67: 847–855.
21. Stec SM, Grabczak EM, Bielicki P et al. Diagnosis and management of premature ventricular complexes-associated chronic cough. *Chest*, 2009; 135: 1535–1541.
22. Brugada J, Blom N, Sarquella-Brugada G et al. Pharmacological and non-pharmacological therapy for arrhythmias in the pediatric population: EHRA and AEPIC-Arrhythmia Working Group joint consensus statement. *Europace*, 2013; 15: 1337–1382.
23. Saul Ph, Papagiannis J, Van Praagh R et al. Late enlargement of radiofrequency lesions in infant lambs. Implications for ablation procedures in small children. *Circulation*, 1994; 90: 492–499.
24. Hsieh IC, Yeh SJ, Wen MS et al. Radiofrequency ablation for supraventricular and ventricular tachycardia in young patients. *Int J Cardiol*, 1996; 54: 33–40.
25. Morwood JG, Friedman JK, Berul CI et al. Radiofrequency catheter ablation of ventricular tachycardia in children and young adults with congenital heart disease. *Heart Rhythm*, 2004; 1: 301–308.
26. Fukuhara J, Sumitomo N, Nakamura T et al. Electrophysiological characteristics of idiopathic ventricular tachycardia in children. *Circ J*, 2011; 75: 672–676.
27. Collins K, Schaffer M, Liberman L, Fascicular and nonfascicular tachycardias in the young: an international multicenter study. *J Cardiovasc Electrophysiol*, 2013; 24: 640–648.
28. Schneider H, Kriebel T, Jung K et al. Catheter ablation of idiopathic left and right ventricular tachycardia in the pediatric population using noncontact mapping. *Heart Rhythm*, 2010; 7: 731–734.
29. Laonakunakorn P, Paul T, Knick B et al. Ventricular tachycardia in nonpostoperative pediatric patients: role of radiofrequency catheter ablation. *Pedi Cardiol*, 2003; 24: 154–160.

Idiopatyczna arytmia komorowa u dzieci i młodzieży: wczesne wyniki leczenia ablacją o wysokiej częstotliwości

Maria Miszczak-Knecht¹, Łukasz Szumowski², Maria Posadowska³, Monika Brzezińska-Paszke¹, Katarzyna Pręgoska³, Franciszek Walczak², Anna Turska-Kmieć¹, Katarzyna Bieganowska⁴

¹Klinika Kardiologii, Instytut „Pomnik-Centrum Zdrowia Dziecka”, Warszawa

²Klinika Zaburzeń Rytmu Serca, Instytut Kardiologii, Warszawa-Anin

³Instytut „Pomnik-Centrum Zdrowia Dziecka”, Warszawa

⁴Pracownia Elektrofizjologii Klinicznej, Instytut „Pomnik-Centrum Zdrowia Dziecka”, Warszawa

Streszczenie

Wstęp: Idiopatyczna arytmia komorowa (iVA) u dzieci ma najczęściej przebieg bezobjawowy. Wskazaniem do leczenia inwazyjnego jest występowanie arytmii objawowej. Jednak w codziennej praktyce część pacjentów jest kwalifikowana do zabiegu ablacji ze względu na wyczynowe uprawianie sportu lub planowanie zawodów wysokiego ryzyka z koniecznością wyeliminowania potencjalnie złośliwej arytmii.

Cel: Celem pracy była ocena wczesnej skuteczności leczenia iVA za pomocą ablacji prądem o wysokiej częstotliwości (RF) przy użyciu systemu CARTO u dzieci i młodzieży oraz identyfikacja czynników wpływających na sukces terapii tą metodą.

Metody: Spośród ponad 600 dzieci poddanych ablacji przeanalizowano dane 30 dzieci w wieku 2,0–17,9 roku (średnio $14,7 \pm 3,1$) poddanych ablacji iVA. Oceniano skuteczność ablacji RF z użyciem systemu elektroanatomicznego CARTO bezpośrednio po oraz 24 godziny po zabiegu. Zbadano wpływ na skuteczność leczenia: wieku w chwili ablacji, typu znieczulenia, lokalizacji arytmii i występowania komorowych zaburzeń rytmu serca w czasie zabiegu.

Wyniki: W trakcie badania elektrofizjologicznego arytmie z prawej komory stwierdzono u 16 (53%) dzieci, w tym z drogi odpływu u 9 (56%) dzieci. Arytmie z lewej komory miało 14 dzieci, w tym u 4 (28%) był to częstoskurcz wiązkowy, a u 2 (14%) z drogi odpływu lewej komory. W grupie arytmii z prawej komory zabieg był skuteczny u 13 (81%) pacjentów, a w grupie arytmii z lewej komory u 11 (78%) osób. Jedynym czynnikiem wpływającym na skuteczność zabiegu ablacji było występowanie spontanicznej arytmii komorowej w czasie badania elektrofizjologicznego i ablacji ($p = 0,012$). Nie wystąpiły powikłania.

Wnioski: Ablacja iVA u dzieci i młodzieży jest bezpieczna. Jej skuteczność jest dobra. Jedynym czynnikiem wpływającym na skuteczność zabiegu jest występowanie spontanicznej arytmii komorowej w czasie badania elektrofizjologicznego i ablacji u pacjentów z arytmia ogniskową.

Słowa kluczowe: idiopatyczna arytmia komorowa, dzieci, ablacja metodą CARTO

Kardiologia 2014; 72, 11: 1148–1155

Adres do korespondencji:

dr n. med. Maria Miszczak-Knecht, Klinika Kardiologii, Instytut „Pomnik-Centrum Zdrowia Dziecka”, al. Dzieci Polskich 20, 04-730 Warszawa, e-mail: knechtmaria@gmail.com

Praca wpłynęła: 14.08.2013 r.

Zaakceptowana do druku: 20.03.2014 r.

Data publikacji AoP: 11.06.2014 r.