

Hybrid cardiovascular procedures in the treatment of selected congenital heart disease in children: a single-centre experience

Ireneusz Haponiuk¹, Maciej Chojnicki¹, Radosław Jaworski¹, Mariusz Steffens¹,
Aneta Szofer-Sendrowska¹, Jacek Juściński¹, Ewelina Kwaśniak¹, Wiktor Szymanowicz¹,
Katarzyna Gierat-Haponiuk², Katarzyna Leszczyńska³

¹Department of Paediatric Cardiac Surgery, Pomeranian Centre of Traumatology, Gdansk, Poland

²Department of Rehabilitation Medicine, Medical University of Gdansk, University Clinical Centre, Gdansk, Poland

³Department of Obstetrics, Medical University of Gdansk, University Clinical Centre, Gdansk, Poland

Abstract

Background: Paediatric hybrid cardiovascular procedures are becoming increasingly popular due to the wide spectrum of cardiovascular abnormalities and a large population of patients who could benefit from hybrid therapy. Contemporary hybrid procedures are introduced in the settings where routine cardiac surgery or cardiac interventions would not allow satisfactory results. Combining cardiac surgery and interventional cardiology techniques appears more beneficial and less invasive for the patient.

Aim: To present results of hybrid procedures performed in the treatment of selected congenital heart disease in our centre in 2008–2013.

Methods: We retrospectively analysed consecutive 80 patients referred for hybrid procedures.

Results: Overall, 73 patients survived, with 4 early and 3 late deaths.

Conclusions: Hybrid procedures in children with congenital heart disease combine the experience of cardiac surgery and interventional cardiology. Hybrid treatment is an alternative option for selected borderline patients. Initial results of hybrid treatment encourage further development of these methods and strategies to provide optimal benefits for the patients.

Key words: congenital heart disease, paediatric cardiac surgery, hybrid procedures

Kardiol Pol 2014; 72, 4: 324–330

INTRODUCTION

Complex anatomy and pathophysiology of congenital heart disease in children resulted in the development of new treatment strategies based on cooperation of invasive cardiologists and cardiac surgeons, supported by sophisticated intra-operative imaging techniques — hybrid procedures. With this approach, positive effects of therapy can be achieved while side effects typically observed when individual component treatments are used separately can be limited. These procedures are used in the treatment of children with congenital heart disease (CHD) with atypical anatomy and associated additional limitations, or with borderline difficult anatomical

variants of typical disease [1]. The aim of this study was to present experience of the Department of Paediatric Cardiac Surgery in Gdansk, Poland, related to introduction and practical use of hybrid procedures in the treatment of selected CHD in children during more than 5 years since this program was initiated in 2008.

METHODS

Study group

We retrospectively analysed 80 consecutive patients referred for hybrid procedures performed in the Department of Paediatric Cardiac Surgery in Gdansk from January 1, 2008 to

Address for correspondence:

Ireneusz Haponiuk, MD, PhD, Department of Paediatric Cardiac Surgery, Pomeranian Centre of Traumatology, ul. Nowe Ogrody 1–6, 80–806 Gdańsk, Poland, tel: +48 58 76 40 659, e-mail: ireneusz_haponiuk@poczta.onet.pl

Received: 15.09.2013

Accepted: 19.11.2013

Available as AOP: 27.11.2013

Copyright © Polskie Towarzystwo Kardiologiczne

Table 1. Summary of performed hybrid procedures and demographic characteristics of the patients

Type of procedure	Number (%)	Body weight*	Age*	Comments
Hybrid intraoperative dilatation of peripheral pulmonary artery stenoses in patients undergoing staged repair of ToF or shunt lesions with increased pulmonary flow	53 (66.3%)	6.5 ± 2.05; 3.5–12.5 kg	9.5 ± 7.7 months; 13 days – 35 months	a) By transventricular approach: 47 patients; b) By pulmonary artery puncture: 6 patients
Hybrid transventricular closure of mVSD	14 (17.5%)	8.4 ± 4; 4.5–20 kg	15.3 ± 16.4 months; 2.7–60 months	a) Single stage procedures: — primary hybrid procedure with transventricular closure of mVSD: 6 patients; — simultaneous intraoperative transventricular closure of mVSD using an implanted occluder during surgical perimembraneous VSD closure using ECC: 1 patient; b) Multistage procedures: — hybrid procedure as the second final stage of treatment in patients with multiple mVSD after pulmonary artery banding in the neonatal period or during early infancy: 4 patients; — hybrid procedure as the final stage of treatment in patients with mVSD, after surgical repair of critically severe CoA and pulmonary artery banding in the neonatal period: 3 patients
Hybrid transatrial closure of ASD II	2 (2.5%)	4 kg and 23 kg	9 months and 9 years	Patients with contraindications to interventional and surgical treatment
Selective RPA and LPA banding + PDA stenting	10 (12.5%)	3.2 ± 1.48; 1.3–7.2 kg	1.4 ± 3.2 months; 1 day – 10.6 months	Two patients with hypoplastic left ventricle due to extensive left-sided CDH
HLHS comprehensive hybrid stage II	1 (1.25%)	5 kg	5.3 months	Norwood type procedure with simultaneous Glenn procedure and PDA stent resection

*mean ± SD; range; ToF — tetralogy of Fallot; mVSD — muscular ventricular septal defect; VSD — ventricular septal defect; ECC — extracorporeal circulation; CoA — coarctation of the aorta; ASD II — ostium secundum atrial septal defect; RPA — right pulmonary artery; LPA — left pulmonary artery; PDA — patent ductus arteriosus; HLHS — hypoplastic left heart syndrome; CDH — congenital diaphragmatic hernia

September 10, 2013. The study group included 38 (47.5%) boys and 42 (52.5%) girls. Ten patients were neonates younger than 28 (12.5%) days. In 1 female patient, 2 hybrid procedures were performed. Procedures and demographic characteristics of the patients are shown in Table 1.

In addition to CHD, concomitant problems in patients referred for hybrid procedures included perinatal morbidity, progressive circulatory decompensation, and congenital defects involving other organs and systems. Twenty (25%) patients were born prematurely, 32 (40%) had low birth weight, 20 (25%) had perinatal infection, 27 (33.8%) showed respiratory failure on admission, 65 (81.2%) showed cyanosis on admission, 50 (62.5%) were small for gestational age, 9 (11.3%) had coarctation of the aorta, 2 (2.5%) had left-sided congenital diaphragmatic hernia (CDH), and 22 (27.5%) patients had a genetic syndrome. The thymus was found to be absent in 15 (18.8%) patients. Surgical/car-

diac surgical procedures or invasive cardiology interventions were performed before the hybrid procedure in 49 (61.3%) patients. We treated 15 (18.8%) children with a single ventricle (SV) physiology, including 6 with hypoplastic left heart syndrome (HLHS). Additional problems coexisting with CHD in patients treated with hybrid procedures are summarised in Table 2.

Hybrid procedures

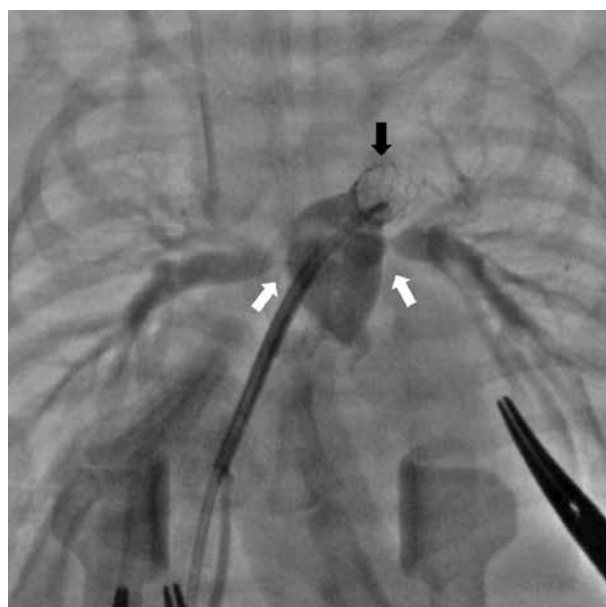Details of hybrid procedures of transventricular closure of muscular ventricular septal defects (mVSD) (Fig. 1) were reported in our previous reports [2–6], and the technique of hybrid procedures in neonates with (HLHS hybrid stage I and HLHS comprehensive hybrid stage II) was consistent with the approach suggested by Galantowicz et al. [7]. All HLHS hybrid stage I procedures were performed in the following order: initially, selective banding of the right pulmonary artery and then

Table 2. Additional problems and comorbidities in patients undergoing hybrid treatment

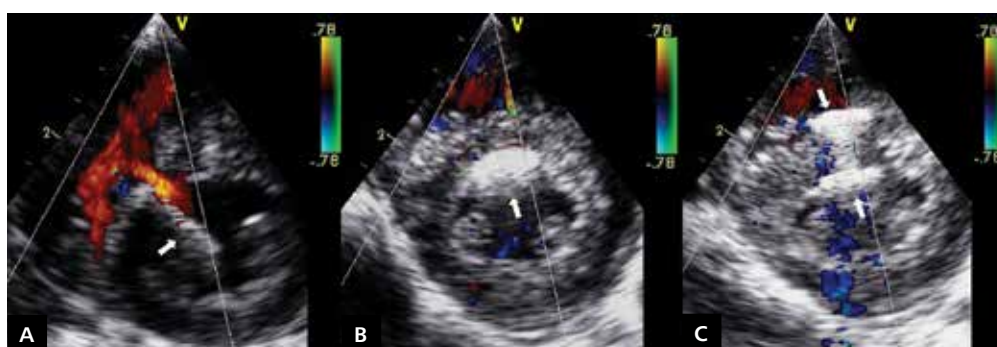
Problem/comorbidity	No. of patients (%)
Prematurity (< 36 weeks of gestation)	20 (25%)
Low birth weight (< 2.5 kg)	32 (40%)
Perinatal infection	20 (25%)
Respiratory failure	27 (33.8%)
Cyanosis	65 (81.3%)
Small for gestational age	50 (62.5%)
Coarctation of the aorta	9 (11.3%)
Congenital diaphragmatic hernia	2 (2.5%)
Genetic syndrome	22 (27.5%)
Lack of the thymus	15 (18.8%)
Previous cardiac surgery, other surgery, or invasive cardiac procedure	31 (38.8%)

the left pulmonary artery was performed under continued prostaglandin E1 infusion, followed by stenting of the patent ductus arteriosus and termination of prostaglandin E1 infusion. The initial access route of choice was conventional median sternotomy but with growing experience of the whole team this was replaced by a less invasive approach involving limited sternotomy within the xiphoid process and lower sternum, performed without thymectomy (in 5 children).

Individual stages of the hybrid procedure were imaged using fluoroscopy (single-plane General Electric Innova 4100 system) and transthoracic, transoesophageal and epicardial echocardiography (GE Vivid i, Philips iE 33). An important component of the evaluation of immediate procedural results was exit angiography performed in all neonates with SV physiology (Fig. 2). Routine early anticoagulation with heparin was used for up to 48 h after the procedure, and antiplatelet treatment with acetylsalicylic acid was continued for up to 6 months after the procedure.

**Figure 2.** Intraoperative exit angiography after hypoplastic left heart syndrome hybrid stage I procedure. Note right and left pulmonary artery narrowings at the sites of banding (white arrows) and a stent in the ductus arteriosus (black arrow)

For hybrid closure of ventricular septal defects (VSD), we used Amplatzer VSD Occluder (St. Jude Medical, Inc., USA) and Amplatzer Duct Occluder II (St. Jude Medical, Inc., USA) devices, and ostium secundum atrial septal defects (ASD II) were closed using Amplatzer Septal Occluder (St. Jude Medical, Inc., USA) devices. For dilation of the ductus arteriosus, we used coronary stents (Abbott Laboratories, USA) and vascular stents (Cook Medical, Inc., USA; C.R. Bard, Inc., USA). Balloon angioplasties were performed using balloon catheters (Balton Sp. z o.o., Poland). For selective pulmonary artery banding, 2.5 mm wide stripes of cut-through PTFE vascular conduit (diameter 3.5 mm) were used (GoreTex®, EU) [8].

**Figure 1.** Hybrid transventricular closure of muscular ventricular septal defect; **A.** The tip of vascular sheath in the left ventricle after crossing the ventricular septal defect (arrow); **B.** First disc of the implant released in the left ventricle (arrow); **C.** Both discs of the implant released in the right and left ventricle and occluding the ventricular septal defect (arrows)

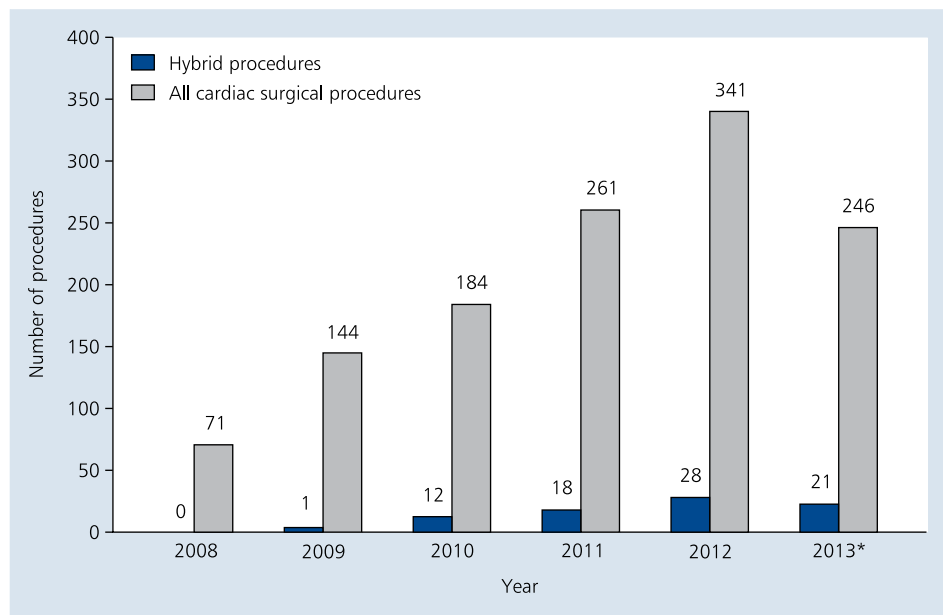


Figure 3. Number of hybrid procedures performed in the Department of Paediatric Cardiac Surgery in Gdansk in 2008–2013; *until September 10, 2013

Statistical analysis

Statistical analysis was performed using the SPSS v.13.0 for Windows statistical software (SPSS Inc., USA). Continuous variables were compared using the Mann-Whitney U test. Categorical variables were compared using the Pearson χ^2 test or the exact Fisher test with Yates's correction in case of small sample sizes in subgroups. $P < 0.05$ was considered statistically significant. Survival was evaluated using the Kaplan-Meier curves. All patients included in the survival analysis died due to the underlying cardiac disease and/or its complications or were followed-up until September 10, 2013. Survival in subgroups was compared using the log-rank test.

RESULTS

During the study period, 1,246 children were treated due to CHD in the Department of Paediatric Cardiac Surgery in Gdansk. This included 476 surgical procedures with the use of extracorporeal circulation (on-pump), 574 surgical procedures without the use of extracorporeal circulation (off-pump), and 196 invasive cardiology procedures. Hybrid procedures amounted for 6.4% of all procedures. The proportion of hybrid procedures in subsequent years was 0% in 2008, 0.7% in 2009, 6.5% in 2010, 6.9% in 2011, 8.2% in 2012 and 8.5% in 2013 (follow-up in progress) (Fig. 3).

Underlying congenital defects in the study group of 80 children were HLHS in 6 (7.5%) children, left ventricular hypoplasia in 3 (3.8%) children, mVSD in 14 (17.5%) children, type B interrupted aortic arch (IAA) in 1 (1.3%) child, ASD II in 2 (2.5%) children, native pulmonary stenosis in 36 (45%) children, and iatrogenic stenosis following pulmonary artery

banding in 18 (22.5%) children. During the study period, the following hybrid procedures were performed: hybrid intraoperative dilatation of peripheral pulmonary artery stenoses during staged repair of tetralogy of Fallot (ToF) or shunt lesions with increased pulmonary flow, performed using the transventricular approach or by pulmonary artery puncture, in 53 (65.4%) patients, hybrid transventricular mVSD closure in 14 (17.2%) patients, hybrid transatrial ASD II closure in 2 (2.4%) children, HLHS hybrid stage I procedures in 10 (12.3%) patients, and HLHS comprehensive hybrid stage II procedure in 1 (1.2%) child.

Among children with mVSD and ASD II, the hybrid procedure resulted in complete shunt occlusion in 15 children, and a small shunt through a slit-like mVSD persisted during a 2-year follow-up in 1 female patient with multiple VSD. No complications related to the presence of an implanted device were noted during short- and medium-term follow-up (mean duration of follow-up 26.1 ± 15.4 months; range 3.9–51.3 months). Hybrid balloon angioplasty procedures resulted in dilatation of pulmonary artery stenoses, both native (mainly involving pulmonary artery branches or the pulmonary valve) and iatrogenic (following palliative surgical pulmonary artery banding). During follow-up, the highest residual gradient in the main pulmonary artery or its branches as measured by echocardiography was 25 mm Hg (mean duration of follow-up 16.9 ± 9.1 months; range 4–34.7 months). After hybrid pulmonary artery balloon angioplasty techniques were introduced, we were essentially able to abandon surgical dilatation of iatrogenic pulmonary artery stenoses following pulmonary artery banding.

Tabela 3. Additional problems and comorbidities in patients with single ventricle (SV) or double ventricle (DV) physiology undergoing hybrid treatment

Problem/comorbidity	Children with SV physiology (n = 15)	Children with DV physiology (n = 65)	P
Prematurity (< 36 weeks of gestation)	3	17	0.45
Low birth weight (< 2.5 kg)	6	26	0.62
Perinatal infection	7	13	0.039
Respiratory failure	9	18	0.021
Cyanosis	15	50	0.031
Small for gestational age	11	39	0.26
Coarctation of the aorta	1	8	0.46
Congenital diaphragmatic hernia	2	0	0.033
Genetic syndrome	2	20	0.15
Lack of the thymus	4	11	0.295
Previous cardiac surgery, other surgery, or invasive cardiac procedure	10	39	0.43

Staged Norwood procedure remains the standard approach to the management of HLHS. Patients with HLHS referred for hybrid procedures were very severely ill neonates who were refused conventional treatment. Despite very high procedural risk, the hybrid procedure was the only potential treatment option in this patient group. In 1 child after HLHS hybrid stage I procedure, a stenosis of the ductus arteriosus located proximally to the implanted stent was observed that required another intervention [9].

When we analysed characteristics of and concomitant conditions in children with SV physiology, we found that the mean age of children with SV physiology was 3.2 ± 3.6 months (range 1 day to 7.9 months) compared to 12.4 ± 15.9 months in children with double ventricle (DV) physiology (range 1.9–107.5 months), a statistically significant difference ($p = 0.001$). The mean body mass in these patient groups also differed significantly, 4.6 ± 2.1 kg in the SV group (range 2–8.3 kg) compared to 7.1 ± 3.4 kg in the DV group (range 1.8–23.3 kg) ($p = 0.003$). Children with SV physiology who underwent a hybrid procedure were referred for this treatment at an earlier stage and with lower body mass, and thus potentially significantly higher operative risk, and were more often found to have respiratory failure, cyanosis, perinatal infection or concomitant CDH (Table 3).

Survival analysis

As of September 10, 2013, 73 patients remained in follow-up, and the mean duration of follow-up was 17.6 ± 12.1 months (range 0 days to 51.3 months). Among children with SV physiology, 7 patients died, yielding 1-year and 2-year survival probability of 65.5% and 54.5%, respectively (mean duration of follow-up 14.6 months) (Fig. 4), and no deaths were noted among the remaining children treated with hybrid procedures (survival 100%, mean duration of follow-up 18.8 months;

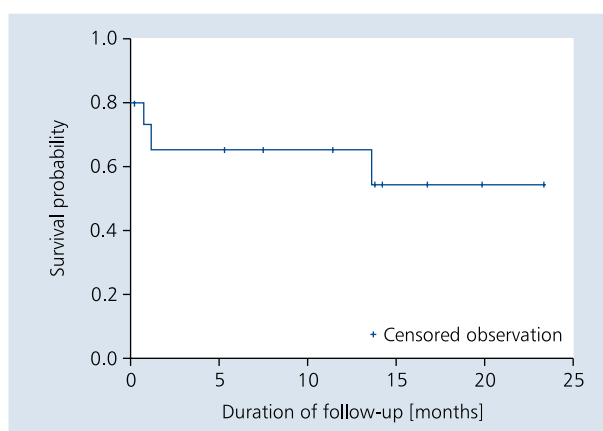


Figure 4. Survival of children with single ventricle physiology after hybrid treatment

$p < 0.001$). Thus, overall 73 of 80 patients are alive, with 4 early deaths (within 30 days after the procedure, including 1 child with left ventricular hypoplasia associated with CDH and 3 children with HLHS) and 3 late deaths (1 child with IAA, 1 child with left ventricular hypoplasia associated with CDH, and 1 child with HLHS).

DISCUSSION

Hybrid cardiovascular procedures in children are becoming increasingly popular, with a growing range of defects undergoing such treatment and an increasing population of patients who could benefit from hybrid therapy. Contemporary hybrid procedures are introduced in the settings where routine cardiac surgery or cardiac interventions would not allow satisfactory results, and combining cardiac surgery and interventional cardiology techniques is actually less invasive and traumatizing for the patient.

Due to a need to introduce hybrid procedures in the Department of Paediatric Cardiac Surgery in Gdansk, the "Gdansk Hybrid Heartlink" program was initiated in 2008 to provide a full spectrum of hybrid treatment capabilities for children with CHD [10]. The whole team of our Department of Paediatric Cardiac Surgery was created with an idea to fully explore the potential of cardiac surgeons, invasive cardiologists, cardioanaesthesiologists, neonatal and infant surgeons, and neonatologists in cooperation with obstetrics and gynaecology and paediatric cardiology tertiary care centres.

Hybrid procedures in the Department of Paediatric Cardiac Surgery in Gdansk were initially introduced in the treatment of infants with mVSD, followed by neonates and preterm infants with IAA, and finally selected neonates with HLHS and left ventricular hypoplasia associated with CDH. Hybrid intraoperative pulmonary artery balloon angioplasty was successfully used as adjunct procedure during staged repair of ToF and shunt lesions with increased pulmonary flow following earlier pulmonary artery banding. After hybrid balloon angioplasty techniques were introduced into our routine practice, we were essentially able to abandon surgical dilatation of pulmonary artery stenoses following pulmonary artery banding.

With development of the program and growing experience of the whole team, we began to perform hybrid procedures in "borderline" patients, including neonates and premature infants with multiple comorbidities and extremely low body mass, which is consistent with treatment strategies used in other centres with similar programs [11–13]. In addition, we introduced surgical techniques allowing less invasive access, including miniinvasive sternotomy, which reduced operative trauma and its potential sequelae. In children undergoing hybrid treatment, sparing thymus during the first procedure also seems beneficial, as it allows maintaining function of this gland in early infancy and facilitates surgical access to the heart and great vessel during further stages of treatment and reoperations.

All patients who died early after a hybrid procedure were neonates in the "borderline" group. Their extremely severely ill general condition and comorbidities precluded both conventional cardiac surgery and conventional interventional treatment (in our material, these were "borderline" neonates and preterm infants with HLHS and CDH). Overall mortality after hybrid procedures (8.8%), despite multiple comorbidities present in "borderline" patients, is generally consistent with the acceptable operative mortality in cardiac surgery programs in Poland and worldwide.

Hybrid procedures still constitute a minor proportion of all procedures performed in the Department of Paediatric Cardiac Surgery in Gdansk but their number is increasing with growing experience of our team. Thus, their value results from the fact that they became an additional, alternative treatment option for selected patients.

CONCLUSIONS

Hybrid procedures in children with CHD combine the experience of cardiac surgery and interventional cardiology and are an alternative treatment option for selected patients, including severely ill "borderline" patients. Initial results of hybrid treatment encourage further development of these methods and strategies to provide optimal benefits for the patients. Performance of hybrid procedures in patients with additional problems requires close multidisciplinary cooperation within the Hybrid Heart Team, involving cardiac surgeons, invasive cardiologists, and anaesthesiologists.

Conflict of interest: none declared

References

- Holzer R, Marshall A, Kreutzer J et al. Hybrid procedures: adverse events and procedural characteristics—results of a multi-institutional registry. *Cong Heart Dis*, 2010; 5: 233–242.
- Chojnicki M, Haponiuk I, Jaworski R et al. Śródoperacyjne obrazowanie hybrydowego zabiegu zamknięcia ubytku w przegrodzie międzykomorowej za pomocą Amplatzer Duct Occluder II. *Kardiologia Pol*, 2011; 69: 1280–1281.
- Haponiuk I, Chojnicki M., Jaworski R. Komentarz do artykułu: „Hybrydowe, przekomorowe zamknięcie mięśniowych ubytków międzykomorowych”. *Kardiologia Pol*, 2013; 71: 211.
- Haponiuk I, Chojnicki M, Jaworski R et al. Delayed closure of multiple muscular ventricular septal defects in an infant after coarctation repair and a hybrid procedure: a case report. *Heart Surg Forum*, 2011; 4: E67–E69.
- Haponiuk I, Chojnicki M, Jaworski R et al. Miniinvasive hybrid closure of multiple muscular ventricular septal defects in premature infant with a novel use of Amplatzer Duct Occluder II: a case report. *Videosurgery Miniinv*, 2011; 6: 33–36.
- Haponiuk I, Chojnicki M, Jaworski R et al. Hybrid approach for closure of muscular ventricular septal defects. *Med Sci Monit*, 2013; 19: 618–624.
- Galantowicz M, Cheatham JP, Philips A et al. Hybrid approach for hypoplastic left heart syndrome: intermediate results after the learning curve. *Ann Thorac Surg*, 2008; 85: 2063–2071.
- Sroka M, Haponiuk I, Chojnicki M, Czauderna P. Cardiovascular hybrid procedure in severe congenital diaphragmatic hernia with significant left heart hypoplasia. *Eur J Cardiothorac Surg*, 2012; 42: 185–187.
- Chojnicki M, Haponiuk I, Jaworski R, Steffens M. Proximal ductus arteriosus stenosis after the hybrid stage I procedure in a newborn with hypoplastic left heart syndrome. *Postep Kardiol Interw*, 2013; 9: 187–189.
- Haponiuk I, Chojnicki M, Jaworski R et al. Gdansk Hybrid Heartlink Programme (GHHP) - we need to share the experience with miniinvasive hybrid procedures in borderline babies — letter to the Editor. *Videosur Miniinv*, 2013; 8: 238–240.
- Venugopal PS, Luna KP, Anderson DR et al. Hybrid procedure as an alternative to surgical palliation of high-risk infants with hypoplastic left heart syndrome and its variants. *J Thorac Cardiovasc Surg*, 2010; 139: 1211–1215.
- Gutgesell HP, Lim DS. Hybrid palliation in hypoplastic left heart syndrome. *Curr Opin Cardiol*, 2007; 22: 55–59.
- Pizarro C, Derby CD, Baffa JM et al. Improving the outcome of high-risk neonates with hypoplastic left heart syndrome: hybrid procedure or conventional surgical palliation? *Eur J Cardiothorac Surg*, 2008; 33: 613–618.

Zastosowanie procedur hybrydowych w leczeniu operacyjnym wybranych wrodzonych wad serca u dzieci: doświadczenia własne

Ireneusz Haponiuk¹, Maciej Chojnicki¹, Radosław Jaworski¹, Mariusz Steffens¹,
Aneta Szofer-Sendrowska¹, Jacek Juściński¹, Ewelina Kwaśniak¹, Wiktor Szymanowicz¹,
Katarzyna Gierat-Haponiuk², Katarzyna Leszczyńska³

¹Oddział Kardiochirurgii Dziecięcej, Pomorskie Centrum Traumatologii im. Mikołaja Kopernika, Gdańsk

²Klinika Rehabilitacji, Gdański Uniwersytet Medyczny, Uniwersyteckie Centrum Kliniczne, Gdańsk

³Klinika Położnictwa, Gdański Uniwersytet Medyczny, Uniwersyteckie Centrum Kliniczne, Gdańsk

Streszczenie

Wstęp: Mimo ciągłego postępu w zakresie technik diagnostycznych i terapeutycznych w ostatnich latach brakuje istotnego postępu w leczeniu wrodzonych wad serca. Czynione są intensywne wysiłki w kierunku doskonalenia kardiochirurgicznych technik operacyjnych oraz interwencji kardiologicznych, a także łączenia ich w celu uzyskania lepszego wyniku terapii. Zabiegi hybrydowe w leczeniu wrodzonych wad serca u dzieci zyskują coraz większą popularność, rozszerza się zakres wad serca leczonych w ten sposób oraz populacja pacjentów mogących być beneficjentami terapii hybrydowej. Współcześnie procedury hybrydowe stosuje się w sytuacjach, gdy rutynowe zabiegi kardiochirurgiczne lub przeszłokórne zabiegi interwencyjne nie przyniosłyby zadowalającego efektu terapeutycznego.

Cel: Celem pracy było przedstawienie własnych doświadczeń ośrodka we wdrażaniu i praktycznym zastosowaniu procedur hybrydowych w leczeniu wybranych wrodzonych wad serca u dzieci w latach 2008–2013.

Metody: Retrospektywnej analizie poddano własny materiał stanowiący grupę 80 pacjentów kwalifikowanych do procedur hybrydowych, wykonanych na Oddziale Kardiochirurgii Dziecięcej PCT w Gdańsku.

Wyniki: Wśród prezentowanej grupy 80 pacjentów żyje 73 dzieci; zanotowano 4 zgony wczesne i 3 późne.

Wnioski: Zabiegi hybrydowe u dzieci z wrodzonymi wadami serca łączą doświadczenia kardiochirurgii oraz kardiologii interwencyjnej i stanowią dodatkową opcję terapii dla wybranej grupy pacjentów. Wstępne wyniki leczenia hybrydowego są zachętą do dalszego rozwoju opisywanych metod i wypracowywania strategii w celu osiągnięcia optymalnej korzyści dla pacjenta.

Słowa kluczowe: wrodzone wady serca, kardiochirurgia dziecięca, leczenie hybrydowe

Kardiologia 2014; 72, 4: 324–330

Adres do korespondencji:

dr n. med. Ireneusz Haponiuk, Oddział Kardiochirurgii Dziecięcej, Pomorskie Centrum Traumatologii im. Mikołaja Kopernika, ul. Nowe Ogrody 1–6, 80–806 Gdańsk, tel: +48 58 76 40 659, e-mail: ireneusz_haponiuk@poczta.onet.pl

Praca wpłynęła: 15.09.2013 r.

Zaakceptowana do druku: 19.11.2013 r.

Data publikacji AoP: 27.11.2013 r.