

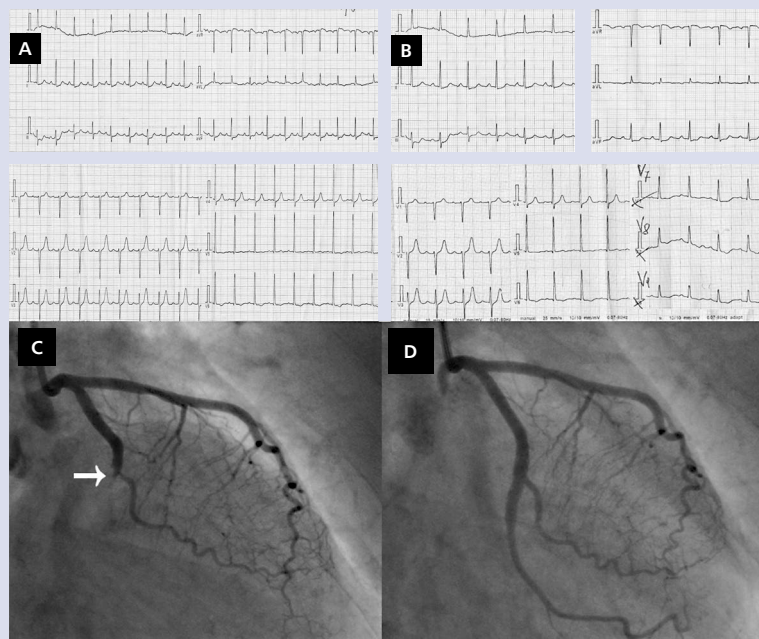
## CLINICAL VIGNETTE

# Myocardial infarction: when ST-segment elevation versus non-ST-segment elevation myocardial infarction paradigm fails

Michał Terlecki, Marek Rajzer, Danuta Czarnecka

1<sup>st</sup> Department of Cardiology, Interventional Electrophysiology, and Arterial Hypertension, Jagiellonian University Medical College, Krakow, Poland

According to the European Society of Cardiology guidelines for the management of patients with suspected myocardial infarction (MI), it is of crucial importance to establish the presence of ST-segment elevation on electrocardiogram (ECG) in order to determine the optimal management strategy [1]. Patients with ST-segment elevation MI (STEMI) are eligible for emergency reperfusion therapy, whereas those with non-ST-segment elevation MI (NSTEMI) require further risk stratification, and thus the referral for invasive diagnosis and reperfusion treatment is delayed. The STEMI-NSTEMI paradigm is based on the observation that ST-segment elevation seen on ECG in the majority of patients with MI is associated with total occlusion of infarct-related artery (IRA), while subtotal IRA occlusion most frequently leads to ST-segment depression and negative T-waves. However, when referral for emergent reperfusion therapy is based only on the ECG criteria for STEMI or NSTEMI diagnosis, we lose around 25% of patients with acute total occlusion of IRA who do not present ST-segment elevation on the ECG, indicative of STEMI [2]. This occurs frequently when IRA is the left circumflex artery (LCx) [3], which supplies the electrically silent posterior wall of the left ventricle and posterolateral papillary muscle and its occlusion may result in acute ischaemic mitral regurgitation. Thus, current qualification criteria are not optimal to select all the patients who would benefit from emergent reperfusion therapy. We describe a case of 73-year-old woman with a history of arterial hypertension and chest pain of few hours' duration, who was admitted to a non-percutaneous coronary intervention (PCI)-capable hospital. STEMI was excluded on the basis of ECG (Fig. 1A), but the troponin level was elevated. The patient, stratified as high-risk, was transferred to our PCI-capable hospital where ECG (including posterior leads) (Fig. 1B), blood sampling for troponin (markedly elevated), and echocardiography (regional motion abnormalities at the lateral and posterior wall with preserved global ejection fraction) were performed on admission. She was diagnosed with NSTEMI and transferred to a catheter lab without any redundant delay. Angiography revealed acute total occlusion of LCx (Fig. 1C), and the patient underwent PCI with stent implantation (Fig. 1D). Ischaemic time (from symptom onset to full flow restoration) reached more than 10 h. Even though the diagnostic process and treatment strategy were consistent with the current guidelines and no complication occurred, the length of hospital stay was extended. Based on cardiac biomarkers, the degree of cardiac injury was significant. Cardiac rehabilitation was prolonged. Finally, the patient was discharged home on the 10<sup>th</sup> day of hospital stay, in good clinical condition and with preserved left ventricular ejection fraction. Bearing in mind the fact that the specificity of ECG as a diagnostic tool for distinction between occluded and patent IRA during MI is unsatisfactory, upon assessment of a patient with MI, instead of focusing on diagnosing STEMI or NSTEMI, we should rather try to determine whether the patient has any signs and symptoms suggestive of an acute coronary occlusion and if he/she requires immediate intervention. It is also important to highlight that in patients with acute chest pain and low likelihood of pathology other than MI, coronary angiography should not be deferred, despite the lack of ST-segment elevation on ECG.



## References

1. Ibanez B, James S, Agewall S, et al. 2017 ESC Guidelines for the management of acute myocardial infarction in patients presenting with ST-segment elevation: The Task Force for the management of acute myocardial infarction in patients presenting with ST-segment elevation of the European Society of Cardiology (ESC). *Eur Heart J*. 2018; 39(2): 119–177, doi: [10.1093/eurheartj/ehx393](https://doi.org/10.1093/eurheartj/ehx393), indexed in Pubmed: [28886621](https://pubmed.ncbi.nlm.nih.gov/28886621/).
2. Schmitt C, Lehmann G, Schmieder S, et al. Diagnosis of acute myocardial infarction in angiographically documented occluded infarct vessel: limitations of ST-segment elevation in standard and extended ECG leads. *Chest*. 2001; 120(5): 1540–1546, indexed in Pubmed: [11713132](https://pubmed.ncbi.nlm.nih.gov/11713132/).
3. Krishnaswamy A, Lincoff AM, Menon V. Magnitude and consequences of missing the acute infarct-related circumflex artery. *Am Heart J*. 2009; 158(5): 706–712, doi: [10.1016/j.ahj.2009.08.024](https://doi.org/10.1016/j.ahj.2009.08.024), indexed in Pubmed: [19853686](https://pubmed.ncbi.nlm.nih.gov/19853686/).

**Figure 1.** A. Electrocardiogram (ECG) on admission to a non-percutaneous coronary intervention (PCI)-capable hospital; B. ECG on admission to a PCI-capable hospital; C. Coronary angiography (arrow shows the infarct-related artery); D. PCI — final outcome

## Address for correspondence:

Michał Terlecki, MD, PhD, 1<sup>st</sup> Department of Cardiology, Interventional Electrophysiology, and Arterial Hypertension, University Hospital, ul. Kopernika 17, 31–501 Kraków, Poland, tel: +48 12 424 73 00, fax: +48 12 424 73 20, e-mail: [michalte@poczta.onet.pl](mailto:michalte@poczta.onet.pl)

**Conflict of interest:** none declared

Kardiologia Polska Copyright © Polish Cardiac Society 2019