

CLINICAL VIGNETTE

Aortic dissection after sudden position change

Małgorzata Kabat^{1,2}, Aleksander Siniarski^{1,2}, Grzegorz Grudzien^{2,3}, Andrzej Gackowski^{1,2},
Jadwiga Nessler^{1,2}, Grzegorz Gajos^{1,2}

¹Department of Coronary Disease and Heart Failure, Faculty of Medicine, Jagiellonian University Medical College, Krakow, Poland

²The John Paul II Hospital, Krakow, Poland

³Department of Cardiovascular Surgery and Transplantology, Faculty of Medicine, Jagiellonian University Medical College, Krakow, Poland

A 42-year-old obese, hypertensive Caucasian man was urgently transferred to hospital from an outpatient clinic due to suspected acute coronary syndrome (ACS). On admission, he complained of dull retrosternal discomfort, accompanied by acute pain in the left inguinal region, spreading up to the abdomen. Symptoms occurred suddenly when the subject was rapidly changing the position from crouching to standing. Initial physical examination revealed a diastolic murmur over the aortic valve, as well as impaired sensation in and coldness of the left lower limb. Blood pressure was 146/59 mmHg. The lower abdominal area was tender on palpation. The physical exam did not reveal other abnormalities. Electrocardiogram showed inverted T-waves in leads V5 and V6. The level of creatine kinase (CK)-MB was moderately elevated but the levels of high-sensitivity cardiac troponin and CK were within reference ranges. On transthoracic echocardiography (TTE) severe aortic regurgitation (AR) and a suspicion of intimal flap in the aortic root were detected (Fig. 1A, B). Immediate computed tomography angiography (CTA) confirmed Stanford type A dissection affecting the entire aorta from the aortic root to both iliac arteries, spreading also to the brachiocephalic trunk (Fig. 1C) [1]. The patient underwent an immediate Bentall–De Bono procedure. The right common carotid artery access was used for arterial cannulation, and selective antegrade cerebral perfusion with mild (25°C–28°C) systemic hypothermic circulatory arrest was used. After completing the replacement of the aortic valve and ascending aorta, the arterial cannulation was switched to a Dacron

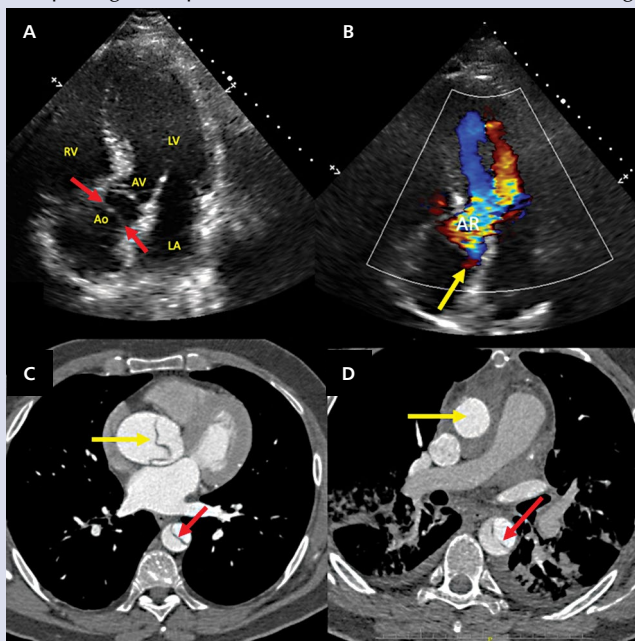


Figure 1. **A.** Apical five-chamber view showing suspected intimal flap (red arrows) very close to the aortic valve (AV, white arrow); LV — left ventricle; RV — right ventricle; LA — left atrium; Ao — aortic root; **B.** Corresponding five-chamber image in colour Doppler mode: perforation of the intimal flap (yellow arrow). LV outflow tract is totally filled by the severe aortic regurgitation jet (AR); **C.** Urgent computed tomography (CT) scan documenting dissection of the ascending and descending aorta (yellow and red arrows, respectively); **D.** Post-surgery CT scan showing normal ascending aortic prosthesis (yellow arrow) and residual dissection of the descending aorta (red arrow). Of note, before the surgery both false and true lumina of the descending aorta are equally filled with contrast, and the true lumen (red arrow) is smaller compared to the false lumen (C). Post-surgery the contrast is predominantly present in true lumen (red arrow; D). True lumen post-surgery is larger than the false lumen

aortic prosthesis in order to achieve better reperfusion and reduce the risk of multi-organ ischaemia. Further course was uneventful. The limb ischaemia was relieved, and no neurological deficits occurred. The cardiac function was normal. CTA revealed normal function of the ascending aortic prosthesis and residual dissection of the remaining aorta (Fig. 1D). No complications occurred at one-year follow-up. It is crucial to differentiate the cause of chest pain in patients referred with a working diagnosis of ACS. The detailed history of rapid onset of symptoms after postural change, coincidence of lower limb ischaemia and AR murmur, together with the result of immediate TTE totally changed the clinical course. A CT scan, instead of an initially planned coronary angiography, was immediately performed and urgent cardiac surgery was necessary. Bedside TTE screening, particularly in patients with atypical presentation, is indicated according to the ACS guidelines. Aortic dissection remains a rare but important, life-threatening condition that may mimic several diseases, depending on dissection localisation. Rapid treatment prevented the patient from further complications, including tamponade or vital organ ischaemia. Stenting of the remaining aortic dissection should be considered, and optimal antihypertensive treatment and follow-up are mandatory.

References

1. Erbel R, Aboyans V, Boileau C, et al. ESC Committee for Practice Guidelines. 2014 ESC Guidelines on the diagnosis and treatment of aortic diseases: Document covering acute and chronic aortic diseases of the thoracic and abdominal aorta of the adult. The Task Force for the Diagnosis and Treatment of Aortic Diseases of the European Society of Cardiology (ESC). *Eur Heart J*. 2014; 35(41): 2873–2926. doi:10.1093/eurheartj/ehu281, indexed in Pubmed: 25173340.

Address for correspondence

Aleksander Siniarski, MD, Department of Coronary Disease and Heart Failure, Faculty of Medicine, Jagiellonian University Medical College, The John Paul II Hospital, ul. Piłsudnicka 80, 31–202 Kraków, Poland, tel: +48 12 614 30 66, e-mail: aleksandersiniarski@gmail.com

Conflict of interest: none declared

Kardiologia Polska Copyright © Polish Cardiac Society 2019