

CLINICAL VIGNETTE

Recurrent pneumonia and pulmonary embolism in a young patient as a presentation of right ventricular myxoma

Anna Szerszyńska¹, Radosław Nowak², Grzegorz Łaskawski², Marcin Fijałkowski³

¹University Clinical Centre in Gdansk, Gdansk, Poland

²Department of Cardiac and Vascular Surgery, Medical University of Gdansk, Gdansk, Poland

³1st Department of Cardiology, Medical University of Gdansk, Gdansk, Poland

Primary cardiac tumours are extremely rare, and the majority of them are benign, mostly myxomas. Overall, 75%–80% of them are located in the left atrium, 10%–20% are in the right atrium (RA), and only 5%–10% are found in both atria or a ventricle. Location in the right ventricle (RV) could be associated with a variety of symptoms, such as pulmonary embolism (PE), obstruction of the RV outflow tract, arrhythmias, and systemic symptoms. We present a case of a 24-year-old man who was admitted to the pulmonology unit with productive cough, haemoptysis, chest pain, and fever. The initial diagnosis was recurrent right-sided pneumonia. A year earlier the patient was hospitalised due to similar symptoms and pneumonia was confirmed by computed tomography (CT). Between both hospitalisations he was asymptomatic. CT revealed the presence of fluid in the right pleural space and opacification in the right lung, indicative of inflammation and atelectasis. The level of C-reactive protein was elevated. Because it was a recurring pneumonia in the same location, a blood test for HIV infection was performed with negative results. The patient was treated with clarithromycin 500 mg/day and ceftriaxone 1 g/day, and subsequently the symptoms of infection decreased. After four days, due to persistent fluid in the pleural space and an increased level of D-dimer, CT angiography was performed in search of PE. The examination revealed acute thromboembolism in the right pulmonary artery, which was accompanied by changes characteristic of chronic PE. In addition, a structure measuring 2.6 × 1.2 cm was found in the RV (Fig. 1A). Transoesophageal echocardiography revealed mild RV dilatation, right atrial enlargement, and a pathological mass attached to the RV apex, which was considered to be a cardiac tumour or a thrombus. Fraxiparine 7600 IU twice a day was administered, and further diagnostic tests were carried out. Cardiac tumours are usually secondary, so additional imaging was required to search for primary tumours. Abdominal and pelvic CT, testicular ultrasonography, and dermatoscopy were performed, but they did not reveal any suspicious lesions. The occurrence of PE in a young patient without any risk factors was an indication for a complex haematologic examination. Laboratory tests for the most common congenital thrombophilias were negative. Cardiac magnetic resonance imaging confirmed the initial dimensions of the pathological mass in the RV (Fig. 1B). The lesion had low mobility, which was unusual for a thrombus in this location. A lack of decrease in the size, despite over two weeks of optimal antithrombotic treatment, was suggestive of a tumour. The patient was transferred to the Department of Cardiac and Vascular Surgery. Excision of the tumour was carried out using minimally invasive port-access approach through right mini-thoracotomy. Under general anaesthesia and with the use of cardiopulmonary bypass and cardioplegic arrest, the RA was opened. Opening the tricuspid valve revealed a rounded mass attached to the RV apex. The tumour was connected to the walls of the RV and papillary muscles with many protrusions but it did not invade the heart muscle and was totally excised (Fig. 1C). A histopathological examination of the tumour revealed myxoma covered with thrombus. One month later the patient was admitted to hospital due to a suspicion of endocarditis. He reported fever, dyspnoea, and tachycardia lasting for five days. Transthoracic echocardiography (TTE) revealed two floating structures in the RA attached to the ceiling and the lower part of the interatrial septum, which were suspected to be bacterial vegetations or thrombi (Fig. 1D, [Suppl. Video 1 — see journal website](#)). Antibiotic therapy with vancomycin (30 mg/kg/day) and gentamicin (3 mg/kg/day) was started and enoxaparin (2 × 90 mg) was administered. Six days later negative results of blood cultures were obtained, so only antithrombotic treatment with enoxaparin overlapping with warfarin was continued. On control TTE the structures decreased and finally disappeared. The patient was referred to a haematologist and a rheumatologist for further diagnostic tests to determine the cause of recurrent thrombosis. After a series of examinations, no abnormalities were found. During one-year follow-up the patient did not report similar symptoms, and TTE showed no recurrence of the tumour.

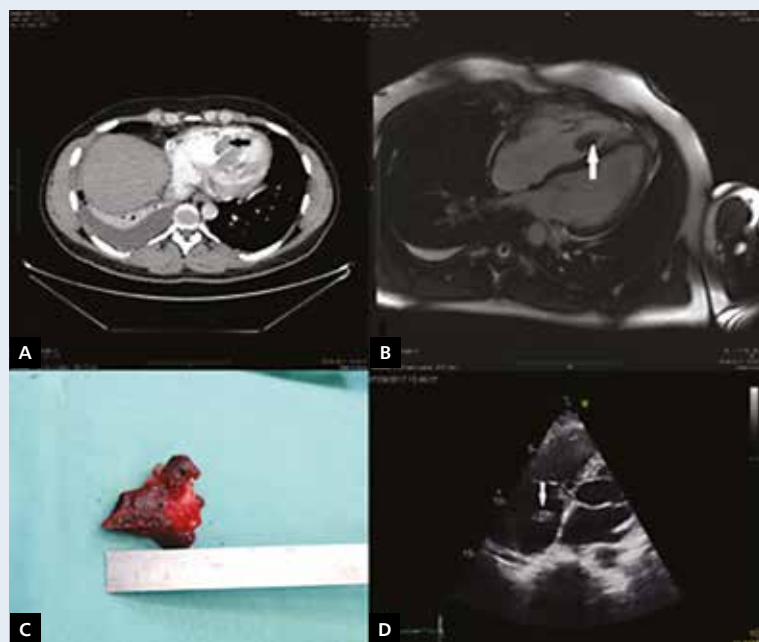


Figure 1. A. Tumour on computed tomography; B. Tumour on magnetic resonance imaging (arrow); C. Excised tumour covered with thrombus; D. Thrombus on echocardiography (arrow)

Address for correspondence:

Dr. Anna Szerszyńska, University Clinical Centre in Gdansk, ul. Dębinki 7, 80-211 Gdańsk, tel: 512 343 012, e-mail: annam-p@gumed.edu.pl

Conflict of interest: none declared

Kardiologia Polska Copyright © Polish Cardiac Society 2019