

CLINICAL VIGNETTE

Right aortic arch with isolated left subclavian artery: a rare association with coarctation of the left pulmonary artery

Peter Olejník^{1,2}, Pavol Kunovsky², Zuzana Venczelova², Darina Buzassyova³, Lenka Majerova¹

¹Medical Faculty Clinic of Paediatric Cardiology, Comenius University in Bratislava, Bratislava, Slovakia

²National Institute of Cardiovascular Diseases of Slovak Republic, Paediatric Cardiocentre, Bratislava, Slovakia

³Paediatric Clinic of Anaesthesiology and Intensive Care, Medical Faculty of Comenius University and Slovak Medical University, Bratislava, Slovakia

A hypotrophic seven-month-old boy was admitted to a paediatric intensive care unit due to severe respiratory distress. Echocardiography performed due to the murmur revealed dilated right ventricle with subsystemic pressures. Computed tomography angiography depicted the right aortic arch (RAA) with isolated left subclavian artery (ILSA) originating from the left-sided patent ductus arteriosus (PDA), significant stenosis of the proximal left pulmonary artery (LPA), and two aortopulmonary collaterals (Fig. 1). With the intention to establish a sufficient flow through the LPA, a percutaneous Palmaz Genesis stent (PG1560PPS; Cordis, Johnson & Johnson, Miami, FL, USA) was implanted into the LPA. Because the stent migrated into the right pulmonary artery (RPA) after its deployment, a wider and longer PalmazBlue stent (PB2470PPS; Cordis, a Cardinal Health Company, Baar, Switzerland) was implanted into the LPA, significantly larger in diameter than the previous one (6.0 vs. 1.7 mm) (Fig. 2). Later on, when pulmonary arterial hypertension regressed, the patient was successfully weaned off the ventilator. Stenosis of proximal LPA can be caused by an extension of ductal tissue into the wall of the LPA. Therefore, the term “coarctation” of the LPA is also appropriate. Surgical removal of ductal tissue and LPA plasty should be performed to establish adequate blood flow through the left lung. Due to our patient’s poor clinical condition, a less invasive percutaneous LPA rehabilitation was performed. Percutaneous stent redilatation is planned in the

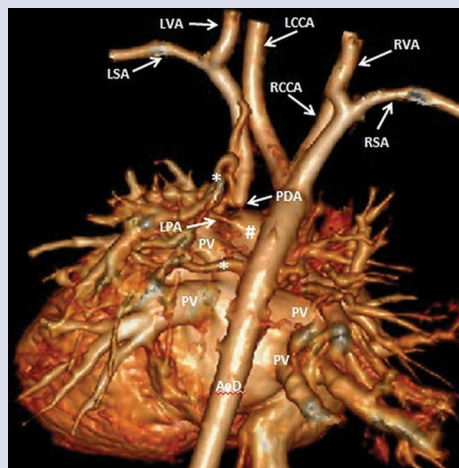


Figure 1. Computed tomography angiography. Three-dimensional virtual reconstruction. Posterior view; LPA — left pulmonary artery; PDA — trivial patent ductus arteriosus; AoD — descending aorta; PV — pulmonary vein; LSA — left subclavian artery; LVA — left vertebral artery; LCCA — left common carotid artery; RCCA — right common carotid artery; RSA — right subclavian artery; RVA — right vertebral artery; #Right pulmonary artery; *aortopulmonary collaterals

future. ILSA is a rare aortic arch anomaly seen in 0.8% of RAAs. It is usually diagnosed incidentally together with other cardiac anomalies, typically with tetralogy of Fallot. The embryologic development of this malformation can be explained by regression of the left aortic arch between the left common carotid artery and the left subclavian artery (LSA), as well as between the LSA and the descending aorta, with persistence of a small bridge of the left arch connecting the left PDA to the LSA. Patients with this anomaly are usually asymptomatic. If present, symptoms of vertebrobasilar insufficiency (headache, impaired vision, or syncope) and/or left limb ischaemia (weakness, pain, and coldness) can be explained by inverted flow through the left vertebral artery into the LSA, especially during left arm exercise. Patients with significant PDA may also present with signs of pulmonary steal syndrome. Due to insignificant shunt through the left-sided PDA to the pulmonary circulation the ligation of the PDA was not performed at that time. To our knowledge, this is the first report of right aortic arch with ILSA associated with LPA coarctation. Except for essential LPA coarctation treatment in infancy, an ILSA reimplantation onto the aortic arch should be considered if clinical signs of vertebrobasilar insufficiency appear in later course.

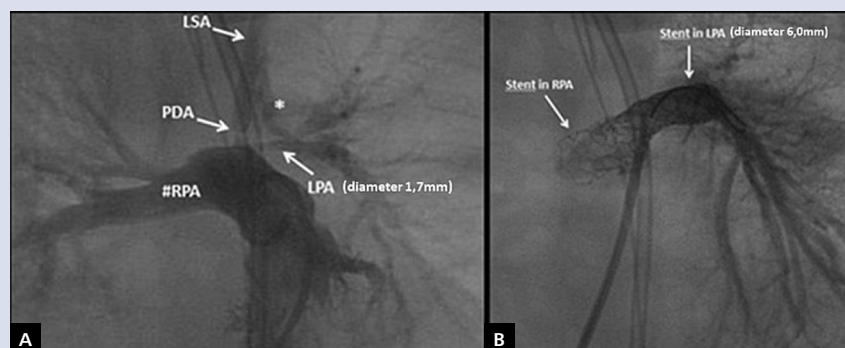


Figure 2. Angiography — anteroposterior view with cranial angulation; **A.** Native angiography; #RPA — right pulmonary artery; *aortopulmonary collaterals; **B.** Angiography after stent implantation into RPA and LPA; other abbreviations — see Figure 1

Address for correspondence:

Dr. Peter Olejník, Paediatric Cardiology, National Institute of Cardiovascular Diseases, Children’s Cardiac Centre, Bratislava, Limbová 1, 83101 Slovakia, e-mail: petoolejnik@gmail.com

Conflict of interest: none declared

Kardiologia Polska Copyright © Polish Cardiac Society 2018