

## CLINICAL VIGNETTE

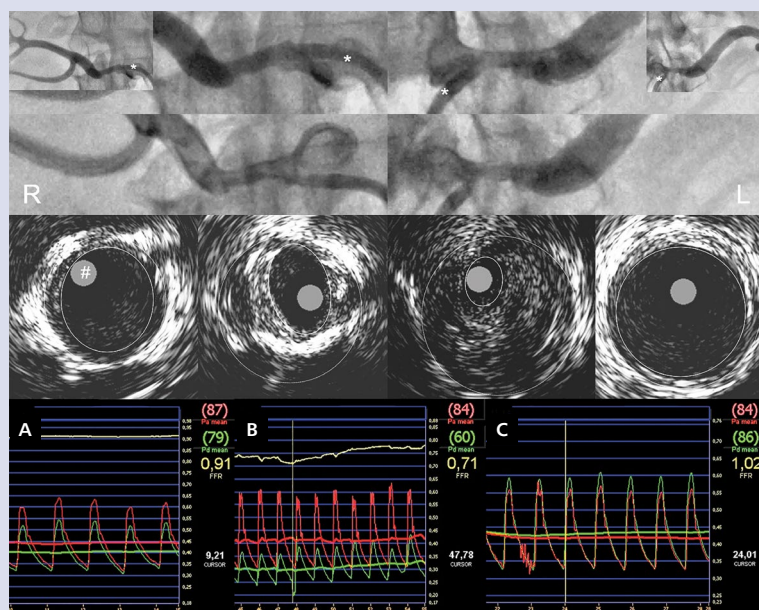
# Borderline bilateral renal artery stenosis assessed with high-resolution angiography, intravascular ultrasound, and renal fractional flow reserve in a patient with renovascular hypertension

Kamil Zieliński<sup>1</sup>, Łukasz Kalińczuk<sup>2</sup>, Jacek Kądziała<sup>2</sup>, Adam Witkowski<sup>2</sup>

<sup>1</sup>Medical University of Warsaw, Warsaw, Poland

<sup>2</sup>Institute of Cardiology, Warsaw, Poland

Renal artery stenosis (RAS) is a common cause of secondary hypertension. Clinical benefits of percutaneous transluminal angioplasty (PTA) for RAS remain controversial, probably depending on correct patient selection. They are especially difficult to assess because of frequent occurrence of borderline lesions of 50% to 70% stenosis on angiography. A few parameters evaluating the physiological severity of RAS have been proposed, but their clinical effectiveness has not been confirmed (e.g. translesional rest pressure gradient [TSPG] and hyperaemic systolic pressure gradient [HSPG], renal fractional flow reserve [rFFR], or minimal lumen area [MLA] on intravascular ultrasound [IVUS]). We present a 72-year-old male patient with renovascular hypertension and poor response to multi-drug treatment, in whom IVUS imaging and invasive pressure wave measurements were performed to assess bilateral RAS. Ultrasonography revealed no kidney abnormalities. Doppler ultrasound showed increased peak systolic velocity (PSV) and renal aortic ratio (RAR) in the left renal artery (LRA), indicating physiologically significant stenosis (240 cm/s vs. 190 cm/s PSV in the right renal artery [RRA]; cut-off 200 cm/s; RAR 4 vs. 3 in RRA; cut-off 3.5). Respective renal arterial resistive indexes (RIs) were 0.59 vs. 0.67 ( $\Delta RI > 0.05$ ). Angiography showed a borderline bilateral RAS. Remarkably, despite similar angiographic appearance, the LRA and RRA differed in terms of MLA and calculated percentage of plaque burden measured with IVUS (Eagle Eye<sup>®</sup>, 20 Mhz, Volcano Corp., Rancho Cordova, CA, USA). The results for LRA were  $< 3.0 \text{ mm}^2$  MLA and  $\sim 90\%$  plaque burden. The corresponding values for RRA were  $9.7 \text{ mm}^2$  MLA and  $\sim 60\%$  plaque burden (Fig. 1, middle row). Simultaneous pressure measurements made at rest and during hyperaemia, distally and proximally to the evaluated lesions, in both the LRA and RRA, allowed us to determine respective values: TSPG 34 mmHg vs. 10 mmHg, HSPG 48 mmHg vs. 20 mmHg; cut-off 20 mmHg, and rFFR 0.71 vs. 0.91; cut-off 0.9 (Fig. 1B and Fig. 1A, respectively). Finally, a Herculink Elite (Abbott Vascular, Santa Clara, CA, USA)  $6.0 \times 18\text{-mm}$  stent (14 atm) was successfully implanted in the LRA, and a normal blood flow was restored, as documented with rFFR (Fig. 1C). Doppler ultrasound confirmed normalisation of PSV and RAR. In long-term follow-up improvement of blood pressure control was achieved. Our case report provided a unique and detailed insight into the complex clinical assessment of physiological significance of RAS, with successful restoration of a normal renal blood flow with PTA.



**Figure 1.** Upper rows, below one another: the two consecutive angiographic frames recorded with Siemens™ AXIOM (1024 × 1024, 15 f/s), showing the narrowest segments of a borderline bilateral stenosis of the right (R) and left (L) proximal renal arteries. Middle row: overlaid vessel cross-sections obtained with intravascular ultrasound (with transducer [#] inside), and within respective distal references (dashed line — external elastic membrane; solid line — lumen dimension). Lower row: pressure waves recorded during hyperaemia, distally to the stenosis (green line), and simultaneously in the aorta (red line), in the right renal artery (A) and in the left renal artery (pre- and post-stenting, B and C, respectively). Asterisk marks the tip of the catheter (\*)

#### Address for correspondence:

Kamil Zieliński, Department of Coronary and Structural Heart Diseases, The Cardinal Stefan Wyszyński Institute of Cardiology, ul. Alpejska 42, 04-628 Warszawa, Poland, e-mail: kamilziel@gmail.com

**Conflict of interest:** none declared

Kardiologia Polska Copyright © Polish Cardiac Society 2018