

Takotsubo syndrome after bone cement injection during hip replacement

Zespół Takotsubo po podaniu cementu kostnego podczas operacji stawu biodrowego

Elena Todorova Kinova¹, Plamen Slavov Kinov², Neli Georgieva Nikolova¹, Assen Rachev Goudev¹

¹Department of Cardiology, University Hospital "Tsaritsa Yoanna – ISUL", Sofia, Bulgaria

²Department of Orthopaedic Surgery, University Hospital "Tsaritsa Yoanna – ISUL", Sofia, Bulgaria

A 59-year-old woman with coxarthrosis was admitted to the Department of Orthopaedic Surgery for elective hip replacement. Preoperative examination revealed treated hypertension and previous knee replacement. Laboratory data were within referent range. A cemented prosthesis was implanted under spinal anaesthesia. During the surgery, after injecting the bone cement, severe bradycardia and hypotension to cardiogenic shock developed. The patient complained of chest discomfort. The electrocardiogram (ECG) showed sinus rhythm and significant ST-elevation in I, II, aVL, and precordial V5–V6 leads (Fig. 1). The surgical procedure was finished in a short time. Haemodynamic deterioration gradually restored after intravenous administration of atropine, hydro-electrolytic solutions, and dopamine. The patient was transferred to the Cardiac Intensive Care Unit. Echocardiography revealed dyskinetic apex, hypokinetic mid-level segments, and hyperkinetic basal segments of the left ventricle (LV; Fig. 2). Ejection fraction (EF) reduced to 45%. There was mild LV outflow tract obstruction with peak gradient 33 mm Hg. Although acute coronary syndrome (ACS) with ST-elevation was diagnosed initially, there was clinical suspicion of stress-induced (Takotsubo) cardiomyopathy. Several hypotheses had been discussed: ACS with shock, "bone cement implantation syndrome (BCIS)" with vasodilation and ACS, and Takotsubo syndrome triggered by stress or by vasoactive reaction after cement injection. The decision was made to perform coronary angiography, but within 15 min the ST-depression reduced significantly and the patient became asymptomatic. One hour later the ST-elevation fully resolved, and ventricular premature complexes with right bundle branch block morphology appeared. Wall motion abnormalities slightly improved. Due to quick reversal of ECG and echocardiographic abnormalities, and the patient's refusal of coronary angiography, we decided to continue medical therapy. The initial high-sensitivity troponin level was 17.9 pg/mL and reached maximum 4039 pg/mL later. In addition to other signs, the lack of severe myocardial necrosis supported the diagnosis of Takotsubo cardiomyopathy. Treatment with hydro-electrolytic solutions, nadroparin calcium 0.4 mL b.i.d. s.c., acetylsalicylic acid 100 mg q.d., bisoprolol 2.5–5 mg q.d., ramipril 2.5 mg q.d., and atorvastatin 20 mg q.d. was administered. On the next day the patient was asymptomatic, with blood pressure 120/70 mm Hg and heart rate 75 bpm. The ECG showed newly developed diffuse negative T-waves (Fig. 3). Regional kinetic abnormalities resolved (Fig. 4) and EF improved to 65%. On the fifth postoperative day the woman was transferred to the Department of Orthopaedic Surgery, where she started specific rehabilitation. The patient was discharged on the eleventh day after the hip replacement. The ECG and echocardiography were normal. During the five-month follow-up several examinations were performed by a cardiologist and orthopaedic surgeon, with no cardiac symptoms and good postoperative results. In this case report, Takotsubo syndrome seemed to be triggered by the injection of pressurised cement during hip replacement, mimicking a severe BCIS with ACS. As far as we know, there is only one such case reported in the literature.

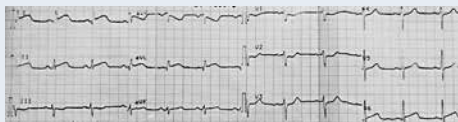

Figure 1. Electrocardiogram at the time of the event

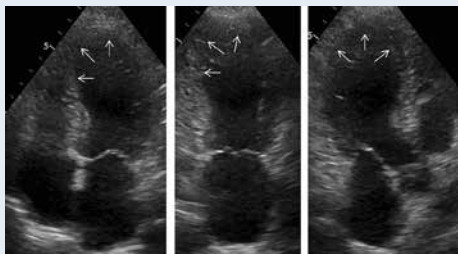


Figure 2. Echocardiography — apical ballooning and hypercontractile basal segments at early stage

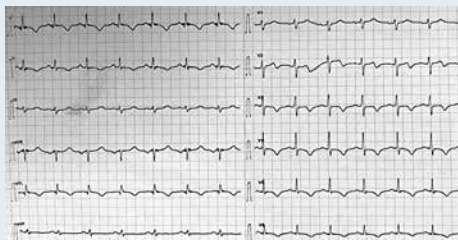

Figure 3. Electrocardiogram 24 h after the event

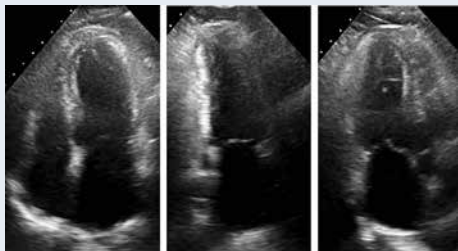


Figure 4. Resolution of wall motion abnormalities 24 h after the event

Address for correspondence:

Assoc. Prof. Elena Todorova Kinova, Department of Cardiology, University Hospital "Tsaritsa Yoanna – ISUL", 'Byalo more' Str. No. 8, Sofia 1527, Bulgaria, e-mail: kinova.e@abv.bg

Conflict of interest: none declared

Kardiologia Polska Copyright © Polskie Towarzystwo Kardiologiczne 2017