

Left main coronary artery quadrifurcation and acute coronary syndrome

Czwórpodział pnia lewej tętnicy wieńcowej i ostry zespół wieńcowy

Paweł Tyczyński¹, Jerzy Pręgowski¹, Jarosław Skowroński¹, Izabela Wojtkowska², Aleksandra Brutkiewicz¹, Adam Witkowski¹

¹Department of Interventional Cardiology and Angiology, Institute of Cardiology, Warsaw, Poland

²Department of Intensive Cardiac Therapy, Institute of Cardiology, Warsaw, Poland

Percutaneous coronary intervention (PCI) of unprotected left main coronary artery (LMCA) trifurcation/quadrifurcation is challenging. However, during acute coronary syndrome (ACS), LMCA PCI may offer better acute and long-term results compared to surgical treatment. Furthermore, elective PCI for bifurcated LMCA is associated with better results compared to trifurcated LMCA. No such comparison exists for ACS-patients. Moreover, there are only single reports of PCI for LMCA quadrifurcation. We present a case of an ACS-patient due to culprit lesion located in LMCA quadrifurcation, who required urgent revascularisation due to unstable haemodynamics. The 65-year-old patient was admitted with recurrent chest pain. Electrocardiogram showed ST depression in precordial V4–V6, I, and aVL leads. Urgent angiography revealed LMCA quadrifurcation with ostial plaque involvement of all four LMCA branches (Fig. 1). After an immediate heart-team decision, LMCA PCI was performed. After wiring the left anterior descending coronary artery (LAD), second intermediate coronary artery (IM), and left circumflex coronary artery (LCX), (Fig. 2A), predilatation of the LAD ostium was performed. Next, a 3.5 × 20 mm everolimus eluting stent was implanted from the proximal LAD to distal LMCA segment (Fig. 2B). TIMI 3 flow was preserved in all LMCA branches. However, after LAD/LMCA postdilatation with 4.0 mm non-compliant balloon (proximal optimisation technique [POT]), (Fig. 2C), severely impaired flow (TIMI 1) in both IM branches and LCX was observed (Fig. 2D). The patient became severely hypotensive. After bail-out intravenous administration of IIb/IIIa inhibitor and postdilatation of IM and LCX ostia, TIMI 3 flow was restored (Fig. 2E). Nonetheless, clinical deterioration required intubation with mechanical ventilation, intravenous infusion of catecholamines, and transitional manual chest compression. Intra-aortic balloon pump was inserted and maintained for 13 days. The patient was mechanically ventilated for 14 days. Maximal troponin T rise up to 8628 ng/L (UNL < 14) was noted the next day after PCI. Echocardiography revealed severely impaired left ventricle function (ejection fraction 15–20%). No systematic study of ACS-patients due to culprit lesions located at LMCA dividing into more than two branches exists. PCI technique and procedural success depends largely on the type of LMCA lesion involvement and concomitant coronary narrowings. Analogically to PCI of an LMCA bifurcation lesion, the one-stent technique may lead to better long-term results compared to two-stent technique for LMCA trifurcation/quadrifurcation lesion. Distortion of the main vessel stent segment after kissing balloon inflation is common. In our case POT caused plaque shift from LAD to IM and LCX ostia with their subsequent acute occlusion. One might speculate that pre-POT predilatation of IM, LCX branches might help avoid such trouble. In contrast to the two-stent technique, where final POT should be considered, liberal use of POT after the one-stent technique is allowed. In conclusion, in very selected, unstable ACS-patients, immediate PCI of LMCA multifurcation may be required.

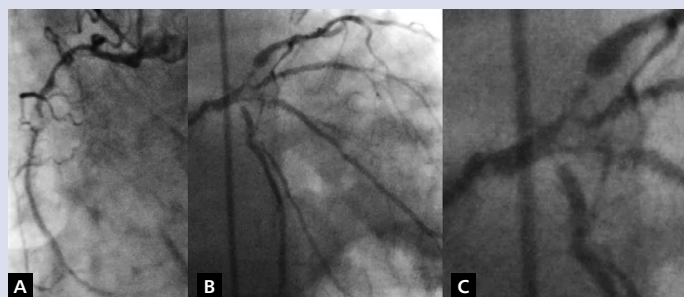


Figure 1. A. Critical stenosis in right coronary artery; B. Critical ostial stenoses in left main coronary artery branches; C. Magnification of the image "B"

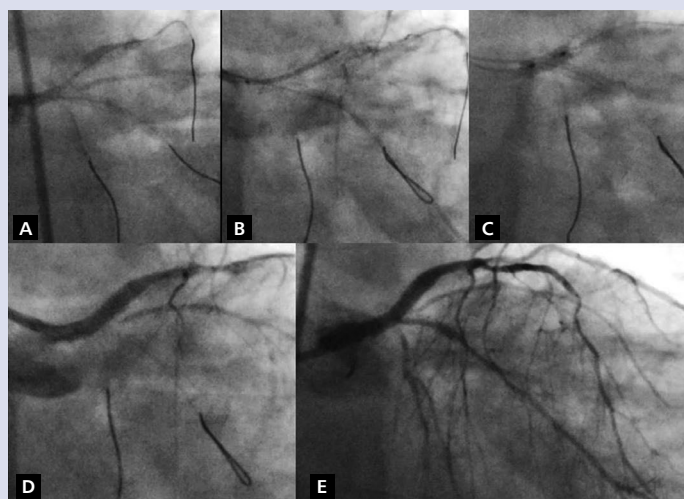


Figure 2. A. Wiring of three branches; B. Stent positioning; C. Proximal optimisation technique; D. Severely impaired flow in intermediate branches and left circumflex coronary artery; E. Final result

Address for correspondence:

Paweł Tyczyński, MD, PhD, Department of Interventional Cardiology and Angiology, Institute of Cardiology, ul. Alpejska 42, 04-628 Warszawa, Poland, e-mail: medykpol@wp.pl

Conflict of interest: none declared

Kardiologia Polska Copyright © Polskie Towarzystwo Kardiologiczne 2017