

Cardiac approach to a patient with breast cancer and metastases in musculoskeletal system

Podejście kardiologiczne do pacjentki z nowotworem piersi i przerzutami do układu kostno-stawowego

Paweł Łęgosz¹, Paweł Małdyk¹, Anna E. Płatek², Filip M. Szymański²

¹Department of Orthopaedics and Traumatology of the Musculoskeletal System, Medical University of Warsaw, Warsaw, Poland

²1st Department of Cardiology, Medical University of Warsaw, Warsaw, Poland

A 47-year-old, obese female was referred to the orthopaedist by an oncologist. Two years prior to the referral the patient was diagnosed with malignant cancer of the right breast (pT2N0(0/1)M0). Histological diagnosis was invasive carcinoma NST G2, with positive ER, positive PR, HER2 (0), and Ki67 (30%). She was treated with tumorectomy with a resection of the sentinel node and subsequent hormone therapy and chemotherapy (with doxorubicin and cyclophosphamide). After the tumorectomy she underwent a second operation to resect excessive scar tissue. Following this she did not have signs of local cancer recurrence for over a year. Subsequently she came to the oncologist complaining on limping and pain in the right hip. She had multiple imaging modalities performed that showed signs of metabolically active metastases in the proximal part of the right femur (Fig. 1). In the Harris Hip Score (a questionnaire assessing performance in hip disease) she scored 38 out of 100 points, which is consistent with poor performance. Orthopaedic assessment showed the possibility of a pathological fracture, and the patient was qualified for total hip replacement and subsequent radiotherapy. The patient had never complained cardiovascular disease in the past. Also, she was never assessed by a cardiologist, even prior to the first round of chemotherapy. Nevertheless, as a part of the standard protocol used in the Orthopaedic Department in patients with malignancy scheduled for hip replacement, she was referred for cardiologic evaluation. In addition to a standard follow-up, she had an echocardiography, ambulatory blood pressure (BP) monitoring, and electrocardiogram using telemedical equipment (Fig. 2). All tests showed normal results, except for mild atrial enlargement and inverse dipping BP pattern (mean 24-h BP 120/73 mm Hg). For cardioprotection before operation and oncological treatment the patient was prescribed ramipril 2.5 mg/day, nebivolol 5 mg/day, and rosuvastatin 20 mg/day. Total hip replacement with the use of bone cement was performed (Fig. 3). The patient was rehabilitated and achieved full recovery (Fig. 4). She was scheduled for radiotherapy and underwent another cardiac evaluation. Six months after the surgery she was in good general condition, with no signs of cancer recurrence or cardiac damage. A multi-specialist approach to patient care is currently crucial for modern management of patients. In orthopaedics hip replacement is a procedure associated with one of the greatest risks of periprocedural complications, including cardiovascular complications such as myocardial infarction, stroke, or thromboembolic complications. Also, oncology treatment, including chemo- and radiotherapy, is associated with various forms of cardiovascular events. Therefore, proper cardiac evaluation and treatment, in both primary and secondary prevention, should be introduced in all patients with cancer and orthopaedic complications.

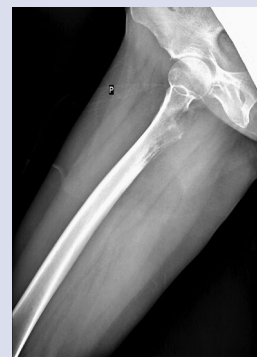

Figure 1. Radiogram of the metastatic tumour in the right femur

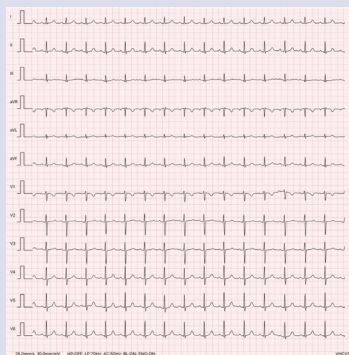


Figure 2. Results of electrocardiogram

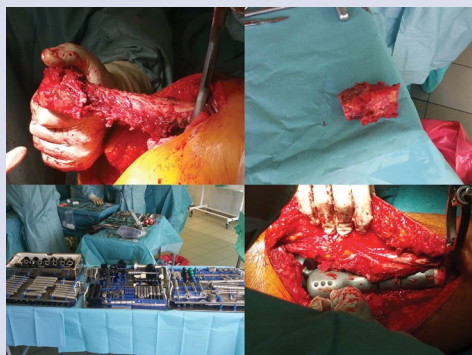


Figure 3. Intraoperative pictures

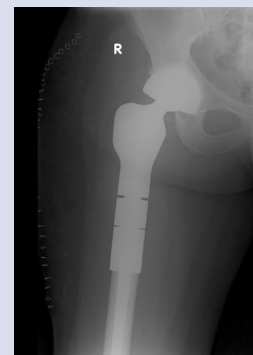


Figure 4. Radiogram of the hip joint prosthesis after total replacement

Address for correspondence:

Paweł Łęgosz, MD, PhD, Department of Orthopaedics and Traumatology of the Musculoskeletal System, Medical University of Warsaw, ul. Lindleya 4, 02-005 Warszawa, Poland, e-mail: pawel.legosz@wum.edu.pl

Conflict of interest: none declared

Kardiologia Polska Copyright © Polskie Towarzystwo Kardiologiczne 2017