

Acute coronary syndrome as the first manifestation of Takayasu's disease

Ostry zespół wieńcowy jako pierwsza manifestacja choroby Takayasu

Jan Z. Peruga, Łukasz Figiel, Jarosław D. Kasprzak

Department of Cardiology, Medical University of Lodz, Lodz, Poland

A 39-year-old woman was admitted to hospital due to typical angina pectoris of three months' duration progressing to Canadian Cardiovascular Society class III. There was no previous medical history or family history of coronary artery disease. Coronary risk factors except for smoking were absent. On admission she presented tachycardia 92/min and with 2 mm ST segment depression in II, III, aVF leads on 12-lead electrocardiogram (Fig. 1A). Laboratory tests showed elevated: troponin T (0.8 ng/mL) and CK-MB white blood cell count (11,100/ μ) and test C-reactive protein (CRP; 28 mg/L) with mildly elevated immunoglobulins (IgA, IgM, IgG) indicating an inflammatory process. Echocardiography showed normal left ventricular (LV) function with ejection fraction 62%. LV relaxation was abnormal and pulmonary vein flow suggested mild elevation of LV end-diastolic pressure. Coronary angiography revealed severe bilateral ostial stenosis — 95% in the right and 80% in the left coronary artery (Fig. 1B, C). Colour Doppler mapping of coronary ostia showed turbulent high-velocity (diastolic component > 1.5 m/s; Fig. 1E) flow suggestive of bilateral ostial coronary stenosis. Ultrasound examination of the aortic arch suggested additionally left subclavian stenosis and bilateral carotid lesions (Fig. 1F). The patient underwent 64-row computed tomography to define stenoses in other major arteries. The scan confirmed critical ostial stenotic right and left coronary artery (Fig. 1D) and revealed inflammatory thickening of ascending and descending aorta, significant stenosis of both carotid and both subclavian arteries, and noncritical involvement of left and right vertebral arteries (Fig. 1G). Additionally, the left renal artery had 85% proximal stenosis. According to her symptoms, the patient was treated with coronary angioplasty (percutaneous coronary intervention) with bare metal stenting 4.0 × 16 mm in the ostium of the right coronary and 4.5 × 12 mm into the left main coronary artery ostium without residual stenosis and good early result. Anti-inflammatory therapy with prednisolone was instituted starting from 60 mg per day, and during one month we observed the normalisation of inflammatory parameters such as white cell count, level CRP, and erythrocyte sedimentation rate. Our patient presented an uncommon form of Takayasu arteritis initially manifesting as coronary acute syndrome due to critical ostial left and right coronary artery stenosis, initially detected on electrocardiogram and angiogram. Further multimodality workup showed severe arteritis in all arch branches and additionally in the renal artery (type V, C+). Therefore, we decided to embrace the percutaneous strategy, which led to symptomatic improvement.

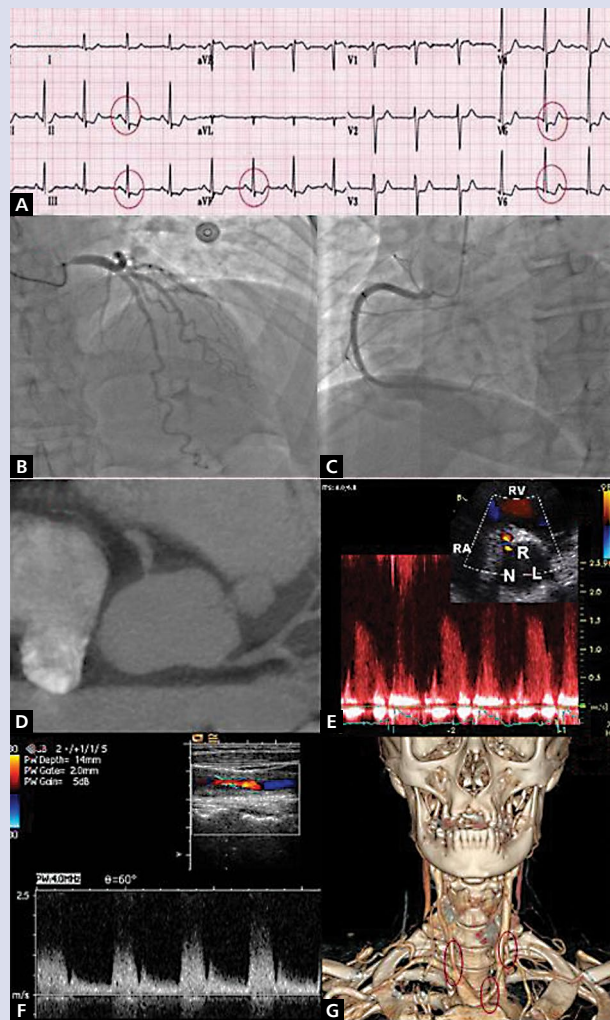


Figure 1. A. Electrocardiogram with 2 mm ST segment depression in II, III, aVF leads; B. Left artery with ostial stenosis; C. Right artery with ostial stenosis; D. Computed tomography showing bilateral critical ostial coronary stenosis; E. Ostial turbulence and high-velocity flow in the right artery (RA) demonstrated by transthoracic echocardiography; RV — right ventricle; F. Abnormal colour Doppler of the middle portion of the right common carotid artery; G. Three-dimensional reconstruction showing right common carotid stenosis, ostial left carotid stenosis, and ostial stenosis of vertebral arteries

Address for correspondence:

Prof. Jarosław D. Kasprzak, Department of Cardiology, Medical University of Lodz, ul. Kniaziewiczza 1/5, 91-347 Łódź, Poland, fax: +48 42 6539909, e-mail: kasprzak@ptkardio.pl

Conflict of interest: none declared

Kardiologia Polska Copyright © Polskie Towarzystwo Kardiologiczne 2017