

Early partial clip detachment following transcatheter mitral valve repair

Częściowe odłączenie zapinki po zabiegu przezskórnej korekcji niedomykalności mitralnej

Adam Rdzanek, Arkadiusz Pietrasik, Piotr Ścisło, Janusz Kochman, Grzegorz Opolski

1st Chair and Department of Cardiology, Medical University of Warsaw, Warsaw, Poland

A 71-year-old man with a history of dyspnoea in New York Heart Association functional class III, due to heart failure and severe mitral regurgitation, was admitted to hospital for the treatment of valvular heart disease. The patient, diagnosed with type 2 diabetes in the past, had undergone two coronary artery bypass surgeries (in 1998 and 2014), the latter complicated by periprocedural myocardial infarction. Heart failure, which developed subsequently, led to the implantation of a cardioverter-defibrillator. Transthoracic echocardiography (TTE) confirmed impairment of left ventricular function (LVDD 66 mm; EF 26%) and the presence of severe functional mitral regurgitation (ERO 0.42 cm², MRvol 51 mL). In a transoesophageal echocardiography (TEE) examination, the patient was found to be amendable for the percutaneous mitral valve repair. Due to the high risk of open heart surgery (EUROSCORE II 12.82%), the patient was scheduled for MitraClip implantation. The procedure was carried out successfully. A single MitraClip device was implanted in the area of the largest regurgitation jet. It led to a significant reduction of mitral insufficiency (Fig. 1A, B). The following hospitalisation was uneventful. However, on the third day after the procedure, in a pre-discharge TTE followed by immediate TEE, loss of posterior leaflet insertion into the MitraClip device and the recurrence of severe mitral regurgitation was found (Fig. 2A). Moreover, three-dimensional TEE showed a small indentation in the posterior leaflet edge, indicating the area of possible device-related leaflet damage (Fig. 2B). Because of the asymptomatic course of the event, after careful consideration of therapeutic options, the patient was discharged home without further interventions. Clinical evaluation, as well as TTE examination, was planned for the following weeks. Partial clip detachment (PCD), a complication observed in 2–4.8% of MitraClip procedures, usually occurs within the first six months following the implantation. In most the cases, loss

of insertion involves posterior mitral valve leaflet. There are no specific guidelines regarding the treatment of this phenomenon. In a large European registry (ACCESS-EU), out of 27 patients in whom PCD was diagnosed, 11 underwent another clip implantation, most of them as a separate procedure. Pharmacological treatment was continued in 10 cases, whereas only six patients were referred for open heart surgery. However, repeat MitraClip therapy is associated with a significantly lower success rate when compared to the first procedure (62% vs. 95%) and heart surgery requires valve replacement more often than annuloplasty. On the other hand, clip embolisation, a potentially life threatening complication, is a very rare phenomenon, and most of the registries do not report such cases following PCD. Taking that into consideration, in our opinion, further pharmacological treatment and a watchful-waiting strategy remains a possible therapeutic option in clinically stable high-risk patients with diagnosed PCD following MitraClip implantation.

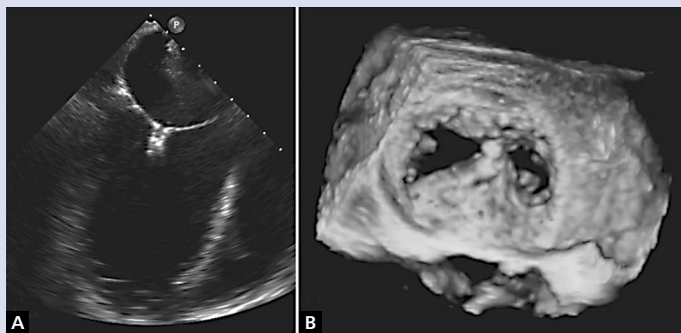


Figure 1. A, B. Peri-procedural echocardiographic assessment of MitraClip implantation

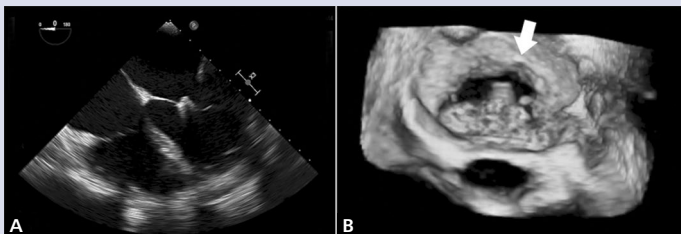


Figure 2. A, B. Partial clip detachment observed three days after the procedure. Arrow indicates the area of possible leaflet damage

Address for correspondence:

Adam Rdzanek, MD, PhD, 1st Chair and Department of Cardiology, Medical University of Warsaw, ul. Banacha 1a, 02-097 Warszawa, Poland, e-mail: ardzanek@poczta.wp.pl

Conflict of interest: none declared

Kardiologia Polska Copyright © Polskie Towarzystwo Kardiologiczne 2017