

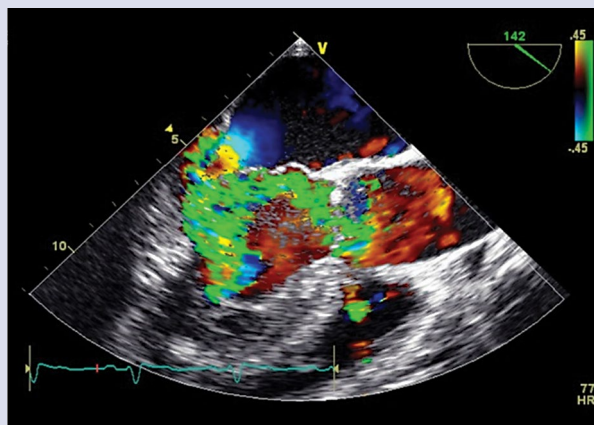
# A loud tear — acute aortic regurgitation with an unusual presentation

Głośny szmer powstały na tle rzadkiej przyczyny ostrej niedomykalności zastawki aortalnej

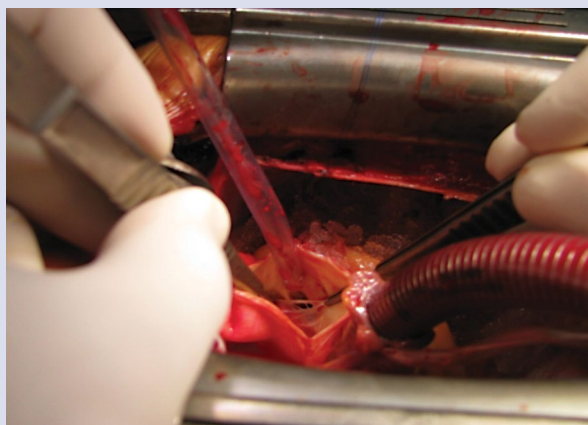
Kevin Domingues, Maria João Vieira, Beatriz Saldanha Santos, Isabel Monteiro, Margarida Leal

Cardiology Department, Hospital Distrital de Santarém, Santarém, Portugal

A 38-year-old man, with no relevant medical history, was admitted to the Emergency Room complaining of a murmur coming from his chest, which was first heard three days before, at night. He also felt more tired than usual, but denied dyspnoea, chest pain, or fever. A few days earlier he had fallen from an utility pole, although he managed to grasp a rope before hitting the ground. On admission, he was calm, haemodynamically stable, and his temperature was normal. The physical examination revealed a grade VI/VI diastolic murmur, discrete pulmonary rales and no peripheral oedema. In transthoracic echocardiogram the presence of a vibratile and filamentous image on the aortic valve and severe aortic regurgitation were noted. His left ventricle (LV) end-diastolic diameter was within normal limits, and he had preserved LV systolic function. A transoesophageal echocardiogram was performed, showing a flail right coronary cusp, with diastolic prolapse into the LV outflow tract and major regurgitation (Fig. 1). There was no elevation of inflammatory markers, serial blood cultures were negative, and a contrast-enhanced chest computed tomography scan revealed a normal aorta. The patient remained haemodynamically stable. He was transferred to a cardiac surgery centre and was submitted to surgery three days after hospital admission. There were multiple fenestrations on the aortic cusps and the right coronary cusp was ruptured and not amenable to repair (Fig. 2). The valve was replaced by a mechanical prosthesis. In the postoperative period he had minor complications only, and the patient was discharged home 12 days after his initial admission. This case represents an unusual presentation of a rare cause of acute valvular disease. Acute aortic regurgitation is usually a consequence of endocarditis, aortic dissection, rupture of a sinus of Valsalva aneurysm, or trauma. Aortic valve cusp fenestrations are commonly noted at pathology examination and during surgery, and according to small studies there is a higher prevalence in men. They may be congenital or an acquired degenerative change associated with age or with chronic hypertension, but their pathophysiology is not fully understood. Fenestrations are characteristically located between the line of closure and the free edge of the cusp, but they may extend from the region of the commissures to the nodule of Arantius. They are not usually associated with regurgitation because they are normally found distal to the line of closure. In this case, we assume the reported accident caused a rupture of one of the fenestrations, which extended beyond the line of closure or was unusually placed at the commissure, leading to a surprisingly well tolerated acute severe regurgitation. Acute aortic regurgitation is better tolerated in younger patients but, if untreated, is associated with significant morbidity and mortality. Surgery should not be delayed in this context. Intraoperative pathologic examination provides an insight into the mechanisms of this unusual disease.



**Figure 1.** Transoesophageal echocardiogram; flail right coronary cusp, with diastolic prolapse into the left ventricular outflow tract, and with major regurgitation



**Figure 2.** Intraoperative view; multiple fenestrations on the aortic cusps and ruptured right coronary cusp

**Address for correspondence:**

Dr. Kevin Domingues, Cardiology Department, Hospital Distrital de Santarém, Avenida Bernardo Santareno, 2005-177 Santarém, Portugal, e-mail: kev.domingues@gmail.com

**Conflict of interest:** none declared

Kardiologia Polska Copyright © Polskie Towarzystwo Kardiologiczne 2017