

Three-dimensional printing technology supports surgery planning in patients with complex congenital heart defects

Technologia wydruku 3D pomaga w planowaniu zabiegów operacyjnych u dzieci z wrodzonymi wadami serca

Radosław Jaworski¹, Ireneusz Haponiuk¹, Maciej Chojnicki¹, Henryk Olszewski², Paweł Lulewicz³

¹Department of Paediatric Cardiac Surgery, Mikolaj Kopernik Hospital, Gdansk, Poland

²The State University of Applied Sciences in Elblag, The Krzysztof Brzeski Institute of Applied Informatics, Elblag, Poland

³Elblag Technology Park, Elblag, Poland

Modern imaging makes it possible to print almost all organs before comprehensive surgical procedure planning with the use of advanced three-dimensional (3D) printing technology. This technique is gaining much wider acceptance and becomes far more common than it was a few years ago. 3D printing is also known as additive manufacturing, which means advanced processes used to synthesise a 3D object in which successive layers of selected tissues and structures are formed under computer control. The final print is possible with the use of many kinds of materials such as polymers and metal. 3D printing has been used previously in medicine to print patient-specific implants and devices for medical use, e.g. titanium pelvis or plastic tracheal splint. In cardiac surgery this technique is helpful in planning of complex surgical procedures. Here we report a six-month-old boy weighting 5.6 kg with pulmonary atresia and ventricular septal defect — with severe clinical manifestation such as complete agenesis of the pulmonary trunk, as well as the absence of the both right and left pulmonary arteries. The patient was admitted to our department after postnatal diagnosis, for further staged treatment. As a new-born, after initial catheterisation the child was as unifocalised with Gore-tex® 3.5 mm shunts from the ascending aorta to remnants of underdeveloped pulmonary arteries located in pulmonary tissue, bilaterally. Due to left-sided shunt hypoperfusion a re-do operation after seven days was necessary with additional Blalock-Taussig shunt. After half a year we performed contrast computed tomography (CT) to find out all options for reconstruction of the right ventricular outflow track (Fig. 1). Because of known limitations of standard two-dimensional CT, and the need to demonstrate anatomical structures while preparing for surgery, due to the complexity of the described case we made our attempts to try 3D printing techniques for pre-surgical decision-making. The CT data were routinely segmented and processed using software, and then converted into a stereolithography file (Fig. 2). Using Pixel Based Segmentation based on the thresholding method, an interval of grayscale values was used to describe the external surface of the anatomical structures. The reconstruction algorithm uses Delaunay triangulation and the sculpture process. Then a model of heart was printed in Elblag Technology Park with an Object30 Printer using liquid polymers (acryl) (Fig. 3). The patient was referred for further treatment, catheter intervention, and finally for surgical treatment. The case shows that 3D printed anatomic models allow all members of the multi-disciplinary team to plan the appropriate treatment approach, prepare for the surgery, and determine potential pitfalls and difficulties. 3D printing techniques used in children with congenital heart defects provide a valuable insight into children's condition also for their parents, allowing them to be fully involved in the proposed treatment options.

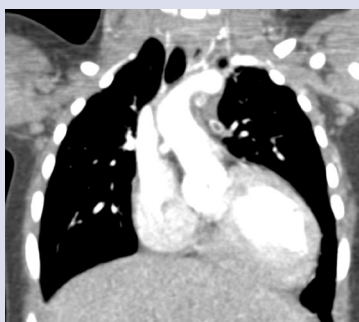

Figure 1. Computed tomography scan of described patient with pulmonary atresia and ventricular septal defect

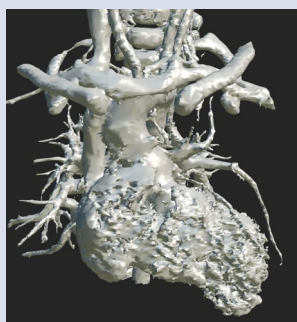


Figure 2. Three-dimensional model converted to stereolithography file just before printing

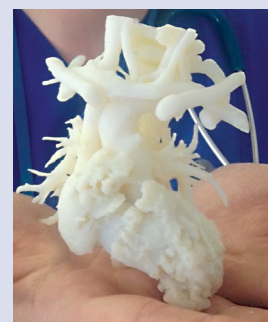

Figure 3. Three-dimensional printed model of the heart and pulmonary vessels with complete agenesis of pulmonary artery bed

Address for correspondence:

Radosław Jaworski, MD, PhD, Department of Paediatric Cardiac Surgery, Mikolaj Kopernik Hospital, ul. Nowe Ogrody 1-6, 80-210 Gdańsk, Poland, e-mail: radicis@go2.pl

Conflict of interest: none declared

Kardiologia Polska Copyright © Polskie Towarzystwo Kardiologiczne 2017