

A 51-year-old patient with carcinoid heart disease and severe tricuspid regurgitation

51-letnia pacjentka z rakowiakową chorobą serca i ciężką niedomykalnością trójdzielną

Elżbieta Florczak¹, Mariola Pęczkowska¹, Marek Konka², Jacek Różański³, Agnieszka Kolasińska-Ćwikła⁴

¹Department of Hypertension, Institute of Cardiology, Warsaw, Poland

²Department of Congenital Cardiac Defects, Institute of Cardiology, Warsaw, Poland

³Department of Cardiosurgery and Transplantology, Institute of Cardiology, Warsaw, Poland

⁴Department of Oncology, Maria Skłodowska-Curie Memorial Cancer Centre, Institute of Oncology, Warsaw, Poland

Neuroendocrine neoplasms (NENs), previously known as carcinoid tumours, are rare malignancies, occurring mainly in the gastrointestinal tract (67.5%). NENs may secrete many vasoactive substances, the most prominent being serotonin, which plays a key role in the development of carcinoid syndrome (CS) and consequently of carcinoid heart disease (CHD). Symptoms usually occur when hepatic metastases are present and release hormones that exceed the hepatic capacity for degradation. Approximately 50% of patients with CS develop CHD, which is characterised by fibrosis of the right heart and its valves. This leads to severe tricuspid (IT), pulmonary (IP) insufficiency, and consequently right heart failure. Echocardiography and magnetic resonance imaging (MRI) are the approved methods established for assessment of the severity of CHD as well as the degree of IT and IP. Somatostatin analogues are used in CS patients to reduce serotonin release and to alleviate the CS symptoms, but it is not always effective. For patients with stable carcinoid tumour, who develop a severe IT and progressive severe right heart failure, cardiac surgery should be considered. Herein we present the case of a 51-year-old female patient with a history of carcinoid tumour of the ileum with metastasis to the liver, who had previously undergone hemicolectomy presented with five-month history of progressive right ventricular failure. From the time of diagnosis, treatment with somatostatin analogues was implemented. Clinical examination revealed cachexia, dyspnoea, cyanosis, and severe lower-extremity oedema. A transthoracic echocardiogram revealed a significantly enlarged right ventricle to 5.4 cm. The retracted, shortened tricuspid leaflets displayed restricted mobility and poor coaptation. Severe tricuspid regurgitation was apparent upon colour-flow Doppler echocardiographic analysis (Fig. 1A, B). The pulmonary valve had moderate regurgitation. An MRI of the heart confirmed restriction of the leaflets of the tricuspid valve and its high-grade insufficiency, with huge enlargement of right atrium (Fig. 1C). The pulmonary valve insufficiency was low. The decision on the type of prosthesis is complex and should be individually tailored based on the individual patient risk of bleeding, the specific tumour-related life expectancy, and possible future therapeutic interventions. In that context, biological prosthesis of the tricuspid valve was chosen. In the perioperative setting, continuous somatostatin analogue (octreotide) infusion is of utmost importance to prevent carcinoid crisis. Then, 2 h prior to surgery an intravenous infusion of octreotide bolus at a dose of 50 µg was implemented, followed by 50 µg/h of continuous infusion for over 48 h after operation. Intraoperatively, a retraction of all three leaflets of the tricuspid valve with a complete lack of coaptation was found. A biological prosthesis, Medtronic Hancock II 31 mm, was implanted. A control echocardiography on day 15 after surgery showed a significant reduction in the size of the right ventricle to approximately 3.0 cm, and normal function of the implanted tricuspid valve (Fig. 1D). We further observed a significant clinical improvement of the patient, both with dyspnoea and peripheral oedema. The patient was discharged home on day 19 after surgery.

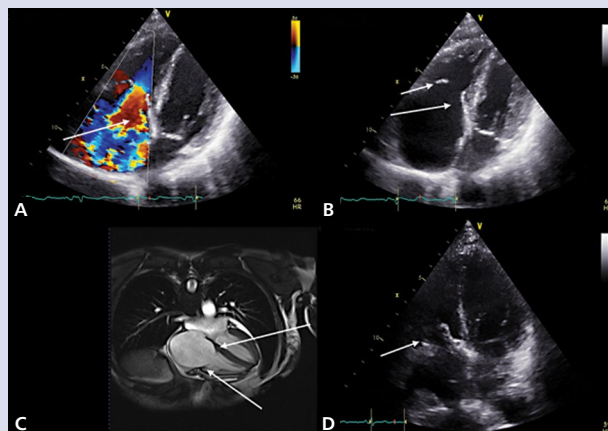


Figure 1. Severe tricuspid regurgitation in carcinoid heart disease before and after cardiosurgery; **A.** Transthoracic echocardiography (TTE), modified four-chamber view: arrow—huge tricuspid regurgitation; **B.** TTE, four-chamber view: arrows — fibrosis and calcification of tricuspid valve leaflets; **C.** Cardiac magnetic resonance imaging: arrows — poor coaptation of the leaflets of the tricuspid valve, and its high-grade insufficiency with huge enlargement of the right atrium; **D.** TTE after surgery, four-chamber view: arrow — bioprosthesis in tricuspid position

Address for correspondence:

Elżbieta Florczak, MD, PhD, Department of Hypertension, Institute of Cardiology, ul. Alpejska 42, 04-628 Warszawa, Poland, e-mail: florczakel@wp.pl

Acknowledgments: We would like to thank Prof. A. Januszewicz for his important suggestions during diagnostic and therapeutic steps, Dr. M. Śpiewak for consultation of MRI investigation, and Dr. E. Sitkowska-Rysiak for her involvement in intraoperative management of the patient.

Conflict of interest: none declared

Kardiologia Polska Copyright © Polskie Towarzystwo Kardiologiczne 2017