

First report of transcatheter closure of a ruptured sinus of Valsalva aneurysm using the Nit-Occlud Lê VSD Occluder

Pierwsze przezcewnikowe zamknięcie pękniętego tętniaka zatoki Valsalwy okluderem Nit-Occlud Lê VSD

Robert Sabiniewicz¹, Lidia Woźniak¹, Piotr Potaż¹, Maksymilian Mielczarek², Dariusz Ciećwierz²

¹Department of Paediatric Cardiology and Congenital Heart Diseases, Medical University of Gdansk, Gdansk, Poland

²1st Department of Cardiology, Medical University of Gdansk, Gdansk, Poland

A 46-year-old male with a history of arterial hypertension and obesity was referred to our hospital due to symptoms of congestive heart failure (NYHA class III). Physical examination revealed a diastolic heart murmur. Transthoracic echocardiogram showed a fistula from the right aortic sinus to the right ventricle. Invasive angiography visualised a ruptured sinus of Valsalva aneurysm (SVA) (Fig. 1). The defect measured 6 mm in diameter at the aorta. The patient was qualified for transcatheter closure of the SVA. Occlusion of the SVA was performed using a 12 × 16 mm Nit-Occlud Lê VSD Occluder (Pfm Medical) under local anaesthesia. The procedure was conducted under transoesophageal echocardiography guidance. The device was delivered from the venous side after the formation of an arteriovenous loop (Fig. 2). The procedure and further hospitalisation was uneventful. The patient experienced gradual symptom reduction, and an echocardiography performed after three months did not reveal a residual shunt. SVAs constitute rare cardiac anomalies, which can be of congenital or acquired origin. Commonly they involve the right coronary sinus (70%) and the non-coronary sinus (29%). Congenital SVAs are caused by weakness at the junction between the aortic media and the aortic ring. Acquired aneurysms are caused by conditions affecting the aortic wall, such as endocarditis, trauma, or connective tissue disease. Unruptured SVAs usually remain asymptomatic. In most cases rupture occurs at the age of 20–40 years. Usually SVAs rupture into the right ventricle and the right atrium, or less frequently into the pulmonary artery, left ventricle, left atrium, or pericardial cavity. This most commonly manifests as exercise intolerance, dyspnoea, or chest pain. Surgery is considered the gold standard treatment for SVA. However, percutaneous closure appears to be a feasible alternative to surgical repair. The first transcatheter closure of SVA was reported in 1994. Since then, a significant number of such procedures have been performed using various devices, most commonly patent ductus arteriosus occluders or atrial septal defects occluders. We chose the Nit-Occlud Lê VSD Occluder, which was originally designed for ventricular septal defect (VSD) closure (Fig. 3). The implant is constructed of a single coil. The coil is made of nitinol, an alloy with shape memory characteristics, and in its relaxed state it adopts the form of a pair of cones nested one inside the other. This implant is distinguished by a gentle and refined structure, which minimises its interference with neighbouring tissues. This is substantiated by the lower rate of atrio-ventricular conduction disturbances after VSD closure with the Nit-Occlud Lê VSD Occluder in comparison with other devices (0% vs. 5–7%, respectively). We believe that the above-mentioned occluder should be considered for transcatheter SVA closure. Of note, to the best of our knowledge this is the first closure of an SVA with a Nit-Occlud Lê VSD device.

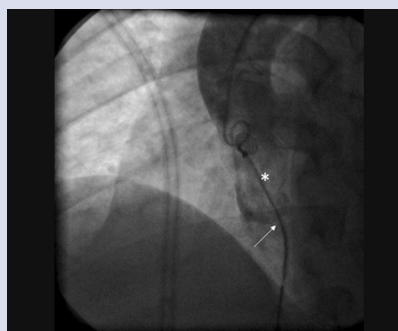


Figure 1. Aortography during positioning of the device. Sinus of Valsalva aneurysm (asterisk) and catheter introduced through the site of rupture (arrow)

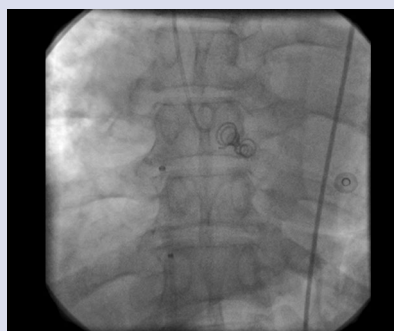


Figure 2. Released occluder




Figure 3. Occluder Nit-Occlud Lê VSD (Pfm Medical)

Address for correspondence:

Lidia Woźniak, MD, Department of Paediatric Cardiology and Congenital Heart Diseases, Medical University of Gdansk, ul. Dębinki 7, 80–211 Gdańsk, Poland, e-mail: lidiawozniak@yahoo.com

Conflict of interest: none declared

Kardiologia Polska Copyright © Polskie Towarzystwo Kardiologiczne 2017