

# Restenosis of the sole patent internal carotid artery

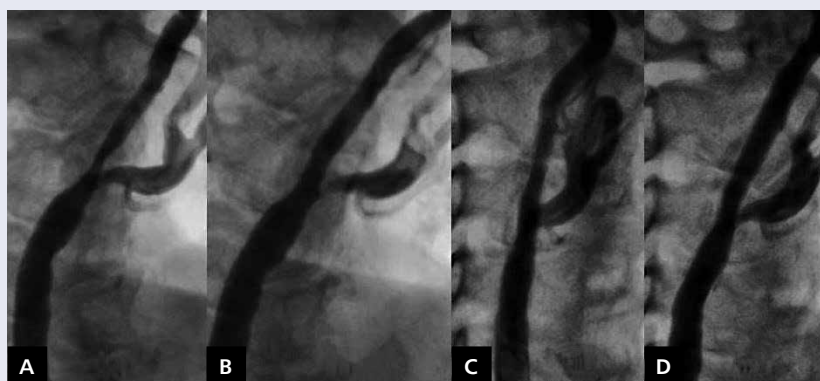
Restenoza w jedynej drożnej szyjnej tętnicy wewnętrznej

Jarosław D. Skowroński<sup>1</sup>, Paweł Tyczyński<sup>1</sup>, Mirosław Janowski<sup>2</sup>, Zbigniew Chmielak<sup>1</sup>, Adam Witkowski<sup>1</sup>

<sup>1</sup>Department of Interventional Cardiology and Angiology, Institute of Cardiology, Warsaw, Poland

<sup>2</sup>Institute for Cell Engineering, Johns Hopkins University School of Medicine, Baltimore, United States

The prevalence of unilateral, common carotid artery (CCA) occlusion in symptomatic patients is around 3%. Contralateral significant stenosis is observed in more than 50% of patients with CCA occlusion. Previous randomised trials suggested that endarterectomy leads to better results than carotid artery stenting (CAS). However, this was questioned with the long-term results of the CREST trial. The incidence of in-stent restenosis (ISR) after CAS is 3–17% and re-CAS is preferred. In case of ISR of the sole patent CCA, the treatment choice is unclear. A 73-year-old male with chronic left CCA occlusion, previous stenting of significantly calcified lesion in the right CCA and internal carotid artery (ICA) (Fig. 1A) two years ago, was admitted due to ICA-ISR. Cardiovascular risk factors included arterial hypertension and impaired glucose tolerance. Generalised atherosclerosis required previous angioplasties of coronary diagonal branch, right and left superficial femoral arteries, and left popliteal artery. Neurological examination revealed memory loss, anisocoria L>R, dropping of the left mouth corner, slight deviation of tongue to left, muscle weakness of left upper limb with sensory impairment, and dysdiadochokinaesia. Carotid ultrasound after first stenting of the right CCA and ICA was satisfactory — peak systolic velocity (PSV): 110 cm/s. Two years later PSV increased to 180 cm/s (corresponding to 70% stenosis). Cerebral computed tomography showed disseminated leukaraiosis and cerebellar atrophy. Re-do percutaneous angioplasty of the right ICA was chosen. Right femoral artery was punctured with 7 F sheath and the right CCA was cannulated with a 5 F JR3.5 guiding catheter then replaced over Amplatz 260 cm extra stiff wire with a 7 F 90 cm sheath. Carotid angiography showed 70% stenosis in the upper segment of the previously implanted stent to the right ICA and just above it (Fig. 1B–D). 5000 IU of heparin was administered. After inserting a FilterWire EZ™ neuroprotective system (Boston Scientific, MA, USA), subsequent lesion predilatation with 4.5 mm and 5.0 mm balloons at 17 atm was done. Due to suboptimal balloon angioplasty self-expanding a 7.0 × 20 mm XACT stent (Abbott Vascular, IL, USA) was implanted across the ISR and above it. Despite postdilatation with a 5.0 mm balloon at 17 atm, residual 10% stenosis was observed (Fig. 1D), without peri-procedural or in-hospital complications. PSV measured 120 cm/s. Few reports are available about the treatment outcome of recurrent stenosis in the sole patent ICA. ICA-ISR develops by neointimal proliferation. However, stent recoil is also a possible mechanism of recurrent stenosis. The presence of calcifications and fibrotic lesions are more likely to lead to stent recoil. Data about optimal treatment of stenosis in the sole patent ICA suggest that endarterectomy is associated with high rates of mortality and morbidity compared to CAS. Although there is a lack of evidence that cerebral protection devices enhance CAS safety, they are widely used. Neointimal tissue differs from friable atherosclerotic plaque. Thus, we speculate that the risk of distal embolisation might be lower during re-CAS. In this case a distal protection filter was selected instead of a proximal device because of chronic closure of contralateral CCA. Multiple stent placement is an independent predictor of ISR treatment of the sole patent ICA and requires clinical vigilance at follow-up. If re-intervention is required, individual treatment choice is most reasonable. At four months follow up neither adverse events nor ultrasound signs of re-ISR were observed.



**Figure 1.** Angiography; **A.** Critical ostial stenosis of the internal carotid artery; **B.** Result after stent implantation; **C.** Diffuse restenosis; **D.** Result after re-angioplasty

**Address for correspondence:**

Jarosław D. Skowroński, MD, Department of Interventional Cardiology and Angiology, Institute of Cardiology, ul. Alpejska 42, 04-628 Warszawa, Poland, e-mail: jskowronski@ikard.pl

**Conflict of interest:** none declared

Kardiologia Polska Copyright © Polskie Towarzystwo Kardiologiczne 2016