

# Optical coherence tomography imaging during endovascular treatment of a patient with Takayasu arteritis

Optyczna koherentna tomografia w obrazowaniu przezskórnego leczenia pacjenta z chorobą Takayasu

Maciej Lewandowski, Małgorzata Peregud-Pogorzelska, Paweł Stachowiak, Marek Brzosko, Zdzisława Kornacewicz-Jach

Takayasu disease (TA) is an inflammation of the large arteries arising from the aortic arch, and sometimes the abdominal aorta. The basis for the treatment of TA is systemic therapy together with symptomatic treatment involving operational or endovascular treatment. Indications are interpolated from recommendations on treatment of atherosclerosis. However, these recommendations should be approached with caution. Thus, the use of modern methods to diagnose and monitor treatment of these changes are of particular interest. Optical coherence tomography (OCT) allows detailed analysis of the inner layers of the wall and atherosclerotic plaque, and it has been performed safely for acute coronary syndrome. In the diagnosis and treatment of peripheral vascular diseases, this technique is less commonly used. We present the case of a 55-year-old woman diagnosed with TA for 2 years, accompanied by shoulder pain, upper limb weakness and numbness, and fatigue. The patient was administered systemic treatment by a rheumatologist. Imaging tests showed severe narrowing in the right subclavian and axillary arteries and the proximal segment of the brachial artery, and left subclavian artery occlusion with well-developed collateral circulation. Considering the clinical indications and patient's preferences, endovascular treatment was planned. Angiography revealed sequential, multiple stenoses (Fig. 1A). OCT showed increased intima-media thickness (IMT) without atherosclerotic plaques (Fig. 1B). Angioplasty was performed with a drug-eluting balloon (DEB) to achieve a good angiographic result (Fig. 2A). OCT confirmed a significant increase in the lumen with dissection over the whole area of IMT (Fig. 2B). Due to the absence of peripheral flow impairment, the treatment was terminated and symptoms almost completely resolved. After several months of observation, the symptoms gradually reappeared and aggravated. Angiography revealed persistent dissection in the previously affected area where the balloon was deployed. A self-expanding paclitaxel-eluting stent (PES) was implanted, which resulted in regression of the symptoms. During subsequent clinical monitoring, the patient again complained of gradually worsening symptoms of limb ischaemia. On follow-up angiography, a diffuse in-stent restenosis (ISR) was noted (Fig. 3A). This time, OCT showed typical ISR (Fig. 3B). The narrowing was expanded with a balloon. Currently, the patient is under clinical observation, and the findings have been unremarkable for the 7 months since the last procedure. The report describes a typical clinical picture of TA. Herein, typical endovascular treatment was performed, which has been shown to be effective for atherosclerosis, especially in the lower limbs, with the use of drug (paclitaxel)-eluting balloons. However, in our case, both the DEB and PES proved to be ineffective. Analysis of OCT images can help determine why a treatment is ineffective. In the present case, OCT revealed chronic non-healing dissection. Compared to images obtained for atherosclerotic lesions, the images for TA show dissection covering the entire thickened complex intima-media and no healing tendency, which is commonly seen in atherosclerotic lesions. Surgery (subclavian-brachial bypass graft) may be effective, but as an invasive technique, it is considered a last resort in cases of failure of endovascular treatment. Moreover, intense anti-inflammatory therapy may enhance healing of the vessel after percutaneous transluminal angioplasty. This problem requires further investigation.

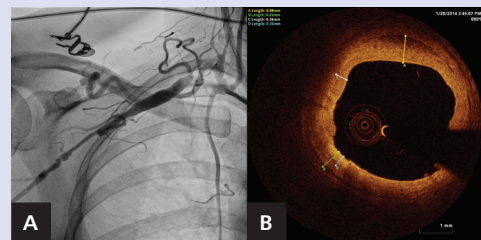


Figure 1. A. Angiography showing sequential, multiple stenosis; B. Optical coherence tomography of the intima-media thickness

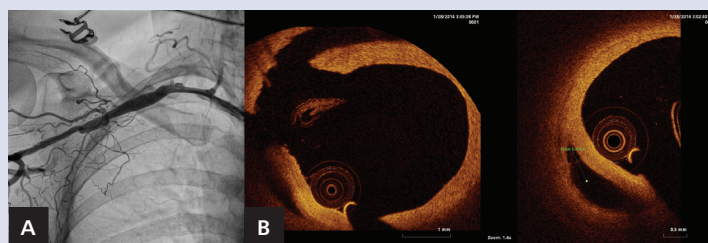


Figure 2. A. Angiography findings after intervention with the drug-eluting balloon (DEB); B. Dissection is observed over the whole area of intima-media thickness after intervention with the DEB

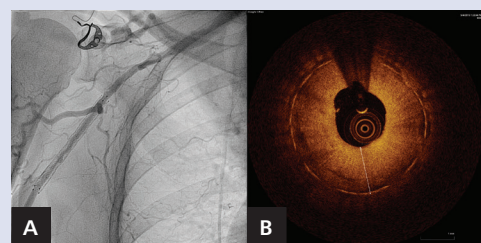


Figure 3. A. A large diffuse in-stent restenosis was noted; B. Optical coherence tomography showing the large diffuse in-stent restenosis

#### Address for correspondence:

Paweł Stachowiak, MD, Department of Cardiology, Pomeranian Medical University, al. Powstańców Wielkopolskich 72, 70-111 Szczecin, Poland, tel: +48 607669786, fax: +48 91 4661379, e-mail: stachowiak22@gmail.com

**Conflict of interest:** none declared

Kardiologia Polska Copyright © Polskie Towarzystwo Kardiologiczne 2016