

Abdominal pain: diagnostic issues in patient with coexisting Takayasu's arteritis and ulcerative colitis

Ból brzucha: problemy diagnostyczne u chorego ze współistniejącym zapaleniem tętnic Takayasu i wrzodziejącym zapaleniem jelita grubego

Joanna Kosalka¹, Katarzyna Wawrzycka-Adamczyk¹, Anna Włodarczyk¹, Beata Machalica², Wojciech Sydor¹

¹2nd Department of Internal Medicine, Jagiellonian University Medical College, Krakow, Poland

²Division of Radiology, 2nd Department of Internal Medicine, Jagiellonian University Medical College, Krakow, Poland

The occurrence of Takayasu's arteritis (TA) in patients with ulcerative colitis (UC) has been previously reported rarely, with only about 50 cases in the world, and more than half of these cases have been identified in Japan. To our knowledge, this is the first case of the co-existence of such diseases reported in Poland. A 23-year-old woman diagnosed with UC in 2007 was hospitalised in 2014 in the Department of Internal Medicine of the Jagiellonian University Medical College in Krakow due to abdominal pain, the presence of claudication of the left upper limb, diplopia, and recurrent headaches. In previous medical history the patient had undergone angioplastic surgery due to critical stenosis of the renal artery. Physical examination revealed lack of pulse in the left upper extremity and 60 mm Hg difference in systolic blood pressure between arms. The laboratory tests showed leucocytosis ($11.39 \times 10^3/\mu\text{L}$), microcytic anaemia (haemoglobin 11.7 g/dL; MCV 77.3 fL, ferrum 7.1 $\mu\text{mol/L}$, TIBC 60.4 $\mu\text{mol/L}$), hypoalbuminaemia (29 g/L), slightly elevated lactate dehydrogenase (668 U/L), decreased glomerular filtration rate estimated by Cockcroft-Gault (79 mL/min), and an increased level of C-reactive protein (CRP; 25.4 mg/L). The presence of atypical anti-neutrophil cytoplasmic antibodies in low titre (1:20) and lack of antinuclear antibodies were confirmed in immunological tests. Lupus anticoagulant, anticardiolipin IgG antibodies, and anti- β -2-glycoprotein IgG antibodies were negative. The patient was also negative for HLA-B27, rapid plasma reagin, human immunodeficiency virus, and hepatitis B and hepatitis

C viruses. Computed tomography (CT) angiography indicated occlusion of the left common carotid artery and proximal part of the left vertebral artery (Fig. 1), critical stenosis of the left subclavian artery (Fig. 2), significant narrowing of the celiac trunk and the superior mesenteric artery, as well as critical stenosis of the proximal right renal artery (Fig. 3). Stents in both branches of left renal artery were patent. Echocardiogram showed thickening of the walls of the left ventricle, and left ventricular ejection fraction was 52%. The TA was confirmed and a treatment was initiated with methylprednisolone (five doses 250 mg/day, then 1 mg/kg/day) and methotrexate (20 mg/week). Positron emission tomography (PET/CT with 18F-FDG) did not reveal active lesions (vasculitis) in the course of TA. An ultrasound examination after three months of pharmacotherapy showed no further narrowing of the carotid,

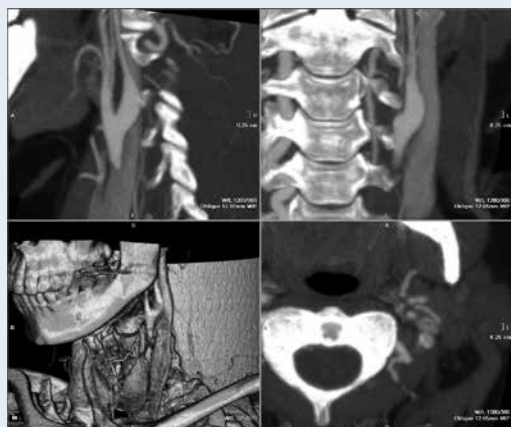


Figure 1. Occlusion of the left common carotid artery and of the left vertebral artery — reverse flow of radiocontrast visible



Figure 2. Critical stenosis of the left subclavian artery — residual flow visible

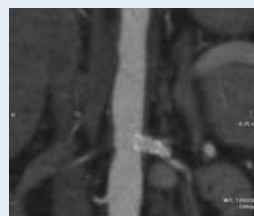

Figure 3. Critical stenosis of the right renal artery and stents in both branches of the left renal artery (upper branch 4 mm, lower branch 2 mm; both fully patent)

vertebral, or subclavian arteries. On the basis of CRP (8.2 g/L) and imaging tests the dose of methylprednisolone was reduced. We did not confirm the presence of HLA-B52, which in several reports is more prevalent in patients with UC/TA and is associated with worse outcomes. Although the coexistence of TA and UC is rare, it should be taken into consideration by cardiologists during diagnosis and treatment of patients; moreover, PET/CT would probably be useful for the evaluation of the disease activity and distinguishing between vasculitic and inflammatory bowel disease-related changes in gastrointestinal tract.

Address for correspondence:

Anna Włodarczyk, MD, Department of Internal Medicine, Jagiellonian University Medical College, ul. Skawińska 8, 31-066 Kraków, Poland, e-mail: anna.wlodarczyk@uj.edu.pl

Conflict of interest: none declared

Kardiologia Polska Copyright © Polskie Towarzystwo Kardiologiczne 2016