

Ruptured plaque in the left main coronary artery. A benign phenomenon?

Pęknięta blaszka w pniu lewej tętnicy wieńcowej

Aleksandra Brutkiewicz¹, Maciej Dąbrowski¹, Paweł Tyczyński¹, Rafał Wolny¹, Nicolas Foin², Adam Witkowski¹

¹Institute of Cardiology, Warsaw, Poland

²National Heart Centre Singapore, Singapore

Intravascular ultrasound (IVUS) allows precise determination of left main coronary artery (LMCA) stenosis. However, in some lesions not only stenosis is of significance, but also the plaque complexity. We present a patient with no-flow limiting LMCA complex lesion. The 51-year-old patient was referred to elucidate the LMCA lesion. His previous history included conservatively treated acute coronary syndrome (ACS) of the inferior wall (several years ago). His first coronary angiography revealed patent right coronary artery (RCA) and non-significant, however angiographically complex plaque in the mid-distal LMCA segment (Fig. 1A, B, 2A). The second ACS due to acute RCA occlusion was treated with bare metal stent implantation to RCA (Fig. 1C, D). Control angiography performed four months later revealed proximally occluded RCA and still present complex LMCA lesion (Fig. 1E, F). IVUS showed eccentric plaque with an empty cavity within the plaque communicating with the lumen and the cavity maximal area of 3.5 mm². The LMCA cross-section area at this point was 11 mm² (Fig. 2B–D). Additionally, the angle between the maximum plaque cavity and the left circumflex artery take-off was nearly 180 degrees. Both the RCA occlusion and the complex LMCA lesions were left without interventional treatment. The patient underwent platelet reactivity testing, which did not show any clopidogrel resistance. Pharmacological treatment included dual antiplatelet therapy (DAPT) consisting of aspirin and clopidogrel. During 14 months of follow-up the patient did not experience any adverse cardiovascular event. One may hypothesize that the counter-flow rupture of the plaque (RP) can cause more blood stream turbulences (as in this case), thus promoting thrombus formation, than no-counter-flow rupture. However, there is no evidence for prophylactic rupture sealing by stent implantation (especially as this patient experienced previous RCA stent occlusion). A previous case series suggested that conservative treatment of no-flow limiting lesions with the RP feature is relatively safe. In the study by Rioufol et al. [Circulation, 2004; 110: 2875–2880] half of the 28 RPs had healed at 22 ± 13 months IVUS follow-up. Interestingly, no RP-related factors promoting the healing process were identified. Nonetheless, some issues should be raised. First, the RP cavity in this study was much smaller than in our patient, and the RP cavity even in the non-healed RPs group decreased (from 1.8 mm² to 0.2 mm²). We did not have baseline IVUS in our patient. The angiographic appearance of the RP cavity, however, did not seem to diminish over the period of seven months (Fig. 1B, F). Secondly, this and other reports did not include patients with RP confined only to LMCA, but also in non-LMCA epicardial arteries. Thirdly, in some RP cases, DAPT may not be enough to prevent thrombus formation and acute artery

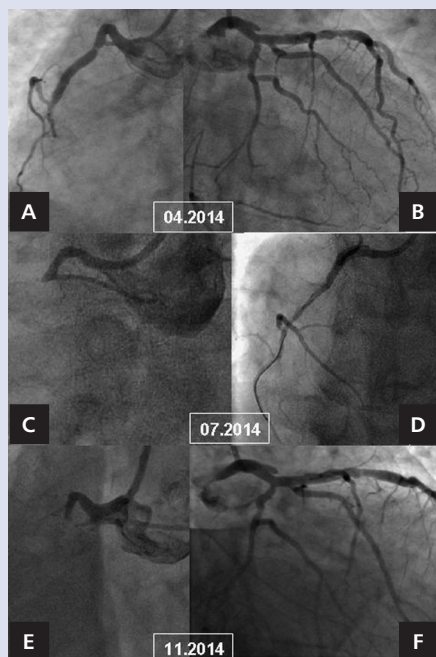


Figure 1. Chronologically presented coronary angiographies. **A.** Patent right coronary artery (RCA); **B.** Complex left main coronary artery (LMCA) plaque; **C.** Acute RCA occlusion; **D.** Opened RCA with stent implantation; **E.** Chronically occluded RCA; **F.** Unchanged LMCA plaque

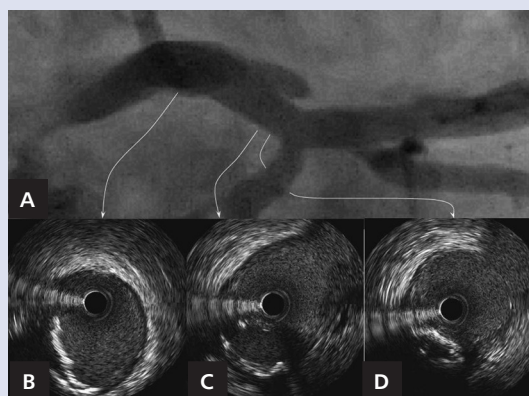


Figure 2. **A.** Magnification of left main coronary artery; **B–D.** Corresponding intravascular ultrasound cross-sections with ruptured plaque cavity — seven o'clock (**C**)

occlusion. Finally, total LMCA occlusion is potentially catastrophic, especially when (as in our case) no circulatory support from the very proximally occluded RCA exist. Thus, optimal pharmacological treatment, including the length of DAPT and its composition (aspirin plus clopidogrel or more potent antiplatelet drugs), remains unclear.

Address for correspondence:

Paweł Tyczyński, MD, PhD, Department of Interventional Cardiology and Angiology, Institute of Cardiology, ul. Alpejska 42, 04-628 Warszawa, Poland, e-mail: medykp@wp.pl

Conflict of interest: none declared

Kardiologia Polska Copyright © Polskie Towarzystwo Kardiologiczne 2016