

Atypical location of granulomatosis with polyangiitis (Wegener's) with heart involvement — effectiveness of treatment with rituximab

Nietypowe występowanie ziarniniakowatości z zapaleniem naczyń (Wegenera) z zajęciem serca — skuteczność leczenia rituximabem

Dorota Sikorska¹, Andrzej Tykarski², Artur Radziemski², Ewa Mojs³, Włodzimierz Samborski¹

¹Department of Rheumatology and Rehabilitation, Poznan University of Medical Sciences, Poznan, Poland

²Department of Hypertension, Angiology, and Internal Diseases, Poznan University of Medical Sciences, Poznan, Poland

³Department of Psychology, Poznan University of Medical Sciences, Poznan, Poland

A patient at the age of 52 years, with a diagnosis of granulomatosis with polyangiitis, was admitted to the Department of Rheumatology and Rehabilitation due to disease progression. The first symptoms of the disease occurred 3 years earlier. Initially, recurrent otitis media were seen. The patient was subsequently treated in the Department of Otolaryngology. On the basis of clinical symptoms, the results of additional tests, and histopathological examination, granulomatosis with polyangiitis was diagnosed. In the process of treatment the following were used: methylprednisolone (500 mg IV pulses), prednisone (max. 50 mg/day), cyclophosphamide (600 mg IV pulses), and azathioprine (75 mg/day). Despite the treatment, disease progression was observed, as follows: central nervous system involvement with accompanying depression and cardiac involvement. Echocardiography revealed discrete hypokinesia and heterogeneous echogenicity of intraventricular septum. Magnetic resonance imaging (MRI) confirmed oval change of heart in the pericardium, infiltrating the right ventricular outflow tract, and pulmonary trunk, with dimensions of 32 × 30 × 17 mm (Fig. 1A, B). The results of laboratory tests found high levels of antibodies cANCA (79.0 RU/mL) and the presence of inflammation (ESR = 48 mm/h, CRP = 11.6 mg/L). Due to the high activity of the disease with cardiac involvement, immunosuppressive therapy was intensified — applied pulses of cyclophosphamide (600 mg IV) and glucocorticosteroids (methylprednisolone 1000 mg IV). In spite of the treatment remission was not obtained. After 2 months, in a control cardiac MRI a persistent mass (28 × 27 × 13 mm) was found in the pericardium. Therefore, it was decided to apply a biological treatment. After obtaining the approval of the Bioethics Committee of the Medical University in Poznan the patient received a total rituximab dose of 2.0 g in four divided administrations (500 mg) at 7-day intervals, while continuing treatment with glucocorticosteroids (prednisone 50 mg/day). Following the treatment achieved clinical improvement and normalisation of laboratory results (negative cANCA and absence of inflammatory markers). In the control MRI a reduction of the mass in the pericardium to the dimensions of 18 × 8 × 16 mm was observed. Another 6 months after treatment with rituximab a total reduction of the mass in the heart was observed. This case confirms that granulomatosis with polyangiitis is a systemic disease with a broad spectrum of organ involved and indicates the effectiveness of treatment with rituximab.

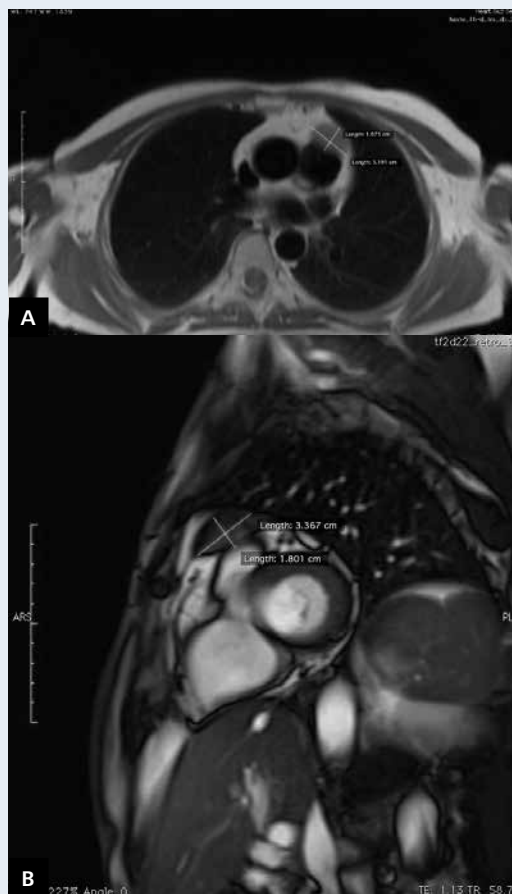


Figure 1. A, B. Magnetic resonance: an oval change in the pericardium, infiltrating the right ventricular outflow tract and pulmonary trunk

Address for correspondence:

Artur Radziemski, MD, PhD, Department of Hypertension, Angiology and Internal Diseases, Poznan University of Medical Sciences, ul. Długa 1/2, 61-848 Poznań, Poland, e-mail: a_radziemski@o2.pl

Conflict of interest: none declared