

# An asymptomatic giant thoracoabdominal aortic aneurysm

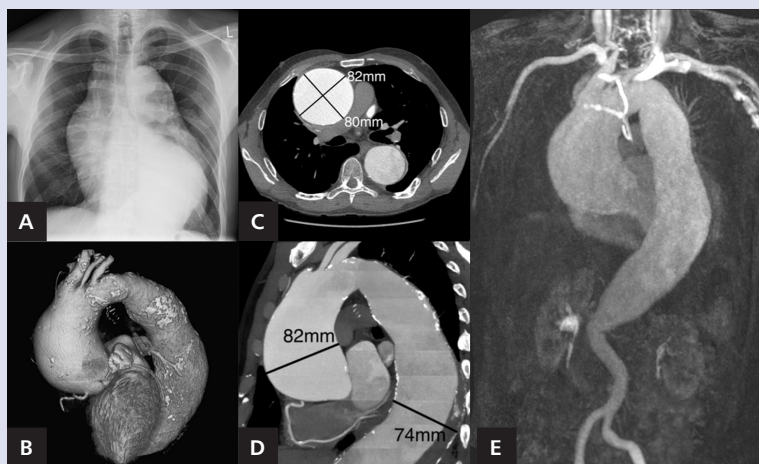
Olbrzymi bezobjawowy tętniak aorty piersiowo-brzuszej

Marta Kałużna-Oleksy<sup>1</sup>, Bartosz Żabicki<sup>2</sup>, Ewa Straburzyńska-Migaj<sup>1</sup>, Stefan Grajek<sup>1</sup>

<sup>1</sup>1<sup>st</sup> Department of Cardiology, Medical University, Poznan, Poland

<sup>2</sup>Department of Radiology, Medical University, Poznan, Poland

Giant ascending and descending aorta aneurysm with coexistent abdominal aorta aneurysm in a non-Marfan patient is a very rare condition; however, huge ascending aorta aneurysms, alone or with concomitant aortic arch enlargement, are frequently reported in literature. The occurrence of chest pain is one of the most common symptoms accompanying thoracic aorta aneurysm, so the complete absence of the patient's symptoms in such a large aortic pathology is interesting for physicians involved in the management of elderly patients with aortic aneurysms. A 52-year-old man was admitted to our hospital due to casual disclosure of a giant aneurysm of ascending, descending, and abdominal aorta for further evaluation. Thoracic aortic aneurysm was suspected at the chest X-ray, performed due to scheduled orthopaedic surgery. Imaging revealed suggestive enlargement of the mediastinum (Fig. 1A). Besides a diagnosis of epilepsy since childhood the patient was generally asymptomatic. He had no family history of connective tissue diseases and no signs of Marfan syndrome. Blood inflammatory parameters, antinuclear and antineutrophil cytoplasmic antibodies, as well as syphilis tests (VDRL) were negative. The trans-thoracic echocardiography showed enlargement of left ventricle (67 mm), hypertrophy of posterior wall (13 mm) and interventricular septum (12 mm), and an ascending aortic aneurysm with severe aortic regurgitation with backflow in the descending aorta and preserved ejection fraction of 55%. Computed tomography angiography (CTA) confirmed an aneurysm of ascending aorta maximally 82 mm in diameter (Fig. 1B, C). The thoracic aorta reduced stepwise in size and reached 30 mm in the aortic arch. The descending aorta was also enlarged to 74 mm in diameter with an eccentric thrombus in its lumen (Fig. 1D). Additionally performed magnetic resonance angiography showed the spread of the aneurysm into the suprarenal part of the abdominal aorta (Fig. 1E). Moreover, in CTA of coronary arteries aneurysmal enlargement of proximal part of left anterior descending artery was found at the level of the first diagonal branch (10 × 6 mm). The patient did not consent to invasive treatment. Although ascending aortic aneurysm is a frequent entity, the size and range of aortic pathology in our patient make such a case rare. Furthermore, the natural history of untreated aortic aneurysm indicates very high incidence of death because of rupture or dissection, and the size of the aneurysm is the most important predictor. However, the benefit-risk ratio of surgical treatment requires thorough evaluation.



**Figure 1.** **A.** Chest X-ray showing conspicuous widening of the mediastinum; **B.** Volume-rendered computed tomography angiography (CTA) of the aorta; **C.** CTA showing a huge ascending aortic aneurysm; **D.** CTA showing an enlargement of descending aorta to 74 mm in diameter with eccentric thrombus in the lumen; **E.** Additionally performed magnetic resonance angiography showing the spreading of the aneurysm into the suprarenal part of the abdominal aorta

**Address for correspondence:**

Marta Kałużna-Oleksy, MD, PhD, 1<sup>st</sup> Department of Cardiology, Medical University, ul. Długa 1/2, 61-848 Poznań, Poland, e-mail: marta.kaluzna@wp.pl

**Conflict of interest:** none declared