

Left ventricular assist as a key factor for heart self-restoration in a 20-year-old patient with severe left ventricular dysfunction: five-year echocardiographic observation

20-letni pacjent z ostrą niewydolnością lewej komory z zastosowaniem wspomaganie lewokomorowego jako sposobu na trwałą autoregenerację serca: 5-letnia obserwacja echokardiograficzna

Anetta Kowalczyk-Wieteska, Jerzy Pacholewicz, Michał Zakliczyński, Anna Barańska-Kosakowska, Marian Zembala

Department of Transplantation and Cardiac Surgery, Silesian Centre for Heart Diseases in Zabrze, Zabrze, Poland

A 20-year-old male patient was admitted to the hospital in a life-threatening condition, haemodynamically unstable, with symptoms of low output syndrome. An intra-aortic balloon pump was introduced together with inotropic support for more than two weeks without any clinical improvement. Left ventricular ejection fraction (LVEF) was 10–15%, left ventricular end-diastolic diameter (LVEDD) was 6.9 cm, and left ventricular end-diastolic volume (LVEDV) was 220 mL. Based on the above-mentioned symptoms and findings, acute, toxic, severely dilated cardiomyopathy was diagnosed. Despite maximum medical therapy no improvement was observed; therefore the patient was qualified for heart support using the Polish Cardiac Assist (POLCAS) system. On 01.08.2007 POLCAS was successfully implanted as a left ventricular (LV) support together with concomitant tricuspid valve annuloplasty. LV global and regional function was assessed twice weekly by transthoracic echocardiography. After four months of treatment LVEF was 25% and LVEDV was 150 mL, and the LV assist device was switch off. In ergospirometry the maximum oxygen consumption (VO_2) was 22.8 mL/kg/min with a limit pulse of 157/min, and blood pressure 100/65 mmHg. The test repeated after 14 days showing that VO_2 max had improved to 25.9 mL/kg/min. After five months of LV support, due to significant improvement of the patient's cardiac efficiency including myocardial contractility with increase of LVEF +35% and significant reduction of LVEDV 140 mL, LVEDD 5.5 cm, a decision to explant the Polish Ventricular Assist Device (POLVAD) was taken (Figs. 1, 2). Pharmacological treatment and rehabilitation were continued, and the patient's cardiac competence was regained. The patient was discharged from the hospital in NYHA I class, with LVEF 40%. Six months later LVEF increased to 50%, and LVEDV and LVEDD were on the same level. During five years of observation, twice a year, LVEF, LVEDV, and LVEDD did not change.

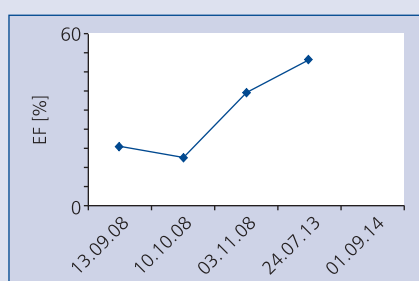


Figure 1. Echocardiographic presentation of ejection fraction (EF%) during and after mechanical device

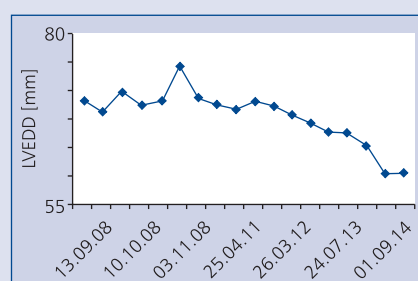


Figure 2. Echocardiographic presentation of left ventricular end-diastolic diameter (LVEDD) during and after mechanical device

Address for correspondence:

Anetta Kowalczyk-Wieteska, MD, PhD, Silesian Centre for Heart Diseases, ul. M. Curie-Skłodowskiej 9, 41-800 Zabrze, Poland, e-mail: kowaletta@onet.eu

Conflict of interest: none declared