

# Combined total aortic arch replacement associated with aortic valve replacement and subtotal thyroidectomy

Jednoczesny zabieg wymiany łuku aorty, wymiany zastawki aortalnej i strumektomii

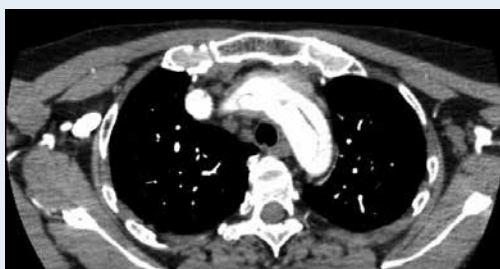Piotr Stepiński<sup>1</sup>, Tomasz Stankowski<sup>1</sup>, Sleiman Sebastian Aboul-Hassan<sup>1</sup>, Maciej Pęksa<sup>1</sup>, Romuald Cichoń<sup>2</sup>

<sup>1</sup>MEDINET Heart Centre Ltd., Nowa Sol, Poland

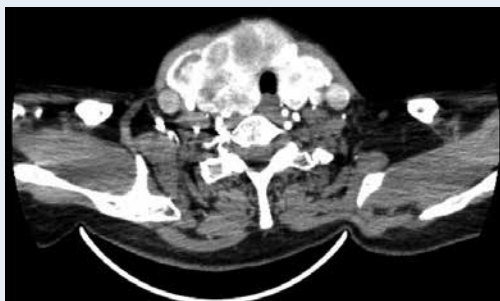
<sup>2</sup>Department of Cardiac Surgery, Medical University of Warsaw, Warsaw, Poland

The aim of this study is to present a 57-year-old female patient in whom a combined total aortic arch replacement associated with aortic valve replacement and subtotal thyroidectomy was simultaneously performed. The patient was admitted to the Department of Neurology due to isolated seizure of the right upper limb, with progression of the paresis. The symptoms resolved after a few hours. Seven months earlier, the patient suffered from a haemorrhagic stroke in the right hemisphere due to an aneurysm of the distal branch of the callosomarginal artery. The pathology was then treated by embolisation of the aneurysm. During current hospitalisation, diagnostic tests showed goitre, paroxysmal atrial fibrillation, and aortic valve insufficiency. Computed tomography angiography confirmed aortic dissection — Stanford type A, with dissected aortic arch, brachiocephalic trunk, both common carotid arteries, and the left subclavian artery (Figs. 1, 2). After completed diagnostics, the patient was transferred to the Department of Cardiac Surgery for immediate operation. It was decided to perform a combined aortic valve replacement with total aortic arch replacement and subtotal thyroidectomy. Longitudinal skin incisions on the neck were performed to expose both carotid arteries. Median sternotomy was performed. Brachiocephalic trunk and the right atrium were cannulated. Extracorporeal circulation (ECC) was established and the patient was cooled to 28°C. The aorta was clamped, aortotomy was performed, and Calafiore blood cardioplegia was introduced into the coronary ostia. Aortic valve was replaced using a 21-mm bioprosthesis. Proximal anastomosis with a four-branched graft to the ascending aorta was performed. The selective antegrade cerebral perfusion started, and under circulatory arrest the distal part of the graft was anastomosed with the descending aorta above the left subclavian artery, also using a felt strip and Bio-Glue (Fig. 3). Circulation was restored through the graft. The four-branched graft was anastomosed with both common carotid arteries and the right subclavian artery. Due to dissection of the right internal carotid artery, the vessel was separately reconstructed. During reperfusion and rewarming, a subtotal thyroidectomy was performed (Fig. 4). The surgery

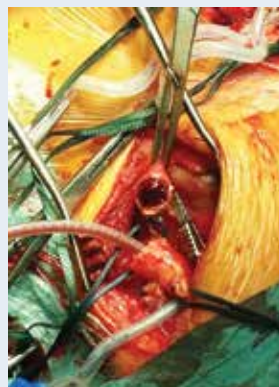took 7 h 10 min, ECC-time was 3 h 22 min, aortic cross clamp time was 1 h 57 min, and circulatory arrest time was 30 min. The postoperative period passed uneventfully. The patient, in a haemodynamically and respiratorily stable state, was discharged 12 days after the surgery to the Department of Cardiology for further rehabilitation. The simultaneous surgical procedures can be safely done after meticulous preparation and diagnostics as well as good constipated surgery sequence. It has to be stated, however, that it requires an individual approach in an environment of an experienced surgical team.



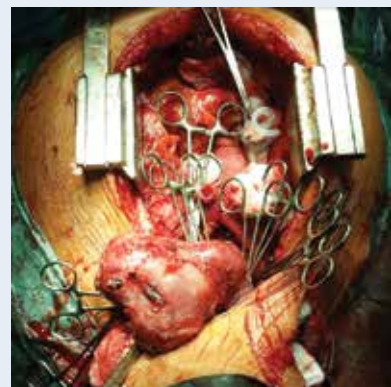
**Figure 1.** Preoperative chest computed tomography scan. Aortic dissection — Stanford type A



**Figure 2.** Preoperative neck computed tomography scan. Goitre and both common carotid dissection



**Figure 3.** Carotid artery cannulation



**Figure 4.** Subtotal thyroidectomy

**Address for correspondence:**

Tomasz Stankowski, MD, MEDINET Heart Centre Ltd., ul. Chałubińskiego 7, 67-100 Nowa Sól, Poland, e-mail: tomekstankowski89@gmail.com

**Conflict of interest:** none declared