

Application of optical coherence tomography of subclavian and axillary arteries in a patient with Takayasu's arteritis

Zastosowanie optycznej koherentnej tomografii w tętnicy podobojczykowej i pachowej u pacjentki z chorobą Takayasu

Paweł Stachowiak, Marcin Milchert, Maciej Lewandowski, Zdzisława Kornacewicz-Jach, Jarosław Gorący

Department of Cardiology, Pomeranian Medical University, Szczecin, Poland

Takayasu's arteritis (TA) is large vessel vasculitis affecting the aorta and its major branches. The annual incidence of systemic vasculitis approaches 40 per million adults worldwide. TA can result in myocardial infarction (MI), and this should therefore be differentiated from arteriosclerotic lesions. Optical coherence tomography (OCT) is increasingly used to assess coronary stent implantation and vessel healing following stent implantation. So far, the use of OCT with Takayasu's disease has been described only once, and it was used for a left anterior descending coronary artery lesion. This is the first case report of the use of OCT with a TA patient providing peripheral arteritis. A 27-year-old woman with psoriasis and celiac disease was admitted to our hospital with typical chest pain. In the first electrocardiogram, ST-elevation in a VR lead and ST-depressions in the other leads were revealed. The patient reported night sweats and muscle weakness in the arms. Physical examination revealed blood pressure at 90/60 mm Hg and 80/50 mm Hg in the right and left arm, respectively. Pulse at both radial arteries was barely palpable. Murmurs above both subclavian arteries and both carotid arteries were heard with auscultation. Echocardiography revealed mild hypokinesis at the apex and septum segments. Serum troponin I and creatine kinase isoenzyme MB activity was elevated significantly to MI. Coronary angiography showed a 90% focal stenosis in the ostium of the left main coronary artery (LMCA) (Fig. 1A). Ticagrelor and acetylsalicylic acid were administered immediately. Afterwards the lesion was predilated with balloons and then a 4.0 × 8 mm drug eluting stent with everolimus was deployed with a good final result. Contrast-enhanced computed tomography (CT) of the aorta and its main branches revealed vessel wall thickening, together with left carotid and subclavian arteries stenosis. Corticosteroid and cyclophosphamide therapy was added to the treatment. After 3 months, the patient underwent angiography to check the stent in the LMCA and also a control angiography and OCT of both subclavian and axillary arteries. These revealed persistent stenosis in both subclavian and right axillary arteries (Fig. 1B, C) and no restenosis in LMCA. OCT revealed intima-media thickness up to 0.75 mm over long distance without atheromatous plaque (Fig. 2). Due to lack of a proper drug-eluting balloon (DEB) for the patient the procedure was postponed. After a few weeks information was received that the patient had died due to massive MI whilst in her home city. Histological lesions in large vessel arteritis involve all layers of the arterial wall: intimal hyperplasia, medial degeneration, adventitial fibrosis, and mononuclear cellular infiltration lead to lack of a clear intima-media border. TA is an inflammatory disease, so anti-inflammatory drugs can reduce the lesions. Therefore, in peripheral arteries, the deployment of a DEB rather than stent implantation should be considered. When a culprit lesion involves the LMCA treatment with only a DEB is not acceptable. Our report provides essential knowledge concerning how an artery can look in large vessel arteritis as opposed to arteriosclerosis. The images can provide rare but important knowledge concerning peripheral and coronary diseases.

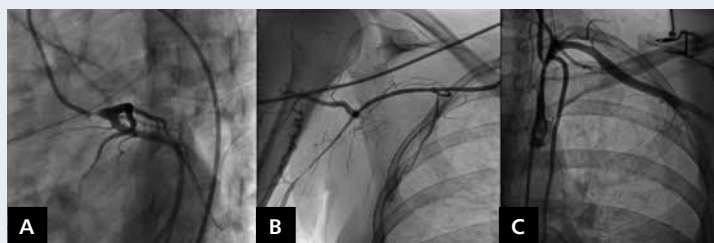


Figure 1. Angiography of left coronary artery (A), right subclavian and axillary artery (B), and left subclavian artery (C)

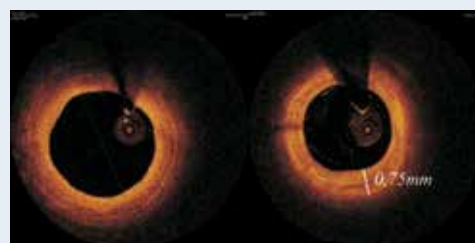


Figure 2. Optical coherence tomography of right subclavian and axillary artery

Address for correspondence:

Paweł Stachowiak, MD, Department of Cardiology, Pomeranian Medical University, al. Powstańców Wlkp. 72, 70-111 Szczecin, Poland, e-mail: stachowiak22@gmail.com

Conflict of interest: none declared