

# Mitral stenosis with giant left atrial thrombus obstructing pulmonary veins

Stenoza zastawki mitralnej z dużą skrzepliną w lewym przedsionku obturująca żyły płucne

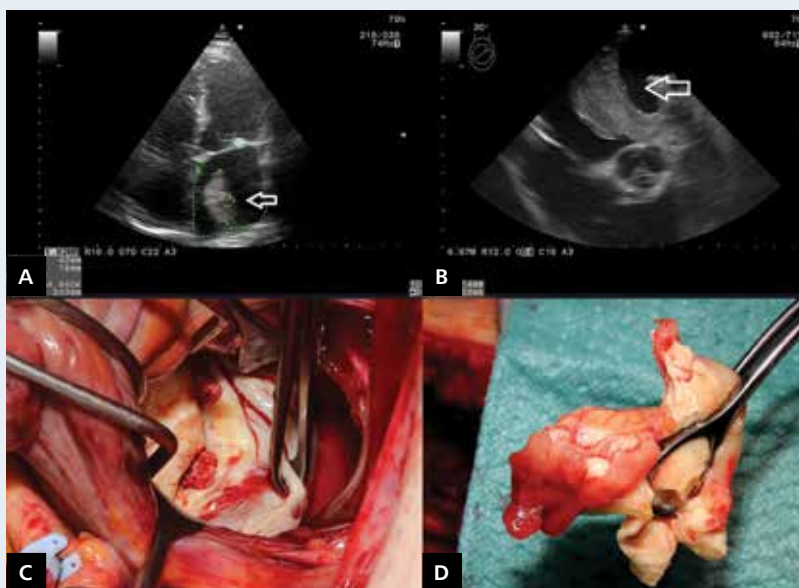
Piotr J. Stryjewski<sup>1</sup>, Agnieszka Kuczaj<sup>2</sup>, Łukasz Kulak<sup>1</sup>, Tomasz Myrdko<sup>3</sup>, Jacek Nowak<sup>1</sup>

<sup>1</sup>Cardiology Department, Chrzanow City Hospital, Poland

<sup>2</sup>2<sup>nd</sup> Department of Cardiology, Zabrze, Medical University of Silesia, Katowice, Poland

<sup>3</sup>Department of Cardiovascular Surgery and Transplantology, Institute of Cardiology, Medical School of Jagiellonian University, John Paul II Hospital, Krakow, Poland

A 64-year-old obese female patient with no previous cardiac history was admitted to hospital due to decreased exercise tolerance. The resting electrocardiography showed atrial fibrillation (AF). In transthoracic echocardiography, mitral valve stenosis (area 1.26 cm<sup>2</sup>) with a concomitant large tumour in the left atrium (LA) was visualised (Fig. 1A). The finding was confirmed by transoesophageal echocardiography — in the LA a large homogenous massive structure was detected. It was a strand-like structure, most probably an organised thrombus, originating from the left appendage extended (diameter 20–30 mm) to the LA, where it was adherent to the left atrial wall and the mitral valve apparatus. The structure partially blocked the mitral valve orifice, enhancing pre-existing mitral valve stenosis (Fig. 1B). Tumour excision with concomitant mitral valve replacement was planned. The patient was referred to the Department of Cardiovascular UJ CM. Surgery was performed using standard cardiopulmonary bypass with moderate hypothermia and antegrade blood cardioplegia. Cardiac surgical procedure confirmed the presence of a giant thrombus located in the whole left appendage and the majority of the LA body, partially obstructing pulmonary veins (Fig. 1C, D). The pathological mitral valve was excised and an artificial mitral valve Medtronic ATS (diameter 29 mm) was placed. The left atrial appendage was ligated. Microscopic examination confirmed a giant thrombus. Left atrial thrombus is one of the typical complications of mitral stenosis; however, the number of patients with mitral stenosis is nowadays very low. On the other hand, the obstructive character of the mass is a very rare feature. Risk factors for thrombus formation in the LA, besides the mitral stenosis, are AF and an enlarged LA. It is estimated that mitral stenosis increases the risk by 17% and the coexistence of mitral stenosis with AF doubles the risk. In this group of patients, the risk of stroke is significantly increased. Although the importance of anticoagulation in prevention of recurrence is obvious, cardiac surgery seems to be the only reasonable means of treatment due to the fact that thrombi extended into the left atrial body in patients with mitral stenosis and AF may persist despite optimal anticoagulation. In conclusion, surgical removal of the thrombus is the treatment of choice.



**Figure 1.** A. Echocardiographic four-chamber view presenting a large mass in the left atrium (arrow); B. Transoesophageal echocardiography of the left atrium at 114 degrees with a large wall adherent mass (arrow); C. Operative view after tumour resection; D. A thrombus removed from the left atrium

**Address for correspondence:**

Piotr Stryjewski, MD, PhD, Cardiology Department, Chrzanow City Hospital, ul. Topolowa 16, 32-500 Chrzanów, Poland, tel: +48 509 59 89 59, fax: +48 32 624 72 58, e-mail: pstryjewski@o2.pl

**Conflict of interest:** none declared