

Persistent left superior vena cava found during pacemaker replacement

Przetrwiała żyła główna górna lewa wykryta podczas wymiany stymulatora serca

Elżbieta Barbara Świętoń¹, Przemysław Stolarz², Marcin Grabowski², Roman Steckiewicz²

¹Department of Cardiology, Central University Hospital in Warsaw, Warsaw, Poland

²Department of Cardiology, Medical University of Warsaw, Warsaw, Poland

Disturbed embryological development of the venous system can result in the formation of a patent tube on the left side, in the form of persistent left superior vena cava (PLSVC). In the presented case, the anomaly was detected during a routine heart electrotherapy procedure, and its type, double superior vena cava (DSVC) connected through the patent left brachiocephalic vein (LBCV), was found in venography performed during pacemaker replacement. A woman, aged 90, was admitted to the clinic for planned pacemaker replacement after more than 10 years of normal functioning of a VVI system. Segmental 'frosting' of electrode isolation and fluid under the electrode were found during the procedure (06.02.2014). A decision was made to replace the electrode. The insertion method was to be conditional on the image of vessel patency after the administration of a contrast. The performed venography showed the presence of PLSVC (Fig. 1A, B). The patency of brachiocephalic vein (BCV) connected to right superior vena cava (RSVC) allowed the introduction of the new electrode in this way (Fig. 2A, B). PLSVC is found in about 0.3–0.5% of the population, and it is usually found by chance during invasive echocardiographic procedures or during post mortem examinations. PLSVC in the form of DSVC is found in about 85% of cases differentiated by the presence or lack of a connecting LBCV. RSVC agenesis is found in 10–15% of cases, in which the entire venous confluence to the right heart goes through the PLSVC due to RSVC obstruction. The anomaly is observed more often in cases of congenital heart defects (3–10%), e.g. joint atrioventricular canal, triatrial heart, and mitral valve atresia. In the majority of cases, PLSVC connects with the right atrium, and in the remaining cases it also connects with the left atrium. According to the available literature, the studied case is the first case in which identification occurred during a successive procedure related to constant heart stimulation. It can be concluded that DSVC with BCV anomalies of systemic veins might be more frequent than is stated in papers discussing heart electrotherapy procedures. The angle of departure of the BCV from the PLSVC favours the immediate introduction of electrodes to it and the omission of the PLSVC without imaging contrasted vessels.

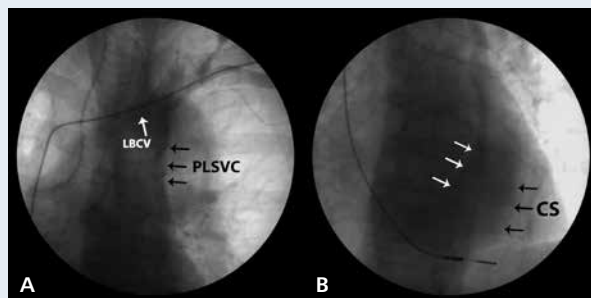


Figure 1. Venography showed (A) the patency of the axillary vein and the subclavian vein, and the persistent left superior vena cava (PLSVC) (arrows) discharged to the enlarged (B) coronary sinus (CS) (arrows); LBCV — left brachiocephalic vein

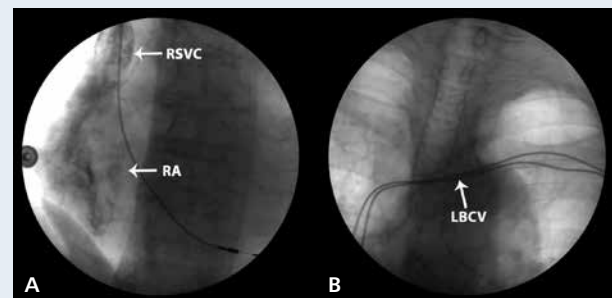


Figure 2. Contrast flow presenting right superior vena cava (RSVC) (arrow) and the right atrium (RA) (arrow; A), patent left brachiocephalic vein with the previous and the newly introduced electrode (arrow; B); LBCV — left brachiocephalic vein

Address for correspondence:

Elżbieta Barbara Świętoń, Msc, Department of Cardiology, Central University Hospital in Warsaw, ul. Banacha 1a, 02-097 Warszawa, Poland, e-mail: swieton@onet.pl

Conflict of interest: none declared