

A subcutaneous implantable cardioverter-defibrillator — the first implantation in Poland

Podskórny kardiowerter-defibrylator — pierwsza implantacja w Polsce

Krzysztof Kaczmarek¹, Radosław Zwoliński², Karol Bartczak², Paweł Ptaszyński¹, Jerzy Krzysztof Wranicz¹

¹Department of Electrocardiology, Medical University, Lodz, Poland

²Department of Cardiosurgery, Medical University, Lodz, Poland

We present the case of a 28-year-old patient successfully implanted with a subcutaneous implantable cardioverter-defibrillator (S-ICD) in secondary prevention of sudden cardiac death. The patient was resuscitated from out-of-hospital cardiac arrest due to ventricular fibrillation (VF). This was complicated by pneumothorax and respiratory failure that required mechanical ventilation for 5 days. After 2 weeks on the intensive care unit, the patient was transferred to the Cardiology Department. A subsequent medical evaluation revealed no structural heart abnormalities, nor other overt cardiovascular dysfunctions. However, during an invasive electrophysiological study, VF was induced with programmed right ventricular stimulation (Fig. 1). Therefore, the patient was implanted with an ICD. One week after this procedure, he presented symptoms of fever, shivers and chest pain. A fulminant endocarditis and right ventricle perforation was diagnosed. Subsequently, an adequate intravenous antibiotic treatment was introduced and the ICD system was explanted. Nevertheless, the important destruction of the tricuspid valve was revealed in echocardiography, and cardiothoracic surgery with artificial tricuspid valve replacement (Medtronic 29 mm) was performed. The surgery was complicated by intermittent complete atrio-ventricular block, thus the epicardial lead was implanted to the left ventricle and connected to the pacemaker placed in the right subclavian region. After 3 weeks of in-hospital recovery, the patient was consulted by an international board of arrhythmology specialists in order to establish the possibility of S-ICD implantation. The electrocardiography screening to check S-ICD arrhythmia discriminators matching with sensed cardiac signals was completed successfully, as well on the intrinsic rhythm as during pacing. Eventually, the patient was referred to S-ICD implantation. The procedure was performed on oral anticoagulation with acenocoumarol (INR on the day of procedure was 2.1), in volatile and maintenance anaesthesia by a joint team of cardiologist and cardiothoracic surgeon. The S-ICD was positioned in the left lateral region between the 5th and 7th intercostal spaces. The subcutaneous defibrillation lead was implanted atypically — in parasternal instead of medial line. The reason for atypical positioning of the lead was to avoid collision with the epicardial lead that had been previously implanted in the substernal region and to avert complications in case of future medial resternotomy. The position of the device and the lead is presented in Figure 2. Considering the high thromboembolic risk, testing of the defibrillator was successfully performed after transoesophageal echocardiography on the 4th day after the implantation. The post-procedure course was uneventful. We present the first Polish experience of implantation of a S-ICD system. This modern therapy is an option for those patients who cannot have a standard ICD implanted for any reason, e.g. vascular abnormalities or intravascular infection. This procedure, although it is still not routinely reimbursed by the public health system, has become a new treatment option for Polish patients.

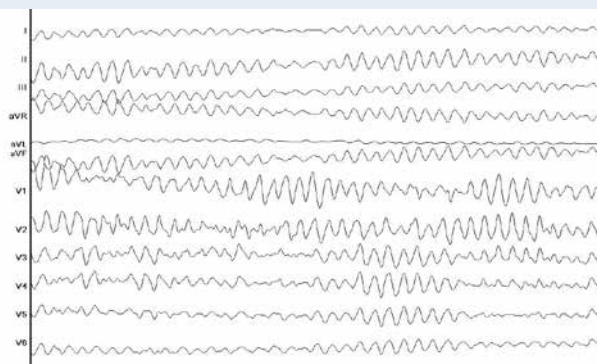


Figure 1. Ventricular fibrillation induced during invasive electrophysiological study

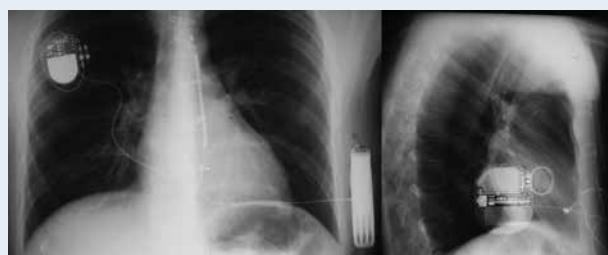


Figure 2. Chest X-ray of the patient with pacemaker connected to epicardial lead, artificial tricuspid valve and subcutaneous implantable cardioverter-defibrillator

Address for correspondence:

Krzysztof Kaczmarek, MD, PhD, Department of Electrocardiology, Medical University, ul. Sterlinga 1/3, 91-425 Łódź, Poland, tel/fax: +48 42 664 43 04, e-mail: medkrzych@yahoo.es

Conflict of interest: K. Kaczmarek — consultation fee from Boston Scientific Poland.

We would like to thank Prof. Ryszard Jaszewski, MD, PhD for his support in organising the first S-ICD implantation procedure.