

The use of an automated external defibrillator in a victim of car accident

Zastosowanie automatycznego defibrylatora zewnętrznego u osoby poszkodowanej w wypadku komunikacyjnym

Bartosz Puchalski^{1,2}, Marek Kwasiżur², Anna E. Płatek¹, Filip M. Szymański¹

¹1st Chair and Department of Cardiology, Medical University of Warsaw, Warsaw, Poland

²Volunteer Mountain Rescue Service, Subcarpathian Group, Sanok, Poland

Early identification of the emergency, early cardiopulmonary resuscitation (CPR), and early defibrillation are crucial for improving survival rates of out-of-hospital cardiac arrest. Various educational programmes and campaigns have been implemented to improve knowledge of basic life support techniques in the general public. Alongside education comes technological advances. Automated external defibrillators (AED) are now more widely available in public spaces including shopping malls, train stations, airports etc. Many paramedical organisations such as volunteer mountain rescue services or other uniformed services have their cars equipped with AED. Statistics show that an increasing number of bystanders, even without any medical training, are using AEDs in emergency settings, performing, in many cases successful, CPR. We report the case of a 37-year-old male who was hit by a car on a pedestrian crossing at dusk. Help was immediately introduced by bystanders, one of whom was a uniformed services officer whose vehicle was equipped with an AED. As a result of the accident, the victim suffered cardiac arrest. Witnesses immediately took steps of basic life support protocol (chest compressions and mouth-to-mouth ventilation), and used AED. The device correctly recognised a shockable rhythm (ventricular tachycardia) and issued appropriate voice commands. After charging the capacitor, the AED delivered energy of 120 J, after which the bystanders, according to the recommendations of the AED, immediately began indirect heart massage. AED-assisted CPR lasted for a total of 15 min, until paramedics arrived on the scene and introduced advanced life support.

Other recorded cardiac arrest rhythms showed that defibrillation should not be performed and finally resuscitation was unsuccessful, which was later shown to be due to multiorgan damage and massive blood loss. Fragments of electrocardiogram recorded by AED are shown in Figures 1 and 2. Guidelines of the European Resuscitation Council strongly stress the role of the 'Chain of Survival' in the management of cardiac arrest patients. The first three links in the Chain: recognition with a call for help, CPR, and defibrillation, are extremely time-sensitive. With every minute of delay, the chances of a favourable outcome drop dramatically. Early recognition and introduction of CPR by bystanders can be improved solely by the education of people, but the third link depends strongly on availability of defibrillator. Since their introduction in 1979, AEDs have slowly become part of the urban landscape. They have been shown to be extremely safe, with a close-to-zero rate of inappropriate intervention, and have dramatically improved survival rates when they are implemented early. The use of AED is reasonable in all cases of cardiac arrest including traumatic and non-traumatic reasons. In traffic accidents, victims' potential causes of cardiac arrest include cardiac combustion (for example by blunt trauma caused by the steering wheel), pulmonary oedema or blood loss. In many cases, these causes are potentially treatable and reversible, especially in young, otherwise healthy individuals. The present case, even though CPR was finally unsuccessful, illustrates that increasing the availability of AEDs in public spaces, and as in this case in uniformed services vehicles, is necessary and can potentially save lives.

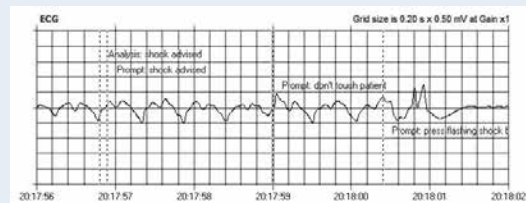


Figure 1. Automated external defibrillator-recorded ventricular tachycardia

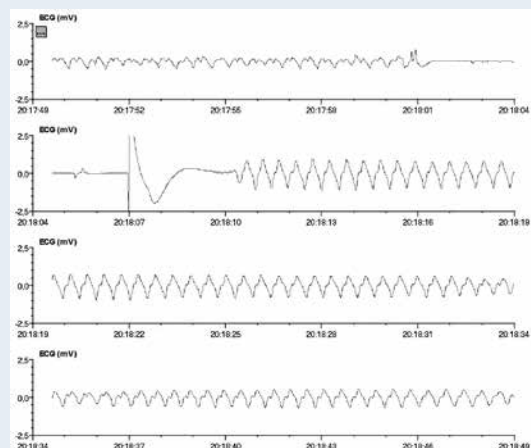


Figure 2. Ventricular tachycardia prior to discharge, with subsequent artefacts caused by chest compressions

Address for correspondence:

Bartosz Puchalski, MD, PhD, 1st Chair and Department of Cardiology, Medical University of Warsaw, ul. Banacha 1A, 02-097 Warszawa, Poland, e mail: bartosz-puchalski@wp.pl

Conflict of interest: none declared