

# Third generation balloon expandable valve implantation in a patient with severe aortic stenosis

Przezskórna implantacja zastawki trzeciej generacji rozprężalnej na balonie u pacjenta z ciężką stenozą aortalną

Paweł Kleczyński, Danuta Sorysz, Marek Tomala, Robert Sobczyński, Dariusz Dudek

Institute of Cardiology, Krakow, Poland

The patient was an 85-year-old female with severe symptomatic aortic stenosis and symptoms of chronic heart failure (class III according to the New York Heart Association functional classification). The presence of several comorbidities including arterial hypertension, severe chronic obstructive pulmonary disease requiring long-term use of bronchodilators and steroids, chronic kidney disease, atrial fibrillation and diabetes contributed to the logistic Euroscore I of 16%. The subject had undergone percutaneous coronary intervention (PCI) in left ascending artery (LAD) with drug eluting stent implantation one month earlier. An echocardiographic assessment revealed a left ventricular ejection fraction of 68%, tricuspid, calcified aortic valve with valvular gradient 70/44 mm Hg and aortic valve area of 0.8 cm<sup>2</sup>. In transoesophageal echocardiogram, the aortic annulus diameter was 24 mm. Coronary angiography did not show any significant atherosclerosis in coronary vessels, and a good result of PCI LAD. Computed tomography (CT)-angiography of iliac and lower limb arteries revealed diameters of right and left common femoral artery of 8 mm and 9 mm, respectively. The subject was discussed at a Heart Team meeting and scheduled for transcatheter aortic-valve implantation (TAVI) with a recommendation for femoral access and the use of a 26 mm Edwards Sapien 3 prosthesis (Edwards Lifesciences, Irvine, CA, USA). TAVI procedure was performed under general anaesthesia and under transoesophageal echocardiography control. A temporary pacemaker for rapid pacing was inserted via right subclavian vein access. A diagnostic 6 French pigtail catheter was introduced to the ascending aorta through the right radial artery for intraprocedural imaging purposes. Balloon aortic valvuloplasty was performed using a 20 × 40 mm balloon under pacing at 180 bpm. Afterwards, a successful implantation of a 26 mm Edwards-Sapien 3 valve (14 F delivery system) under pacing at 180 bpm was performed (Figs. 1, 2). The duration of the procedure was 100 min with 0.7 mGy of radiation. The post-procedural transthoracic echocardiogram showed a gradient of 16/7 mm Hg with no aortic regurgitation and no paravalvular leaks (Fig. 3). At 45 days follow-up, the patient remains asymptomatic with aortic gradient of 19/8 mm Hg and no aortic regurgitation.

Edwards Sapien 3 prosthesis is a novel device for TAVI procedures to improve results of valve implantation mainly by reducing the risk of paravalvular leaks due to a new design of valve prosthesis, inner and outer 'skirt'. Moreover, ultra-low delivery profile with 14 F could provide lower risk of vascular complications.

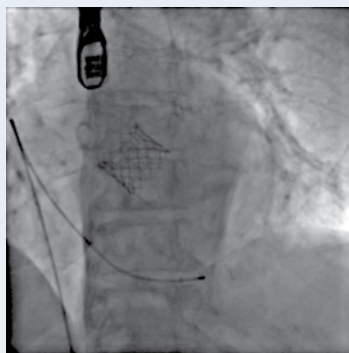


Figure 1. Edwards Sapien 3 after TAVI in fluoroscopy

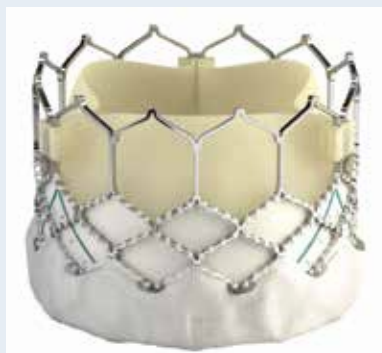

Figure 2. Edwards Sapien 3 valve with outer and inner skirt

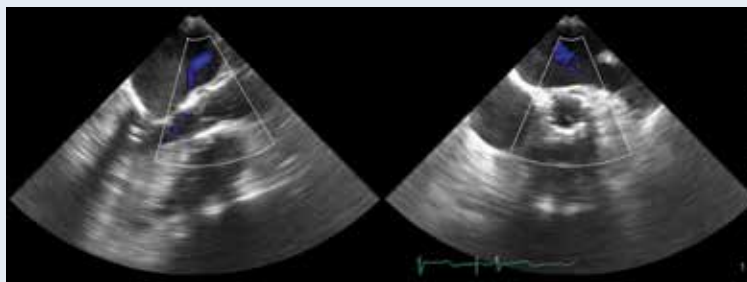


Figure 3. No aortic regurgitation and paravalvular leaks after TAVI

#### Address for correspondence:

Paweł Kleczyński, MD, PhD, 2<sup>nd</sup> Department of Cardiology and Cardiovascular Interventions, Jagiellonian University Medical College, ul. Kopernika 17, 31-501 Kraków, Poland, tel: +48 12 424 71 81, fax: +48 12 424 71 84, e-mail: kleczu@interia.pl

**Conflict of interest:** none declared