

# Alternating left and right bundle branch block

Naprzemienny blok prawej i lewej odnogi pęczka Hisa

Katarzyna Mitreęa, Radosław Lenarczyk, Patrycja Pruszkowska, Zbigniew Kalarus, Beata Średniawa

Department of Cardiology, Congenital Heart Diseases and Electrotherapy, Silesian Medical University, Silesian Centre of Heart Diseases, Zabrze, Poland

A 59-year-old white male was admitted to the hospital with complaints of chest pain, palpitations and weakness. He was a smoker with a significant family history of coronary artery disease (CAD). During the past few days, he had had a syncope. He was admitted to the hospital because of tachycardia with wide QRS syndrome to provide a coronary angiogram to exclude, or to confirm, acute coronary syndrome. His physical examination was unremarkable. Accelerated rhythm with left bundle branch block (LBBB) morphology and heart rate (HR) of 75 bpm was seen in the electrocardiogram (ECG) record (Fig. 1). In echocardiography, global hypokinesia with ejection fraction of 45% was noted. In coronary artery catheterisation, non pathological changes were seen. A few days after the coronary angiogram, in ECG record, atrio-ventricular (AV) dissociation, sinus rhythm (HR of 55 bpm) with right bundle branch block (RBBB), and slightly faster nodal rhythm (HR of 58 bpm), were observed (Fig. 2). We therefore carried out an electrophysiological study (EPS), where we observed nodal rhythm (HR of 60 bpm), rhythm induced from the region below AV node with LBBB (localised in the right bundle branch), and occasionally sinus rhythm without LBBB. The arrhythmia was not induced by programmed right atrial (RA) stimulation. During the continuous RA stimulation, faster than the accelerated rhythm, the correct AV conduction was observed. Therefore, the patient was qualified for pacemaker implantation. After DDD pacemaker implantation in the 24-hour digital Holter records, sinus rhythm, AAI or DDD stimulation, and occasionally accelerated nodal or ventricular rhythm were observed. During a half year observation, the patient remained asymptomatic. Alternating bundle branch block (ABBB) is a very rare situation in clinical practice. There are many potential causes of ABBB e.g.: CAD, adrenergic stimulation, degenerative processes or the migration of impulse origin. Some authors have stated that ABBB constitutes about 6% of all bundle branch blocks. The greatest danger in patients with ABBB is the potential risk of complete heart block. This is why treatment is focused on pacemaker implantation. Although the above-mentioned patient had no AV disorders (e.g. AV block), there was a possibility of complete heart block appearing during syncope episodes. This case report shows the importance of an appropriate ECG evaluation, its monitoring and further diagnostic process e.g. EPS, especially in symptomatic patients. It is important to remember that ECG recordings may stimulate ABBBs, which should be analysed very closely because of their unique clinical relevance.

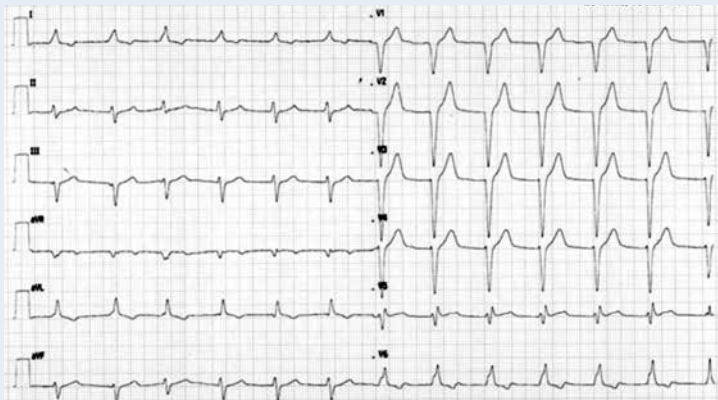


Figure 1. Accelerated rhythm with LBBB morphology and HR of 75 bpm

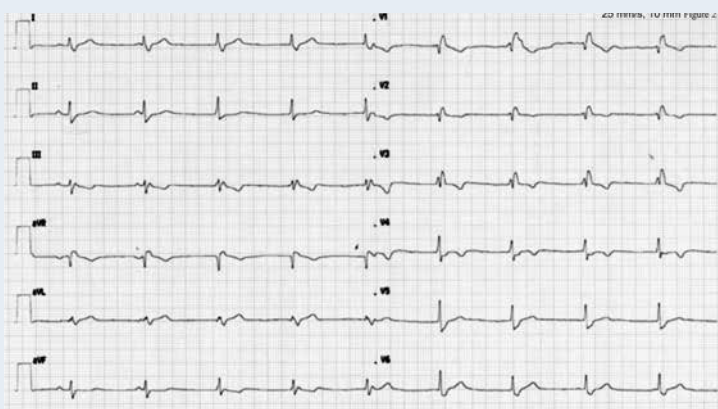


Figure 2. Sinus rhythm with RBBB morphology, HR of 55 bpm, AV dissociation, nodal rhythm, HR of 58 bpm

#### Address for correspondence:

Katarzyna Mitreęa, MD, PhD, Department of Cardiology, Congenital Heart Diseases and Electrotherapy, Silesian Medical University, Silesian Centre of Heart Diseases, ul. Curie-Skłodowskiej 9, 41-800 Zabrze, Poland, e-mail: kas-k2@o2.pl

**Conflict of interest:** R. Lenarczyk — consultant at Medtronic and Biotronik; B. Średniawa — consultant at Medtronic Bakken Research Center, Bristol Myers-Squibb, Pfizer, fees for lectures: Boehringer-Ingelheim, Servier and MSD, Berlin-Chemie; others — none declared.