

# Giant intrathoracic haematoma compressing the left atrium after PCI for degenerated saphenous vein graft

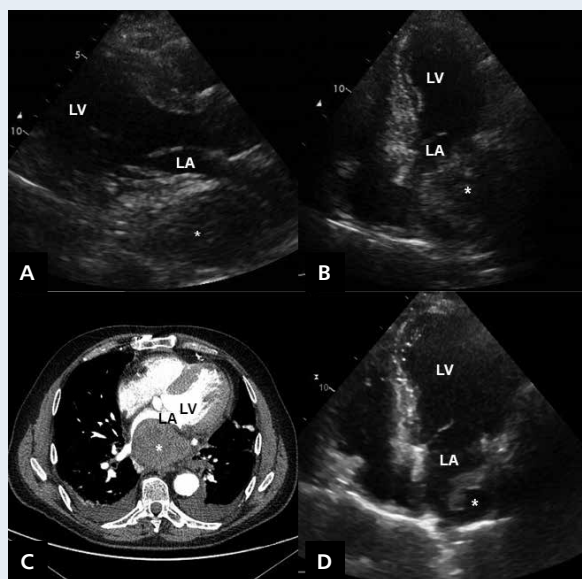
Angioplastyka zdegenerowanego graftu żylnego powikłana olbrzymim krwiakiem śródpiersia uciskającym lewy przedsionek

Maksymilian Mielczarek<sup>1</sup>, Miłosz Jaguszewski<sup>1,2</sup>, Joanna Wdowczyk<sup>1</sup>, Dariusz Ciećwierz<sup>1</sup>, Marcin Gruchała<sup>1</sup>

<sup>1</sup>1<sup>st</sup> Department of Cardiology, Medical University of Gdansk, Gdansk, Poland

<sup>2</sup>University Heart Centre, University Hospital of Zurich, Zurich, Switzerland

A 61-year-old male patient with a 17-year history of coronary multi-vessel disease and coronary artery bypass graft (CABG) was admitted for the exacerbation of angina. Bedside echocardiography demonstrated hypokinesis in basal, posterior and lateral segments of the left ventricle (LV). Coronary angiography revealed a chronic occlusion of both native coronary arteries and two critical lesions in saphenous vein graft (SVG) to posterolateral branch of the circumflex coronary artery. Therefore, we subsequently attempted percutaneous coronary intervention (PCI) for the degenerated SVG utilising Judkins R4 8 French guiding catheter and SpideRX Embolic Protection Device for distal embolic protection. Both lesions were predilated using a 4.0 × 20 mm Maverick balloon. The distal lesion was covered with bare-metal stent (5.0 × 13 mm Pro-Kinetic) followed by self-expanding 7.0 × 30 mm Wallstent implanted to cover the proximal stenosis. A second stent was postdilated with a 5.0 × 15 mm Maverick balloon. The periprocedural course was uneventful and a satisfactory angiographic result was achieved. Several hours after the PCI, the patient complained of chest pain. Serial electrocardiographic records did not reveal new ischaemic changes, and echocardiography identified neither new segmental LV systolic dysfunction nor hydropericardium. Due to a positive troponin test and the fulfilled criteria of periprocedural myocardial infarction (MI), hospitalisation was prolonged. A three-day-echocardiography documented a structure suggesting a large thrombus in the left atrium (LA) or a large mass pressing upon the LA from outside (Figs. 1A, B). Computed tomography angiography (CTA) identified a large mass of 80 mm × 82 mm × 86 mm adjoining the right wall of treated SVG (Fig. 1C). Urgent coronary angiography excluded SVG perforation. The patient remained asymptomatic with no haemodynamic compromise, and a conservative treatment strategy was applied. A CTA performed after ten days showed a reduction of mediastinal haematoma. Due to frequent episodes of paroxysmal atrial fibrillation and non-sustained supraventricular tachycardia, therapy with sotalol and warfarin was implemented. The patient was discharged home on the 26<sup>th</sup> day. A month later, echocardiography (Fig. 1D) and CTA documented further haematoma resolution. The patient continues to do well 12 months after the index event. SVG degeneration is the drawback of this commonly used technique of CABG. Potentially life-threatening SVG rupture remains a rare complication and can be discovered incidentally. The initial strategy is to prevent blood leakage by prolonged inflation of the balloon prior to rupture. Frequently, final implantation of stent graft is necessary. Successful treatment may however be hampered by the lack of an appropriate stent graft 'off the shelf', because of the abnormally large diameter of degenerated SVG. We here present a case of particular clinical significance where an intrathoracic haematoma that compressed the LA occurred after PCI of SVG with a clinical presentation of periprocedural MI but with no haemodynamic compromise, and thus treated conservatively with an elegant result.



**Figure 1.** A. Parasternal long axis view; B. Apical four-chamber view; C. Computed tomography angiography transverse plane; D. Apical four-chamber view; asterisk — intrathoracic haematoma; LA — left atrium; LV — left ventricle

**Address for correspondence:**

Maksymilian Mielczarek, MD, 1<sup>st</sup> Department of Cardiology, Medical University of Gdansk, ul. Dębinki 7, 80-952 Gdańsk, Poland, e-mail: max.mielczarek@gmail.com

**Conflict of interest:** none declared