

A new diagnosis of severe aortic stenosis in a 77-year-old woman

Nowo rozpoznana ciężka stenoza aortalna u 77-letniej kobiety

Guoning Zeng, Yanping Wang, Xuerui Tan, Min Yu

Department of Cardiology, 1st Affiliated Hospital, Shantou University Medical College, Shantou, China

A 77-year-old woman was presented to our department after suffering from 20 days of dizziness and fatigue. She had a history of hypertension for 40 years and type 2 diabetes mellitus for ten years. On examination, blood pressure was 172/67 mm Hg (right upper extremity), 170/70 mm Hg (left upper extremity), 85/57 mm Hg (right lower extremity) and 98/60 mm Hg (left lower extremity). Computed tomography angiography of aorta showed stenosis of left subclavian artery (Fig. 1A) and severe descending aortic stenosis (Figs. 1B, C), with extensive collateralisation between subclavian artery and arteria iliaca externa. Takayasu arteritis (TA), a rare type of large-vessel vasculitis that affects the aorta and its major branches, is more prevalent in Asian countries, and affects women more often than men. Although TA is generally considered to be a disease of younger adults, there are multiple reports of TA in patients over 60 years of age. However, severe aortic stenosis presenting in a 77-year-old woman is extremely rare, with survival dependent upon collateral circulation.

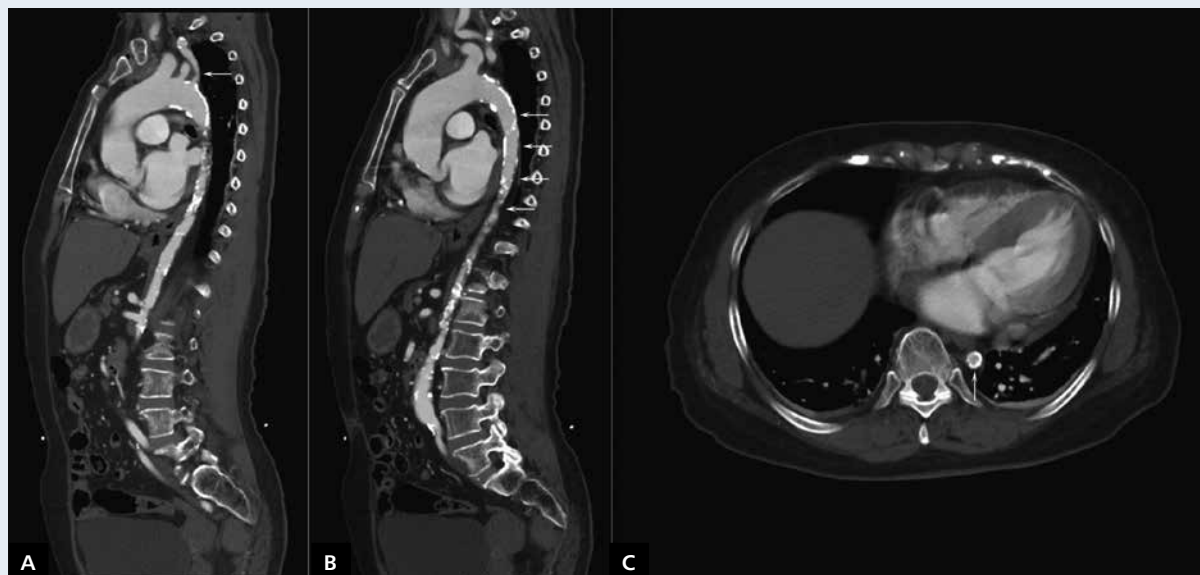


Figure 1. Computed tomography angiography of aorta; **A.** Stenosis of left subclavian artery; **B, C.** Severe descending aortic stenosis, with extensive collateralisation between subclavian artery and arteria iliaca externa

Address for correspondence:

Dr Min Yu, Department of Cardiology, 1st Affiliated Hospital, Shantou University Medical College, Shantou, Guangdong 515041, China, tel: +86-754-88905337, fax: +86-754-88259850, e-mail: stmedt2008@163.com

Conflict of interest: none declared