

Should a cardioverter-defibrillator be implanted in an Andersen-Tawil syndrome patient with severe ventricular arrhythmias and syncope?

Czy wszczepiać kardiowerter-defibrylator chorej z zespołem Andersen-Tawila oraz z nasiloną arytmia komorową i omdleniem?

Piotr Bienias¹, Anna Kostera-Pruszczyk², Katarzyna Bieganowska³, Maria Miszczak-Knecht³, Piotr Pruszczyk¹

¹Department of Internal Medicine and Cardiology, Medical University of Warsaw, Warsaw, Poland

²Department of Neurology, Medical University of Warsaw, Warsaw, Poland

³Department of Cardiology, Children's Memorial Health Institute, Warsaw, Poland

A 20-year-old woman with genetically-confirmed Andersen-Tawil syndrome (ATS) at the age of 12 (D71V mutation KCJN2 gene), with typical ATS dysmorphic features (hypertelorism, mandibular hypoplasia, clin- and syndactyly) was admitted to our department due to recurrent ventricular arrhythmias (VA) and prolonged syncope a few months earlier during everyday activity. ATS was also diagnosed in her father who suffers from periodic paralysis. Until now VA had been asymptomatic in our patient. However, in numerous 24-h Holter performed since the diagnosis, VA constituted 18–29% of all daily beats and frequent episodes of bidirectional ventricular tachycardia were always detected. In standard electrocardiography (ECG), sinus rhythm and no marked QTc prolongation or no U-wave were observed (Fig. 1). Exercise test and echocardiography were normal. The patient was being treated with propranolol (100 mg daily) and avoided drugs inducing QT prolongation. At present, Holter monitoring showed over 20,000 polymorphic ventricular premature beats (including frequent pairs, bigeminy or trigeminy) and over 600 bidirectional non-sustained ventricular tachycardia (max. 19 beats, max. 120–150 bpm), without bradyarrhythmias (Fig. 2). Importantly, the severity of current VA was similar to that observed previously. Since the patient had experienced a prolonged syncope a few months previously, this raised the question of whether an implantable cardioverter-defibrillator (ICD) should be implanted. ATS is a rare genetic disorder combining frequent VA occurrence, prominent U-wave in ECG, mild QTc prolongation, various extracardiac features including periodic paralysis and various dysmorphic features. ATS symptoms vary, even within the same family (as in our patient). Sometimes ATS is called long-QT syndrome type 7, although the QT interval itself is seldom prolonged. In most ATS patients, a mutation in the KCJN2 gene has been found (encoding potassium channel Kir2.1). As ATS is a rare disease, no definitive recommendations for VA management are available. Ablation attempts fail in many cases. Pharmacological treatment is not beneficial in many patients either. In some ATS cases, ICD implantations are indicated. In a group of 15 genetically confirmed ATS patients seen at our departments, an ICD was implanted in six cases due to recurrent syncope (four patients) or even cardiac arrest (two cases). It seems that beta-blocker therapy (especially propranolol) is of clinical value, however successful calcium channel blockers therapy or a combination of flecainide plus beta-blockers therapies have also been described. According to current guidelines, ICD should be implanted especially in a severe VA patient resistant to drug therapy, with syncope, with left ventricular dysfunction or after cardiac arrest. It must be underlined that ICD implantation in ATS does not eliminate frequent VA. An optimal programming of ICD in ATS is difficult and shocks may be expected even at full consciousness, too. Moreover, bidirectional ventricular tachycardia typical for ATS is usually self-terminating and syncope in ATS repeats itself only rarely. However sudden cardiac death has been reported in ATS patients (it occurs in about 10% of subjects). Our patient after a detailed electrophysiology consultation is still considering ICD implantation, and is scheduled for regular follow-up at our department.

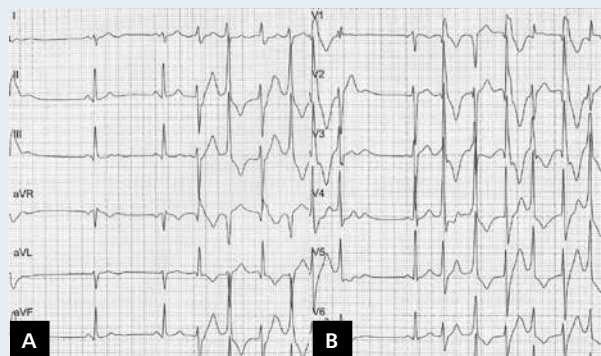


Figure 1. A, B. Standard ECG. Sinus rhythm 54 bpm. Right axis deviation. QT interval 360 ms. No distinct U wave. Bidirectional ventricular tachycardia

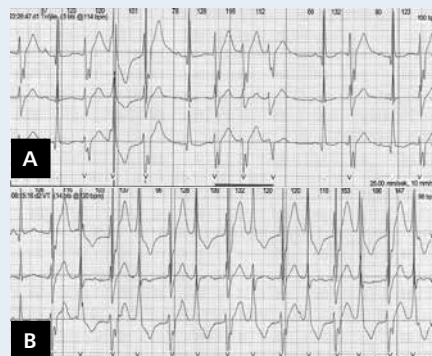

Figure 2. Strips of three-channel 24-h Holter monitoring. Sinus rhythm. Monomorphic (A) and bidirectional (B) non-sustained ventricular tachycardia

Address for correspondence:

Piotr Bienias, MD, PhD, Department of Internal Medicine and Cardiology, Medical University of Warsaw, ul. Lindleya 4, 02-005 Warszawa, Poland, e-mail: pbienias@mp.pl

Conflict of interest: none declared