

# Pregnancy-related physiological changes in cardiovascular system observed with implantable cardioverter-defibrillator

Fizjologiczne zmiany w układzie sercowo-naczyniowym w trakcie ciąży obserwowane za pomocą implantowalnego kardiowertera-defibrylatora

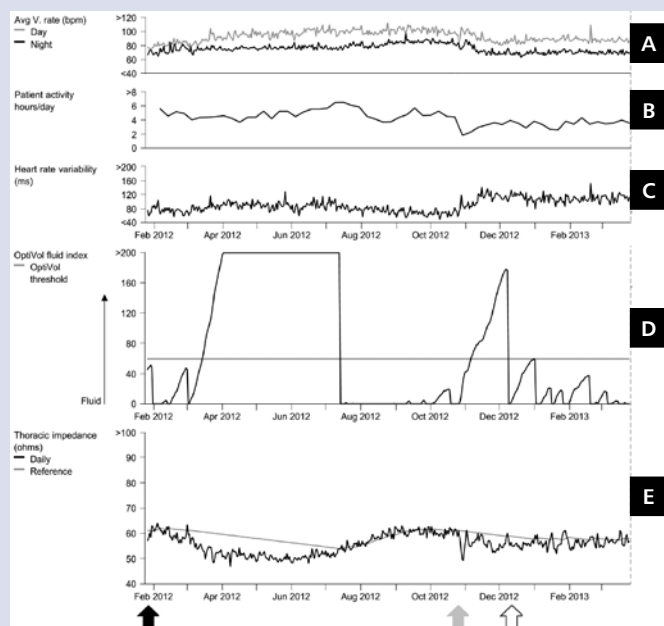
Marcin Michalak<sup>1</sup>, Andrzej Cacko<sup>1,2</sup>, Marcin Grabowski<sup>1</sup>

<sup>1</sup>1<sup>st</sup> Department of Cardiology, Medical University of Warsaw, Warsaw, Poland

<sup>2</sup>Department of Medical Informatics and Telemedicine, Medical University of Warsaw, Warsaw, Poland

A 30-year-old woman was implanted with a single chamber implantable cardioverter-defibrillator (ICD) system in 2006 due to successfully resuscitated ventricular fibrillation. In 2009, she underwent ICD replacement with another defibrillation lead implantation due to lead failure. She had no comorbidities and the function of the heart was normal, with left ventricular ejection fraction at 65%. In February 2012, the patient became pregnant. From the 5<sup>th</sup> week of pregnancy, the beta-blocker (bisoprolol 2.5 mg o.d.) was stopped and she did not take any other medications until delivery. On the 39<sup>th</sup> week, she underwent an elective caesarean section due to obstetric indications. Delivery and postpartum period were uncomplicated. Present ICD device (Medtronic, Virtuoso VR) was equipped with several diagnostic functions known as Cardiac Compass<sup>®</sup>. Parameters such as heart rate (HR), HR variability (HRV), daily activity, thoracic impedance and OptiVol<sup>®</sup> fluid index were measured automatically every day and produced some long-term trends. All the trends are stored up to 14 months, allowing us to observe some physiological changes in the cardiovascular system that were occurring during pregnancy. Normal pregnancy is linked with several structural and functional changes in the cardiovascular system that are necessary to meet the increasing metabolic demands of mother and developing foetus. The main changes include increases in blood volume and cardiac output, and decreases in systemic vascular resistance and blood pressure. Total body water of a pregnant woman increases by 6–8 L and is located mostly in extracellular space. There is about a 40% increase in blood volume caused mainly by an increase in plasma volume. The heart muscle undergoes a mild remodelling that leads to ventricular hypertrophy as well as dilatation.

We present trends of cardiovascular parameters received during routine follow-up that have been done six months after delivery (Figs. 1A–E). Typical HR acceleration during pregnancy by about 15 bpm and its normalisation after childbirth was noted (Fig. 1A). HRV is decreased in a pregnant woman due to a shift in autonomic balance and it returns to the pregestational state after delivery, as in this case (Fig. 1C). Patient's activity at 4–6 h per day was maintained during the course of pregnancy until delivery, where a sudden drop was noted corresponding to convalescence following the c-section (Fig. 1B). The first and most pronounced change observed was rapid and prolonged decrease of thoracic impedance (Fig. 1E) which translated into a corresponding rise of fluid index above the alarm threshold (Fig. 1D). Several factors may play a role in these observations, e.g. fluid retention in thorax and lungs and heart enlargement. A similar but slighter reduction in thoracic impedance observed at the time of delivery may be explained by a sudden increase in venous return secondary to decompression of vena cava inferior as well as increased vascular tone due to sympathetic system activation. The high amplitude and rate of impedance changes that are associated with pregnancy result in inadequate fluid overload alarms, and make this method inappropriate in monitoring pregnant women.



**Figure 1.** Physiological changes in cardiovascular system parameters associated with pregnancy; **A.** Average ventricular rate trend; **B.** Patient activity trend (hours per day); **C.** Heart rate variability trend; **D.** OptiVol<sup>®</sup> fluid index trend; **E.** Thoracic impedance trend; black arrow — onset of pregnancy; grey arrow — day of delivery; white arrow — end of postpartum period

#### Address for correspondence:

Marcin Grabowski, MD, PhD, 1<sup>st</sup> Department of Cardiology, Medical University of Warsaw, ul. Banacha 1a, 02-097 Warszawa, Poland, e-mail: grabm@tlen.pl

**Conflict of interest:** none declared