

# Stenosis in proximal LAD in a 34-year-old female with essential thrombocythemia treated with novel bioabsorbable scaffold

Stenoza proksymalnej części LAD u 34-letniej kobiety z nadpłytkowością samoistną leczoną za pomocą nowego stentu bioresorbowalnego

Anna Wolska-Bulach<sup>1</sup>, Anna Smukowska-Gorynia<sup>2</sup>, Lucyna Woźnicka-Leśkiewicz<sup>1</sup>, Aleksander Araszkiwicz<sup>2</sup>, Andrzej Tykarski<sup>1</sup>

<sup>1</sup>Department of Hypertensiology, Angiology and Internal Diseases, Poznan University of Medical Sciences, Poznan, Poland

<sup>2</sup>1<sup>st</sup> Department of Cardiology, Poznan University of Medical Sciences, Poznan, Poland

A 34-year-old woman was hospitalised in the Department of Hypertensiology due to chest pain that had occurred after a few minutes of exercise and stopped quickly at rest. Past history: Preterm delivery because of maternity gestosis and hypertension (2007), glomerulonephritis (2008), tonsillectomy (2008), appendectomy, miscarriage (2009), delivery by caesarean section (2011). Laboratory results: Elevated levels of: PLT, total and LDL cholesterol, RBC, potassium, granulocyte-alkaline phosphatase; negative troponin; positive antibodies ANA (1:160 — speckled light type), V617F JAK2 mutation gene by PCR; low level of erythropoietin. Bone marrow biopsy revealed an increased number of megakaryocytes without evidence of fibrosis. Essential thrombocythemia (ET) was diagnosed. ECG: The sinus rhythm with negative T-waves in V<sub>2</sub>-V<sub>4</sub>. Echocardiography: Hypokinesis of basal segment of intraventricular septum with ejection fraction 65%. The ECG stress test was electrocardiographically (ST-segment depression in the inferior and lateral walls) and clinically (chest pain) positive. The coronarography revealed critical stenosis (95%) in the ostium of left anterior descending coronary artery (LAD) (Fig. 1), a circuit filled with a delay, without changes in other coronary arteries. The intravascular ultrasound (IVUS) confirmed very small minimal luminal area (2.1 mm<sup>2</sup>) (Fig. 2). The patient was qualified by the heart team for percutaneous coronary intervention (PCI) of LAD. The implantation of an everolimus-eluting bioresorbable vascular scaffold (BVS) Absorb 3.5 × 18 mm was successfully performed (Fig. 3). After the PCI, the patient was discharged with the regimen to take: acetylic acid, ticagrelor for 12 months (90 mg twice a day), metoprolol, pantoprazol and atorvastatin. At 5-month follow up, control coronarography showed no signs of stenosis in LAD. Optical coherence tomography (OCT) confirmed the proper neointimal response without scaffold area obstruction (Fig. 4). The ECG and echocardiography revealed no abnormalities. Critical stenosis of coronary arteries or myocardial infarction (MI) is a rare complication of ET in young patients. According to the literature, approximately 13% of patients younger than 40 years at diagnosis experience thrombotic events such as: transient ischaemic attack, MI, stroke, peripheral arterial and venous thrombosis. ET treatment is always a challenge, due to the high risk of recurrent thrombosis. BVS resorption is completed within 3 years after device implantation, thus allowing the artery to restore its physiological vasomotor response as well as reduce chronic inflammation and late stent thrombosis. We assumed that the novel BVS Absorb and antiplatelet drug as ticagrelor used in our case should improve the outcomes of treatment due to better protection against restenosis.

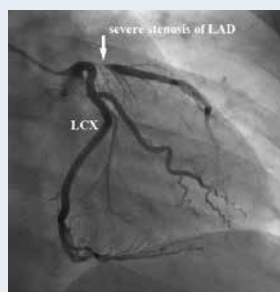


Figure 1. Angiogram. Severe stenosis of LAD proximal segment; LCX — left circumflex artery

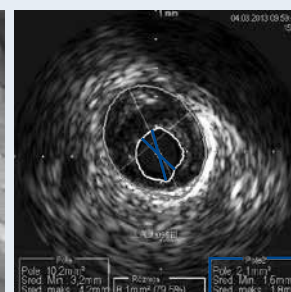


Figure 2. IVUS. Severe stenosis of LAD proximal segment with the minimal luminal area 2.1 mm<sup>2</sup>

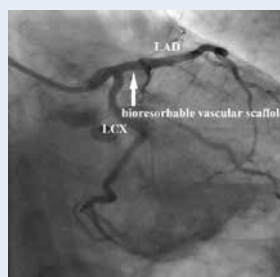


Figure 3. The PCI of LAD (implantation of BVS); LCX — left circumflex artery

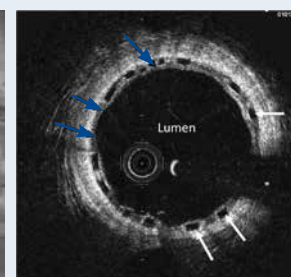


Figure 4. Five-month follow-up. OCT cross-sectional image. BVS struts (white arrows) covered with thin neointima layer (blue arrows)

#### Address for correspondence:

Dr Anna Wolska-Bulach, Department of Hypertensiology, Angiology and Internal Diseases, Poznan University of Medical Sciences, ul. Długa 1/2, 61-848 Poznań, Poland, e-mail: annawolskabulach@gmail.com

**Conflict of interest:** none declared