

# Heart perforation by pro-MRI right ventricular lead in a 26-year-old woman

Perforacja serca przez elektrodę komorową pro-MRI u 26-letniej kobiety

Małgorzata Hardzina<sup>1</sup>, Andrzej Ząbek<sup>1</sup>, Bartosz Laskowicz<sup>2</sup>, Anna Rydlewska<sup>1</sup>, Krzysztof Boczar<sup>1</sup>, Barbara Małecka<sup>1, 3</sup>

<sup>1</sup>Department of Electrophysiology, John Paul II Hospital in Krakow, Poland

<sup>2</sup>Department of Radiology, John Paul II Hospital in Krakow, Poland

<sup>3</sup>Institute of Cardiology, Jagiellonian University Medical College in Krakow, Poland

A 26-year-old patient had a VVI pacemaker implanted at the age of nine due to congenital complete atrio-ventricular block. Unipolar passive-fixation Pacesetter Membrane lead was implanted to the right ventricle apex (Fig. 1A). For the following 17 years, the patient felt well. She underwent an elective device replacement and gave birth naturally. Recently, the patient had transient ischaemic attacks twice with symptoms of syncope accompanied by transient motor aphasia, disorder of vision and right-side hypoesthesia. To give a final neurological diagnosis, magnetic resonance imaging (MRI) of the brain was demanded. Additionally, routine pacemaker follow-up showed an episode of miopotential oversensing. For these two reasons, the patient was qualified for transvenous lead extraction (TLE) with simultaneous implantation of DDD pro-MRI stimulation system. Using a mechanical Cook system, the old ventricular lead was removed and new active-fixation, bipolar Medtronic CapSureFixMRI was initially implanted to the right ventricular outflow tract. However, due to intraoperative dislocation of the lead, it was finally placed in

the periapical region of the right ventricle. Atrial lead was implanted to the right atrial appendage. A Medtronic Ensura DR pacemaker was placed in the previous pocket (Fig. 1B). Beginning from the day following the procedure, the patient felt recurring pricking pain in the apical region radiating to the right shoulder. These symptoms aggravated significantly over the following few weeks and were the reason for the patient's readmission. During the device follow-up, a high pacing threshold was noted (unipolar [UP]: 4.25 V/1 ms; bipolar [BP]: 2.0 V/1 ms). Sudden increase of the threshold value was recorded in the device's stored data (from 1.3 V/0.4 ms to 2.5 V/0.4 ms in BP configuration). Variation of R wave sensing in BP measurements (from 5 mV to 14.5 mV) synchronised with heart cycle was also detected. Moreover, R wave sensing values were two times higher in BP than in UP measurements. Heart apex perforation by ventricular lead was confirmed in transthoracic echocardiography (TTE) (Fig. 2) and computed tomography (CT) (Fig. 3). Another urgent TLE of the ventricular lead with cardio-surgical back-up was performed. Subclavian vein obstruction revealed in venography before the procedure became a significant difficulty during the TLE procedure (Fig. 4). The perforating lead was removed using a yellow Byrd dilator from Cook Medical. A new lead was implanted to intra-ventricular septum through regained vessel lumen (Fig. 1C). The whole procedure was uneventful. TTE on the third day after the procedure showed an increased amount of fluid in the pericardial space (from 4 mm to 11 mm), which decreased over the following days. The patient was discharged in good condition. The probable cause of heart perforation was the displacement of lead tip into the channel remaining after removal of the 17-year-old lead.

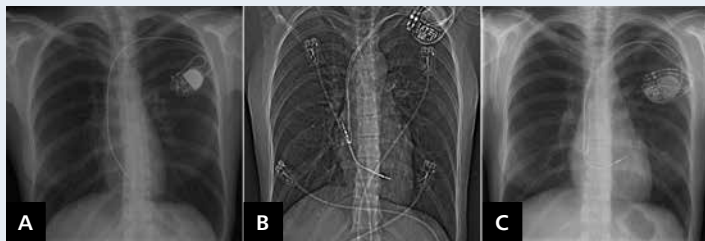

Figure 1. Chest X-ray in PA projection; A. VVI pacemaker; B. Perforating lead; C. Final pacemaker

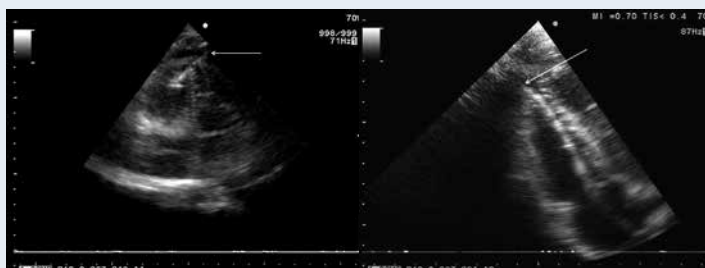

Figure 2. TTE (arrow) the lead tip in pericardial space

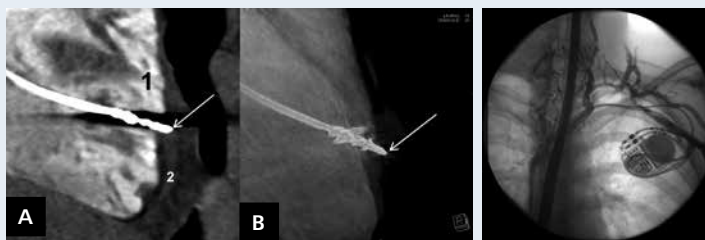

Figure 3. CT (arrow) perforating lead tip; A. Multiplanar reconstruction; 1 — right heart cavity with contrast medium; 2 — pericardial sac space; B. Volume rendering technique

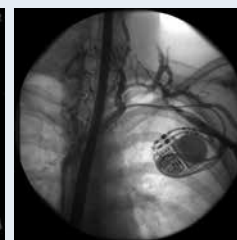


Figure 4. X-ray: vein obstruction with collateral circulation

#### Address for correspondence:

Andrzej Ząbek, MD, MSc, Department of Electrophysiology, John Paul II Hospital in Krakow, ul. Prądnicka 80, 31-202 Kraków, Poland, e-mail: andrzej\_j\_z@poczta.onet.pl

**Conflict of interest:** Anna Rydlewska — faculty fee for Medtronic