

Implantation of a bioabsorbable vascular scaffold into a coronary vein graft: a two-week angiography follow-up

Implantacja bioabsorbowalnego stentu do żylnego pomostu wieńcowego w obserwacji dwutygodniowej

Tomasz Roleder¹, Andrzej Ochała², Grzegorz Smolka³, Wojciech Wańha³, Wojciech Wojakowski³

¹2nd Department of Cardiology, Medical University of Silesia, Katowice, Poland

²Department of Invasive Cardiology, Medical University of Silesia, Katowice, Poland

³3rd Department of Cardiology, Medical University of Silesia, Katowice, Poland

An 83-year-old patient with a history of coronary artery bypass grafting (CABG) performed 13 years ago was admitted due to unstable angina for diagnostic catheterisation. His medical history consisted of CABG with left internal mammary artery to left anterior descending artery and vein grafts to obtuse margin artery (OM), diagonal artery (D1) and right coronary artery (RCA). Following that, the patient had multiple percutaneous coronary interventions (PCI) in vein grafts: bare metal stent implantation into the Ao-OM (three years ago), two POBA of Ao-OM (one and two years ago), two drug eluting stents (DES) into Ao-OM (six and 12 months ago), and DES into Ao-D1 (two years ago). Coronary angiography revealed significant stenosis in distal segment of Ao-RCA and in stent restenosis in DES implanted to Ao-OM. The lesion in Ao-RCA (% diameter stenosis = 82%, minimal diameter = 0.43 mm, lesion length = 5 mm) was treated with an everolimus-eluting bioabsorbable vascular scaffold (BVS) (Absorb, 2.5 × 15 mm) achieving good post procedural angiographic results (% diameter stenosis = 13%, minimal diameter = 2.5 mm) (Fig. 1). Two weeks after the procedure, the patient was hospitalised again for an elective PCI of Ao-OM in stent restenosis. The bypass angiography revealed patent Ao-RCA with sustained good angiographic results at the site of BVS implantation. Drug eluting BVS implantation may be a new option for the treatment of stenotic coronary vein grafts. However, a prospective study is needed to validate the safety of such a BVS application.

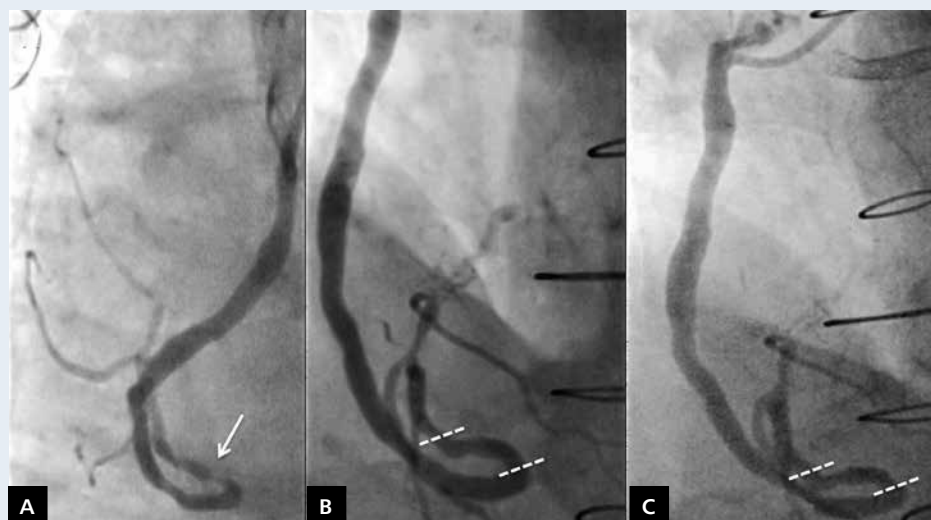


Figure 1. Two-week angiographic follow-up of the bioabsorbable vascular scaffold implantation into the vein graft of the right coronary artery; **A.** 82% stenosis of the right coronary vein graft (white arrow); **B.** The final effect of Absorb (2.5 × 18 mm) implantation into the right coronary vein graft (white dashed lines); **C.** Two-week follow-up of the Absorb stent implantation into the vein graft (white dashed lines)

Address for correspondence:

Tomasz Roleder, MD, PhD, 2nd Department of Cardiology, Medical University of Silesia in Katowice, ul. Ziolowa 45/47, 40-635 Katowice-Ochojec, Poland, e-mail: tomaszroleder@gmail.com

Conflict of interest: none declared