

Paravalvular aortic regurgitation as the reason for second CoreValve bioprosthesis implantation in a patient with native bicuspid valve

Niedomykalność okołozastawkowa jako przyczyna implantacji drugiej bioprotezy CoreValve u pacjenta z natywną zastawką dwupłatkową

Zenon Huczek, Janusz Kochman, Bartosz Rymuza, Piotr Scisło, Radosław Wilimski, Grzegorz Opolski

1st Chair and Department of Cardiology, Medical University of Warsaw, Poland

We present the case of a 70-year-old male patient who was admitted to our centre with severe symptomatic aortic stenosis. His medical history included: hypertension, stroke (1998 and 2013) with subsequent left-sided paraparesis and status after traumatic upper right limb amputation in his youth. Patient's logistic EuroSCORE was 18.1%, EuroSCORE II 5.7% and the Society of Thoracic Surgeons Score 2.7%. Transthoracic echocardiography showed impaired left ventricular ejection fraction of 27%, mean aortic pressure gradient of 70.5 mm Hg, aortic valve area of 0.6 cm², and peak velocity of 6.3 m/s. For precise aortic annulus measurement, transoesophageal echocardiography (TEE) and a computed tomography scan were performed and revealed a heavily calcified bicuspid valve with mean annulus diameter of 24 mm. Angiography demonstrated a significant lesion in the 3rd segment of right coronary artery (RCA). Due to the high operative risk, the patient was referred by the Heart Team for percutaneous coronary intervention of RCA and transcatheter aortic valve implantation (TAVI) via the femoral route (considering the absence of atherosclerotic lesions in ilio-femoral arteries). Native valve was predilated with a 22 mm Numed balloon catheter (Fig. 1A). On the basis of pre-procedural imaging, a 29 mm Medtronic CoreValve™ bioprosthesis was implanted at the annulus level. However, control angio and TEE showed low implantation accompanied by significant paravalvular aortic regurgitation (Fig. 1B). Haemodynamic measurement also confirmed a suboptimal effect with low diastolic aortic pressure (DAP) and high left-ventricular end-diastolic pressure (LVEDP) (Fig. 2A). Therefore, the decision was made to implant a second bioprosthesis — another 29 mm CoreValve was placed and deployed 8–10 mm higher than the first one (Fig. 1C). Implantation of the second valve significantly decreased the magnitude of regurgitation from severe to no or mild, both in angiography and pressure recordings (Figs. 1D and 2A, respectively).

It has been shown in several observational and randomised trials that even mild paravalvular regurgitation after TAVI is an independent predictor of long-term mortality. It is therefore of crucial importance to diagnose early and minimise the grade of regurgitation by post-dilatation or second valve deployment. This case demonstrates that apart from imaging modalities, direct pressure measurement is an easy, reliable and reproducible method of paravalvular leak detection. Recently, it has been shown in a non-selected population of TAVI procedures that pressure gradient $\Delta_{DAP-LVEDP}$ is a powerful predictor of mortality.

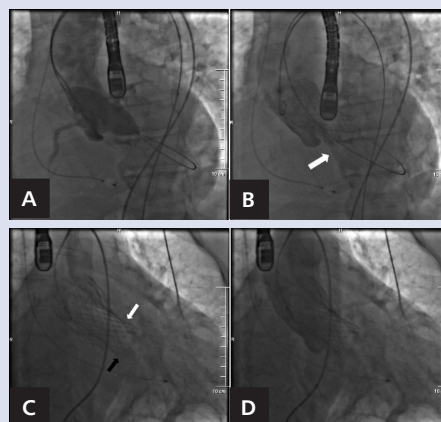


Figure 1. A. Predilatation of native valve with 22 mm balloon catheter; B. Severe paravalvular regurgitation after 29 mm CoreValve implantation (white arrow); C. Status post second 29 mm prosthesis placement, black arrow — distal edge of first CoreValve, white arrow — distal edge of second bioprosthesis; D. No-to-mild regurgitation after second CoreValve deployment

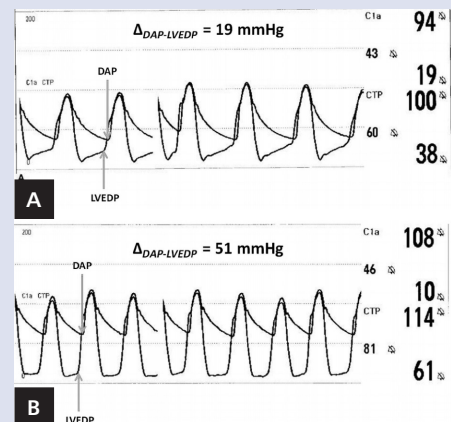


Figure 2. Invasive haemodynamics with simultaneous measurement of aortic and left ventricular pressures; A. Severe regurgitation after first CoreValve placement with low pressure gradient $\Delta_{DAP-LVEDP}$; B. Significant improvement after implantation of second bioprosthesis reflected by $\Delta_{DAP-LVEDP}$ increase

Address for correspondence:

Zenon Huczek, MD, PhD, 1st Chair and Department of Cardiology, Medical University of Warsaw, ul. Banacha 1A, 02-097 Warszawa, Poland, e-mail: zenon.huczek@wum.edu.pl

Conflict of interest: none declared