

Optical coherence tomography to reveal vascular lesions after catheter-based renal nerve ablation with a novel multi-electrode EnligHTN™ system

Optyczna tomografia koherencyjna ujawniająca uszkodzenie naczyń po przezcewnikowej denerwacji tętnic nerkowych z zastosowaniem nowego systemu wieloelektrodowego EnligHTN™

Milosz Jaguszewski, Jelena-Rima Ghadri, Thomas F. Lüscher, Christian Templin

Cardiovascular Centre Cardiology, University Hospital of Zurich, Zurich, Switzerland

A 72-year-old female with a history of sleep apnoea syndrome was referred to the Andreas Gruentzig Catheterisation Laboratories for catheter-based renal nerve ablation (RNA) due to drug-resistant, uncontrolled hypertension. After intravenously loading with aspirin, the RNA was obtained using the first generation multi-electrode EnligHTN™ system (St. Jude Medical, Westford, MA, USA) delivering 8 ablation runs on both the left and the right renal artery. Before and after the RNA procedure, optical coherence tomography (OCT) was performed using the C7-XR imaging system (LightLab Imaging, Inc., Westford, MA, USA) with a non-occlusive technique and a single-mode optical fibre catheter (frequency domain-OCT-catheter, DragonFly™, St. Jude Medical, Westford, MA, USA). The OCT catheter was advanced over a standard 0.014" angioplasty guidewire using a monorail lumen at the tip. To optimise pullback recordings, renal arteries were flushed of blood with Ultravist 300 (Bayer House, Berkshire, United Kingdom) at a flow rate of 8.0 mL/s and the application of an automated pullback speed of 20 mm/s. The post-procedural pullback visualised local oedemas (Fig. 1A, B) concomitant with significant thrombi formations (Fig. 1A, C) and small disruptions (Fig. 1D, arrow). The clinical course was uneventful and the patient was discharged home on the second day of hospitalisation.

Catheter-based RNA has been recently approved for the treatment of resistant hypertension. During the RNA procedure, transmural lesions are delivered along the walls of the renal arteries to disrupt the sympathetic nerve network located within the arterial adventitia.

Here, we report a case in which OCT was performed to reveal potential periprocedural vascular side effects. The RNA was obtained using a novel EnligHTN™ catheter delivering a basket with 4 radiopaque electrodes (Fig. 1E, inset). The design of the EnligHTN™ system enabled simultaneous ablation runs, minimising catheter manipulation (Fig. 1E, arrows). However, the performance of OCT revealed several local lesions including post-ablation oedemas, thrombi formations and tissue disruptions. OCT provides novel insights on vascular effects of RNA, suggesting the potential need for double antiplatelet therapy before the procedure. However, the safety and efficacy of the new catheter-based RNA devices require soon to be evaluated in greater detail.

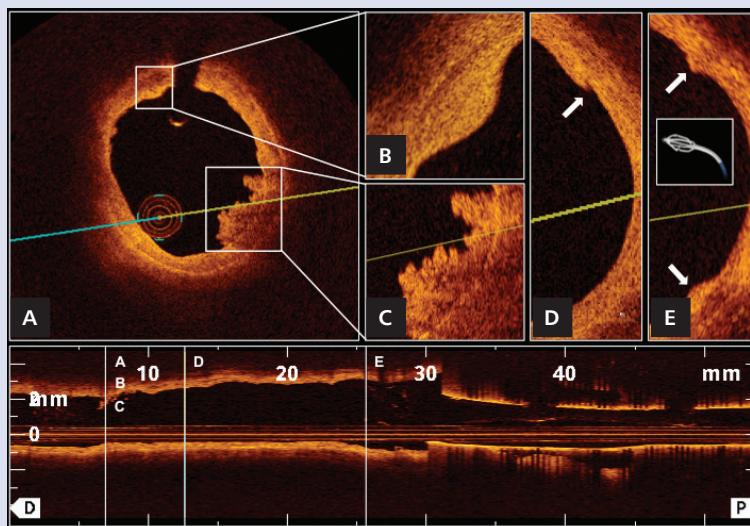


Figure 1. Optical coherence tomography (cross-sections and pullback) to reveal local acute morphological vascular changes after catheter-based RNA such as thrombus formations (A, C), vessel notches (B, E) and dissections (D)

Address for correspondence:

Milosz Jaguszewski, MD, Cardiology, Cardiovascular Centre, University Hospital of Zürich, 8091 Zürich, Switzerland, tel: +41 44 255 99 76, e-mail: milosz.jaguszewski@usz.ch

Conflict of interest: The institution of the authors has received educational and research grants from St. Jude Medical, Brussels, Europe. T.F.L. has received consultant honoraria from St. Jude Medical.