

Association of quadricuspid aortic valve and ventricular septal defect in a patient who had undergone atrial septal defect surgery

Współwystępowanie czteropłatkowej zastawki aortalnej i ubytku w przegrodzie międzykomorowej u chorego poddanego zabiegowi zamknięcia ubytku w przegrodzie międzyprzedsionkowej

Sait Demirkol¹, Sevket Balta¹, Zekeiya Arslan², Murat Unlu³, Ugur Kucuk¹, Atila Iyiso¹

¹Gulhane Medical Faculty Cardiology, Ankara, Turkey

²Gelibolu Hospital Cardiology, Canakkale, Turkey

³Beytepe Hospital Cardiology, Ankara, Turkey

Quadricuspid aortic valve (QAV) is a rare congenital cardiac anomaly. QAV can be associated with other congenital cardiac abnormalities, such as ventricular or atrial septal defect, aneurysm of Valsalva sinus, and patent ductus arteriosus. A 20 year-old man was referred to our outpatient unit for evaluation of a systolic heart murmur. The patient had undergone atrial septal defect surgery 10 years previously. Electrocardiography showed a normal sinus rhythm with a right bundle branch block. Two-dimensional (2D) transthoracic echocardiography (TTE) showed moderate right ventricular dilatation and the calculated Qp/Qs was 2.2. For further evaluation, we applied 2D and 3D transoesophageal echocardiography (2D and 3D TEE), which revealed the aortic valve consisted of 4 leaflets of differing sizes (Fig. 1A). 2D colour Doppler TEE displayed a mild aortic regurgitation and a ventricular septal defect (Fig. 1B). 3D TEE full volume view also revealed QAV (Fig. 1C). Left ventriculography demonstrated a membranous ventricular septal defect (Fig. 1D). We decided to close this defect because he was symptomatic and Qp/Qs was higher than normal values. Hurwitz and Roberts (Am J Cardiol, 1973; 31: 623–626) classified the quadricuspid semilunar valve into 7 types (A–G). According to this classification, our patient had the commonest variant — type G, with 4 different cusps. Severe regurgitation due to cusp malcoaptation is common in type G, but our patient had mild aortic regurgitation. QAV may be found as an isolated lesion, or an association with other congenital anomalies, including ventricular septal defect, hypoplasia of anterior mitral leaflet, subaortic fibromuscular stenosis, patent ductus arteriosus, pulmonary artery stenosis, supraventricular arrhythmias, complete atrioventricular block, and anomalies of coronary arteries. For this reason, although TTE is the method of choice in the diagnosis of QAV, TEE should be performed to investigate whether other congenital anomalies are associated with QAV.

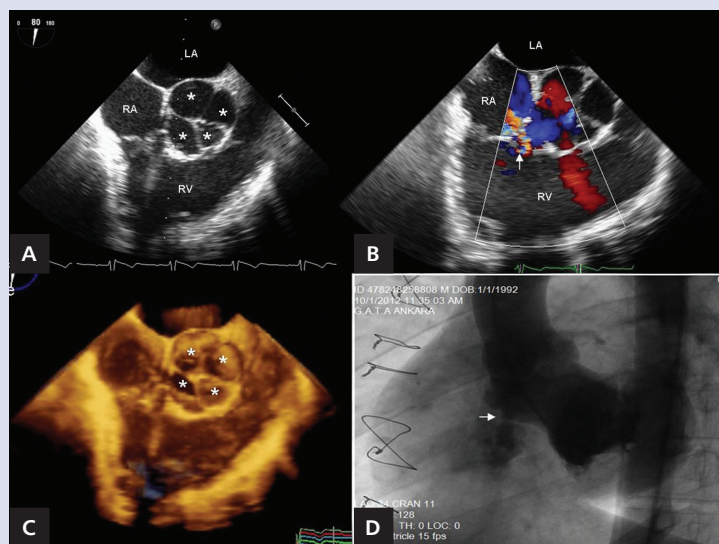


Figure 1. Two- and three-dimensional transoesophageal echocardiography (2D and 3D TEE) revealed the aortic valve consisted of 4 leaflets of differing sizes (A). 2D colour Doppler TEE displayed a mild aortic regurgitation and a ventricular septal defect (B). 3D TEE full volume view also revealed quadricuspid aortic valve (C). Left ventriculography demonstrated a membranous ventricular septal defect (D); LA — left atrium; RA — right atrium; RV — right ventricle; asterisk — aortic cusps; arrow — ventricular septal defect

Address for correspondence:

Sevket Balta, MD, Gulhane Medical Faculty, Tevfik Saglam, 06018 Ankara, Turkey, tel: +903123044281, e-mail: drsevketb@gmail.com

Conflict of interest: none declared