

The natural history of thromboembolic pulmonary hypertension. Since when is it chronic? A proposal of an algorithm for the diagnosis and treatment

Historia naturalna zakrzepowo-zatorowego nadciśnienia płucnego. Od kiedy jest ono przewlekłe? Propozycja algorytmu postępowania diagnostyczno-terapeutycznego

Jerzy Lewczuk^{1,2}, Renata Romaszkiwicz¹, Lucyna Lenartowska¹, Piotr Piszko¹, Jacek Jagas¹, Małgorzata Nowak¹, Ewa Mroczek¹, Daniel Błaszczuk¹, Wojciech Witkiewicz^{1,3}, Krzysztof Wrabec¹

¹Cardiology Ward, Provincial Specialist Hospital, Research and Development Centre, Wrocław, Poland

²Faculty of Health Sciences, Wrocław Medical University, Wrocław, Poland

³Faculty of Dentistry, Wrocław Medical University, Wrocław, Poland

INTRODUCTION

The diagnosis of chronic thromboembolic pulmonary hypertension (CTEPH) requires an objective demonstration of two components of the disease: pulmonary hypertension in haemodynamic studies of the pulmonary circulation (mean pulmonary arterial pressure [MPAP] \geq 25 mm Hg) and thromboembolic changes in imaging studies. Although the aetiology and pathogenesis of CTEPH has not yet been completely elucidated, the association between a previous diagnosis of acute pulmonary embolism (APE) can be demonstrated in up to about 50% of the cases. CTEPH is, however, a very rare consequence of diagnosed and treated APE. Its incidence is estimated at 0.1–0.5% [1], although, according to Pengo et al. [2], it may be even up to 3.8%.

HOW TO MONITOR PATIENTS WHO HAVE SUFFERED APE IN ORDER NOT TO MISS CTEPH?

The monitoring of anatomical lesions in the pulmonary vessels and of the pulmonary haemodynamics in patients who have suffered an episode of APE with pulmonary hypertension provides evidence that both of the above pathological components of CTEPH behave in a different and non-parallel manner in individual patients. In the first 6 weeks after the embolic episode resolution of changes in the follow-up computed tomography scan is seen in a mere 32% of the patients [3], while pulmonary blood pressure normalises in half that time in as many as about 90% of the patients [4]. The persistence of residual embolic

changes in imaging studies can be expected in 57% of the patients at 6 months and 52% of the patients at 11 months after the episode of APE [5], which is in stark contrast to the very low prevalence of CTEPH. This suggests that there is no need to monitor post-APE residual embolic lesions using imaging techniques in order to identify patients at risk of CTEPH [6].

It seems, however, justified to monitor pulmonary blood pressure values in these patients. In the past, at facilities where pulmonary angiography was the principal tool for the diagnosis of APE, pulmonary blood pressure values during an APE episode were determined “by the way” during concomitant pulmonary haemodynamic study. Now, however, that this role has been taken over by imaging studies that no longer require pulmonary artery catheterisation, routine invasive measurement of pulmonary pressures — although it is the only method that provides fully reliable measurements — can no longer be recommended. Pulmonary pressure should initially be estimated by non-invasive methods by echocardiography, an imaging modality in which more and more advanced equipment is available. By measuring the pressure gradient across the tricuspid valve one can calculate pulmonary artery systolic pressure (PASP) from the modified Bernoulli formula. Alternatively, other echocardiographic signs suggestive of pulmonary hypertension are looked for. These data, obtained from the echocardiogram, form the basis of the current ESC recommendations for estimating the presence of pulmonary hypertension (Table 1). They distinguish the following categories: pulmonary

Address for correspondence:

Prof. Jerzy Lewczuk, Cardiology Ward, Provincial Specialist Hospital, Research and Development Centre, ul. Kamińskiego 73a, 51–124 Wrocław, Poland, tel: +48 71 327 03 28, fax: +48 71 325 39 44, e-mail: lewczuk@wssk.wroc.pl

Received: 12.11.2012

Accepted: 23.01.2013

Copyright © Polskie Towarzystwo Kardiologiczne

Table 1. Simplified criteria of probability of pulmonary hypertension according to ESC [7] assuming a normal right atrial pressure of 5 mm Hg

Pulmonary hypertension unlikely	PASP \leq 36 mm Hg and no additional echocardiographic variables suggestive of pulmonary hypertension
Pulmonary hypertension possible	PASP \leq 36 mm Hg but presence of additional echocardiographic variables suggestive of pulmonary hypertension or PASP 37–50 mm Hg with/without additional echocardiographic variables suggestive of pulmonary hypertension
Pulmonary hypertension likely	PASP $>$ 50 mm Hg with/without additional echocardiographic variables suggestive of pulmonary hypertension

hypertension unlikely (PASP \leq 36 mm Hg and no additional echocardiographic variables suggestive of pulmonary hypertension), pulmonary hypertension possible (either PASP \leq 36 mm Hg with additional echocardiographic variables suggestive of pulmonary hypertension or PASP of 37–50 mm Hg with or without additional echocardiographic variables suggestive of pulmonary hypertension) and pulmonary hypertension likely (PASP $>$ 50 mm Hg with or without additional echocardiographic variables suggestive of pulmonary hypertension) [7]. The above echocardiographic data are also necessary in order to estimate the risk of in-hospital/30-day mortality in a patient with APE [8].

A PROPOSAL OF AN ALGORITHM FOR THE DIAGNOSIS AND TREATMENT OF CTEPH (FIG. 1)

Can the value of pulmonary pressure determined during an APE episode be predictive of future development of CTEPH? Numerous observational studies provide evidence that normal pulmonary pressure in this period indicates that this is not possible, provided the APE does not recur. Grifoni et al. [9] conducted an observational study in which they found no pulmonary hypertension on follow-up echocardiography at discharge in any of the 155 patients admitted with APE without the signs of pulmonary hypertension. Pulmonary hypertension did not develop in any of these patients over 1 year of echocardiographic follow-up in patients with APE and baseline PASP $<$ 40 mm Hg investigated by Ribeiro et al. [10] and at our facility [11]. It therefore seems that patients with APE but without the signs of pulmonary hypertension in the baseline echocardiogram do not need to be monitored for pulmonary hypertension in the future, and the duration of anticoagulant treatment should be determined on the basis of the current recommendations for the management of APE [8]. It should be emphasised that a sufficiently long

duration of anticoagulation markedly decreases the risk of APE recurrences. Although the assessment of the impact of recurrences on the appearance or worsening of pulmonary hypertension in patients on anticoagulation varies [10–12], the risk of pulmonary hypertension during an APE recurrence largely increases when anticoagulation is discontinued [13].

Further echocardiographic monitoring of pulmonary pressure seems necessary in patients with APE and “likely” pulmonary hypertension but also in those in whom pulmonary hypertension is considered “possible” (i.e. even when PASP does not exceed 37 mm Hg but other signs suggestive of pulmonary hypertension are present). Adopting such a cautious procedure seems justified, so that patients who might develop CTEPH in the future are not “missed”, given the fact that pulmonary pressure is monitored using echocardiography, i.e. a diagnostic method that is less reliable than haemodynamic studies. It is commonly recognised that echocardiographically determined pulmonary pressure values may be underestimated (although this is usually the case with higher values) [14] and that there are discrepancies as to the upper limit of normal PASP [15]. Serial echocardiographic measurements of pulmonary pressure in patients with a recent history of an embolic event show that in most patients, whatever the baseline value, the pressure starts to decrease after initiation of anticoagulation [10, 11, 13] and that the pulmonary pressure reduction does not seem to be greater after using fibrinolytic treatment [10, 11]. However, the higher the baseline PASP, the higher the risk of non-normalisation [10, 11, 13]. Patients with baseline PASP values exceeding 50 mm Hg are at a 3-fold higher risk of chronic pulmonary hypertension [10]. On the other hand, pulmonary hypertension may completely resolve even in patients with the so-called subacute massive pulmonary embolism, which refers to APE recurrences that last 2–8 weeks and in which pre-anticoagulation PASP usually exceeds 70 mm Hg [16, 17].

Pulmonary pressure should also be monitored echocardiographically in patients in whom CTEPH develops according to another scenario than that in patients who have been diagnosed with APE and who have received treatment for it. In a study by Lang [18], 63% of the 142 consecutive patients with CTEPH the disease had not started with the clinical manifestations of venous thromboembolism. These CTEPH cases might have developed as a result of undiagnosed and untreated clinically overt, subclinical or latent episodes of APE [19]. Meignan et al. [20] demonstrated that latent pulmonary embolism may develop in up to 50% of the patients with proximal deep vein thrombosis. In these patients, the time between the undiagnosed embolic episode and the development of the first clinical manifestations (the so-called “honeymoon period”) may last many years [21]. It is not until the patient experiences increasing exertional dyspnoea and reduced exercise tolerance and until echocardiography shows signs of pulmonary hypertension that further evaluation of

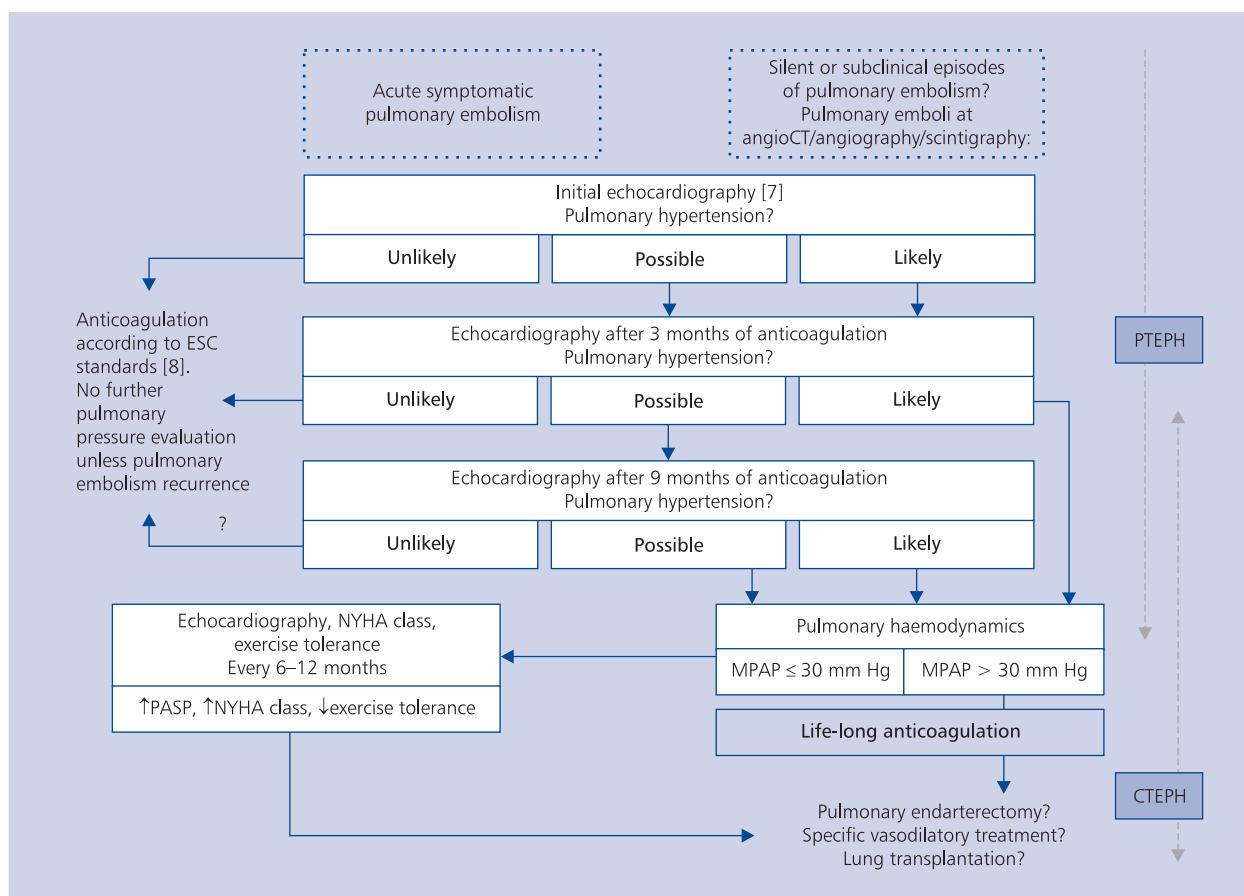


Figure 1. A proposal of an algorithm for the diagnosis and treatment of thromboembolic pulmonary hypertension; CT — computed tomography; CTEPH — chronic thromboembolic pulmonary hypertension; MPAP — mean pulmonary artery pressure; NYHA — The New York Heart Association; PASP — pulmonary artery systolic pressure; PTEPH — persistent thromboembolic pulmonary hypertension

the latter is initiated [22]. If the imaging studies performed in these patients show thrombotic changes, then the presence of symptoms associated with pulmonary hypertension for more than 8 weeks coupled with the absence of recurrent embolisms during this period (which principally rules out the diagnosis of the so-called subacute massive pulmonary embolism) allows one to establish the diagnosis of CTEPH. However, our observations show that despite many years of a history suggestive of incipient pulmonary hypertension it should not be considered chronic, establishing the preliminary diagnosis of CTEPH, as after the initiation of anticoagulation the pressure decreases and even normalises [22, 23]. This is an argument to support the use of the same diagnostic algorithm in this group of patients as in patients with pulmonary hypertension following APE.

So what should we call pulmonary hypertension that persists after a clinically overt or latent episode of APE but normalises after the initiation of anticoagulation in most of the patients? It seems that it should be referred to as persistent thromboembolic pulmonary hypertension

(PTEPH) [12, 13]. Only in certain cases, PTEPH develops into CTEPH. As may be concluded from the serial echocardiographic measurements performed by Ribeiro et al. [10], PTEPH starts to develop into CTEPH on the sixth week after initiation of anticoagulant treatment. Around that time, in most patients, pulmonary hypertension enters the stabilisation phase without further decreasing in the later period. The presence of the signs of pulmonary hypertension in a follow-up echocardiogram after this period warrants the suspicion of CTEPH and a referral of these patients to reference centres where it is possible to perform haemodynamic studies of the pulmonary circulation to reliably confirm the diagnosis. The clinical experience suggests, however, that the follow-up echocardiography and, possibly, also the haemodynamic study should be performed after 3 months rather than 6 weeks. In this case, if CTEPH is diagnosed and the patient is qualified for pulmonary endarterectomy, 3-month anticoagulation is advocated by cardiac surgeons to avoid perioperative embolic recurrences [24]. The correctness of the selection of this period

is confirmed by clinical observations, which also indicate that referrals for haemodynamic studies should be made in the case of those patients whose echocardiograms obtained at 3 months into anticoagulation reveal “likely” pulmonary hypertension with a PASP exceeding 50 mmHg [10, 11]. De Perrot et al. [11] showed progression of PASP in these patients over the further 6–12 months. This progression, provided there are no recurrences of APE, does not seem to occur in patients with “possible” pulmonary hypertension in follow-up echocardiography performed after 3 months of anticoagulation [12]. In some of these patients, further observation revealed a decrease or even normalisation of pulmonary hypertension [11, 13]. It therefore seems justified to uphold the diagnosis of PTEPH in patients with “possible” pulmonary hypertension following 3 months of anticoagulation. These patients should continue anticoagulation and undergo a follow-up echocardiogram 6 months later. The persistence of the signs of pulmonary hypertension (“likely” or “possible”) after this period should prompt one to verify it in a haemodynamic study of the pulmonary circulation. However, the absence of echocardiographic signs of pulmonary hypertension (unlikely pulmonary hypertension) merely requires anticoagulation to be performed in accordance with the principles of secondary prevention of thrombosis. These patients, provided they do not develop recurrent embolisms, most likely do not need to have their pulmonary pressure monitored any further.

As mentioned above, pulmonary hypertension can only be confirmed by invasive haemodynamic examination of the pulmonary circulation. All those patients, once the diagnosis has been confirmed, require indefinite anticoagulant therapy. The demonstration of proximal embolic lesions, accessible to the cardiac surgeon, in pulmonary angiography and/or other imaging studies allows to qualify patients with confirmed pulmonary hypertension for pulmonary endarterectomy, which is the treatment of choice and leads to spectacular clinical outcomes [25]. Patients who are not eligible for this procedure may be offered specific vasodilator treatment or lung and heart transplantation. A proposal of an algorithm for the management of patients with confirmed CTEPH has been presented elsewhere [26]. Patients most eligible for urgent pulmonary endarterectomy include those with the worst prognosis in whom MPAP exceeds 40 mm Hg [27]. Clinical observations of patients with moderate pulmonary hypertension, with MPAP exceeding 30 mm Hg, who refused to undergo surgery indicate that the clinical course of these patients varies but is generally unfavourable [28, 29]. For this reason this group of patients should be qualified for pulmonary endarterectomy [30], and the experiences of Polish and foreign centres suggest to perform the procedure in patients in a low NYHA functional class and coexistent peripheral embolic lesions [25, 30, 31]. In these patients, pulmonary hypertension, often worsens

despite anticoagulation with time and decreases only in the terminal stage of right ventricular dysfunction.

However, not all the patients with haemodynamically confirmed pulmonary hypertension and with embolic lesions accessible to the cardiac surgeon must undergo surgery. Observations of patients with mild CTEPH and a MPAP not exceeding 30 mm Hg and with the so-called borderline pulmonary hypertension (MPAP 21–24 mm Hg) indicate that long-term prognosis is favourable [23, 28, 29], and a prospective 3-year observation of 10 such anticoagulated patients at our facility has shown a reduction in pulmonary pressure, improvement of the NYHA functional class and improvement of exercise tolerance in all of these patients [23]. In 9 of these patients, pulmonary hypertension was assessed echocardiographically 3 years later as being “unlikely”, although this has not been verified with the reliable haemodynamic study. It seems that these patients should be regularly assessed echocardiographically and clinically and referred for surgery only if their pulmonary pressure rises, their NYHA functional class worsens, their exertional dyspnoea exacerbates or their exercise tolerance decreases.

CONCLUSIONS

Pulmonary hypertension, which often accompanies overt embolic episodes or develops in the course of clinically latent form of this disease, rapidly decreases and usually resolves within 6 weeks after initiation of anticoagulation. However, the course of this period, which may be referred to as persistent thromboembolic pulmonary hypertension (PTEPH), varies from patient to patient and is often prolonged in patients with high baseline pulmonary hypertension. PTEPH only occasionally develops into chronic thromboembolic pulmonary hypertension (CTEPH). In our diagnostic and therapeutic algorithm, based on nearly 20 years of published observations, the strategic role in the monitoring of pulmonary hypertension — from the initial examination till the resolution or establishment of chronicity of pulmonary hypertension — has been attributed to echocardiography. Echocardiographic suspicion of CTEPH established after at least 3 months of anticoagulation must be confirmed by an invasive haemodynamic study of the pulmonary circulation. All the patients with CTEPH require indefinite anticoagulation therapy. Demonstration of a MPAP exceeding 30 mm Hg suggests that these patients should undergo surgery and/or drug treatment.

The natural history of thromboembolic pulmonary hypertension presented above, which has formed the basis for the development of an original algorithm for the diagnosis and treatment, should facilitate the decision to refer patients with suspected CTEPH to reference centres and those with confirmed CTEPH and accessible embolic lesions for pulmonary endarterectomy. It should also prevent patients with PTEPH from undergoing surgery.

The study has been part of the project “WROVASC — Integrated Centre for Cardiovascular Medicine” funded by the European Regional Development Fund and by the state budget — Operational Programme ‘Innovative Economy’ 2007–2013.

Conflict of interest: none declared

References

- Moser KM, Auger WR, Fedullo PF. Chronic major-vessel thromboembolic pulmonary embolism. *Circulation*, 1990; 81: 1735–1742.
- Pengo V, Lensing AW, Prins MH et al. Thromboembolic Pulmonary Hypertension Study Group. Incidence of chronic thromboembolic pulmonary hypertension after pulmonary embolism. *N Engl J Med*, 2004; 350: 2257–2264.
- van Rossum AB, Pattynama PM, Tjin AT et al. Spiral CT appearance of resolving clots at 6 week follow-up after acute pulmonary embolism. *J Comput Assist Tomogr*, 1998; 22: 413–417.
- Fedullo PF, Auger WR, Kerr KM et al. Chronic thromboembolic pulmonary hypertension. *N Engl J Med*, 2001; 45: 1465–1472.
- Nijkeuter M, Hovens MM, Davidson BL et al. Resolution of thromboemboli in patients with acute pulmonary embolism: a systematic review. *Chest*, 2006; 129: 192–197.
- Mroczek E, Lewczuk J. Co się dzieje w naczyniach płucnych u antykoagulowanego chorego po ostrym incydencie zatorowym? Znaczenie kliniczne zmian anatomicznych i hemodynamicznych. Jak postępować? *Kardiologia Polska*, 2012; 70: 401–404.
- Task Force for Diagnosis and Treatment of Pulmonary Hypertension of European Society of Cardiology (ESC) and European Respiratory Society (ERS) endorsed by International Society of Heart and Lung Transplantation. Guidelines for the diagnosis and treatment of pulmonary hypertension. *Eur Heart J*, 2009; 30: 2493–2537.
- Task Force for Diagnosis and Management of Acute Pulmonary Embolism of the European Society of Cardiology (ESC). *Eur Heart J*, 2008; 29: 2276–2315.
- Grifoni S, Vanni S, Magazzini S et al. Association of persistent right ventricular dysfunction at hospital discharge after acute pulmonary embolism with recurrent thromboembolic events. *Arch Intern Med*, 2006; 166: 2151–2156.
- Ribeiro A, Lindmarker P, Johnsson H et al. Pulmonary embolism. One-year follow up with echocardiography doppler and five year survival. *Circulation*, 1999; 99: 1325–1330.
- Romaszkiewicz R, Lewczuk J, Piszko P et al. Wpływ przedłużonej do roku profilaktyki przeciwzakrzepowej na zachowanie się nadciśnienia płucnego i na możliwość rozwinięcia się przewlekłego zakrzepowo-zatorowego nadciśnienia płucnego po incydencie ostrej zatorowości. *Pol Przegl Kardiol*, 2005; 7: 399–403.
- de Perrot M, Fadel E, McRae K et al. Evaluation of persistent pulmonary hypertension after acute pulmonary embolism. *Chest*, 2007; 132: 780–785.
- Soyza NDB, Murphy ML. Persistent post-embolic pulmonary hypertension. *Chest*, 1972; 62: 665–668.
- Brecker SJ, Gibbs JS, Fox KM et al. Comparison of Doppler derived hemodynamic variables and simultaneous high fidelity pressure measurements in severe pulmonary hypertension. *Br Heart J*, 1994; 72: 384–389.
- McQuillan BM, Pickard MH, Leavit M et al. Clinical correlates and reference intervals for pulmonary artery systolic pressure among echocardiographically normal subjects. *Circulation*, 2001; 104: 2797–2802.
- Kasper W, Geibel A, Tiede N et al. Distinguishing between acute and subacute massive pulmonary embolism by conventional and Doppler echocardiography. *Br Heart J*, 1993; 70: 352–356.
- Sutton GC, Hall RJC, Kerr IH. Clinical course and late prognosis of treated subacute massive, acute minor, and chronic pulmonary thromboembolism. *Br Heart J*, 1977; 39: 1135–1142.
- Lang IM. Chronic thromboembolic pulmonary hypertension: not so rare after all. *N Engl J Med*, 2004; 350: 2236–2238.
- Ryu JH, Olson EJ, Pellikka PA. Clinical recognition of pulmonary embolism: problem of unrecognized and asymptomatic cases. *Mayo Clin Proc*, 1998; 73: 873–879.
- Meignan M, Rosso J, Gauthier H et al. Systematic lung scans reveal a high frequency of silent pulmonary embolism in patients with proximal deep venous thrombosis. *Arch Intern Med*, 2000; 160: 159–164.
- Moser KM., Auger WR, Fedullo PF. Chronic major-vessel thromboembolic pulmonary embolism. *Circulation*, 1990; 81: 1735–1742.
- Romaszkiewicz R, Lewczuk J, Piszko P et al. Chronic thromboembolic pulmonary embolism not preceded by clinical thromboembolic event: clinical, echocardiographic and haemodynamic course. *Kardiologia Polska*, 2011; 69: 58–60.
- Romaszkiewicz R, Lewczuk J, Piszko P et al. Clinical course of unoperated mild chronic thromboembolic pulmonary hypertension. *Kardiologia Polska*, 2011; 69: 438–443.
- Klepsetko W, Mayer E, Sandoval J et al. Interventional and surgical modalities of treatment for pulmonary arterial hypertension. *J Am Coll Cardiol*, 2004; 43 (suppl. S): 73S–80S.
- Madani MM, Auger WR, Pretorius V et al. Pulmonary endarterectomy: recent changes in a single institution’s experience of more than 2,700 patients. *Ann Thorac Surg*, 2012; 94: 97–103.
- Rubin LJ, Hoepfer MM, Klepsetko W et al. Current and future management of chronic thromboembolic pulmonary hypertension: from diagnosis to treatment responses. *Proc Am Thorac Soc*, 2006; 3: 601–607.
- Doyle RL, McCrory D, Channick RN et al. Surgical treatment/Interventions for pulmonary arterial hypertension. ACCP Evidence-based clinical practice guidelines. *Chest*, 2004; 126 (suppl. 1): 63S–71S.
- Lewczuk J, Piszko P, Jagas J et al. Prognostic factors in medically treated patients with chronic pulmonary embolism. *Chest*, 2001; 119: 818.
- Riedel M, Stanek V, Widimsky J et al. Long term follow-up of patients with pulmonary thromboembolism: late prognosis and evolution of hemodynamic and respiratory data. *Chest*, 1982; 81: 151–158.
- Kurzyna M, Torbicki A, Poloński L et al. Thrombo-embolic pulmonary hypertension—do not spoil a chance for effective surgery. *Kardiologia Polska*, 2011; 69: 875–878.
- Pepke-Zaba J, Delcroix M, Lang I et al. Chronic Thromboembolic Pulmonary Hypertension (CTEPH): Results From an International Prospective Registry. *Circulation*, 2011; 1: 1–9.