

Urgent invasive coronary strategy and mild induced hypothermia in patients with resuscitated sudden cardiac arrest

Pilna strategia infuzyjna i terapeutyczna hipotermia u chorych po nagłym zatrzymaniu krążenia

Marko Noc¹, Rihard Knafelj¹, Blaz Mrevlje²

¹Centre for Intensive Internal Medicine, University Medical Centre, Ljubljana, Slovenia

²Department of Cardiology, University Medical Centre, Ljubljana, Slovenia

INTRODUCTION

Sudden cardiac arrest (SCA) remains the leading cause of death in developed countries, with an annual incidence ranging from 36 to 81 events per 100,000 inhabitants. According to the findings of post mortems and immediate coronary angiography, significant coronary artery disease may be documented in more than 70% of patients suffering from SCA [1, 2]. Following initial cardiocerebral resuscitation in the field, the re-establishment of spontaneous circulation (ROSC) is achieved in 40% to 60% of patients who are subsequently transferred to the emergency department. Because of typical delays in the 'chain of survival', up to 80% of patients remain comatose despite ROSC which pinpoints post-resuscitation brain injury. Its severity may ultimately vary from mild disability to permanent vegetative state and cannot be accurately prognosticated on hospital admission. Only a minority of 'lucky losers' with prompt initiation of chest compression and defibrillation, which is usually the case if emergency medical personnel are already present when cardiac arrest occurs, regain consciousness immediately after ROSC.

'CONSCIOUS' SURVIVORS OF CARDIAC ARREST

The return of consciousness immediately after ROSC, as opposed to a coma, indicates the absence of significant post-resuscitation brain injury. If a coronary event is suspected, conscious survivors of cardiac arrest routinely undergo immediate coronary angiography and revascularisation similar to other patients with acute coronary syndrome (ACS) without preceding cardiac arrest (Fig. 1). Despite the fact that such patients have been typically excluded from major ACS interventional trials, we believe that in the absence of post-resuscitation brain injury, these studies can be safely extrapolated to this subpopulation of cardiac arrest patients. As a matter of fact,

these patients have an excellent prognosis which is comparable to, or even better than, ACS patients without cardiac arrest [3, 4]. Therefore, there is disagreement regarding immediate coronary angiography and percutaneous coronary intervention (PCI) if ST-elevation myocardial infarction (STEMI) or ACS without ST-elevation (NSTEMI/ACS) is suspected.

'COMATOSE' SURVIVORS OF CARDIAC ARREST

Unlike with conscious survivors of cardiac arrest, the brain represents another key target organ in comatose survivors. Since there was no effective treatment for post-resuscitation brain injury in the past, comatose survivors of cardiac arrest have never generated much interest among the interventional community despite the high prevalence of obstructive coronary disease. Instead, they typically died in the hospital or nursing home in a permanent vegetative state without their coronary anatomy being discovered. Treating coronaries if the patient does not wake up from a coma is indeed a futile intervention. The introduction of mild induced hypothermia in 2002 has undoubtedly revolutionised the field of the post-resuscitation treatment of comatose survivors and with 'number needed to treat' of seven represents one of the most effective interventions in modern cardiovascular medicine [5, 6]. Since comatose survivors of cardiac arrest undergoing hypothermia started to 'wake up' in subsequent days, more efforts were made to define and treat the cause of cardiac arrest. This led to comprehensive 'brain and heart' oriented post-resuscitation protocols with very consistent survival rates of between 55% and 65% [7–10]. Importantly, more than 80% of survivors achieve favourable neurological recovery and an extended lifespan [10]. This is in striking contrast with the 'pre-hypothermia era' as is evident also from our own registry of comatose survivors of out-of-hospital cardiac arrest (Fig. 2) [11].

Address for correspondence:

Marko Noc, MD, PhD, FESC, Centre for Intensive Internal Medicine, University Medical Centre, Zaloska 7, 1000 Ljubljana, Slovenia, tel/fax: +386 1 522 22 96, e-mail: marko.noc@mf.uni-lj.si

Received: 26.09.2012 Accepted: 31.10.2012

Copyright © Polskie Towarzystwo Kardiologiczne

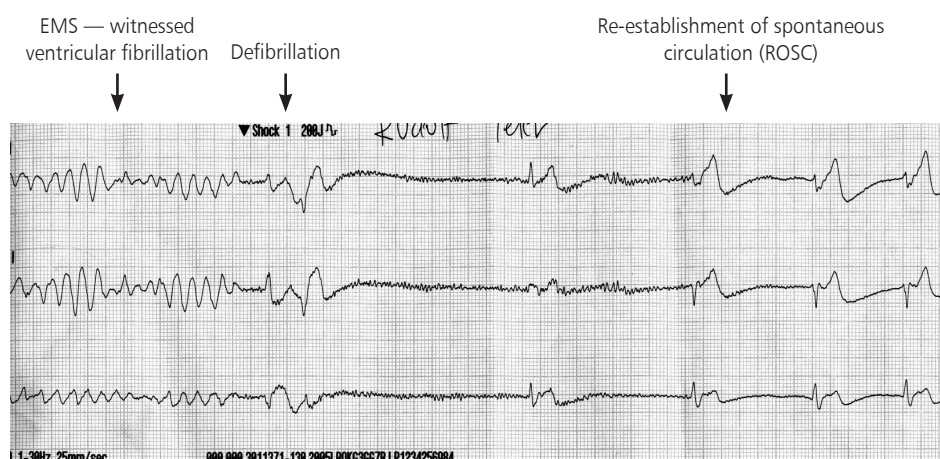


Figure 1. Example of a patient with sudden cardiac arrest on arrival of the emergency medical team which had been alerted 15 minutes earlier because of typical chest pain. The patient, who was defibrillated, immediately regained consciousness and was transported approximately 70 km to a '24/7' primary percutaneous coronary intervention centre for immediate interventional treatment; EMS — emergency medical staff

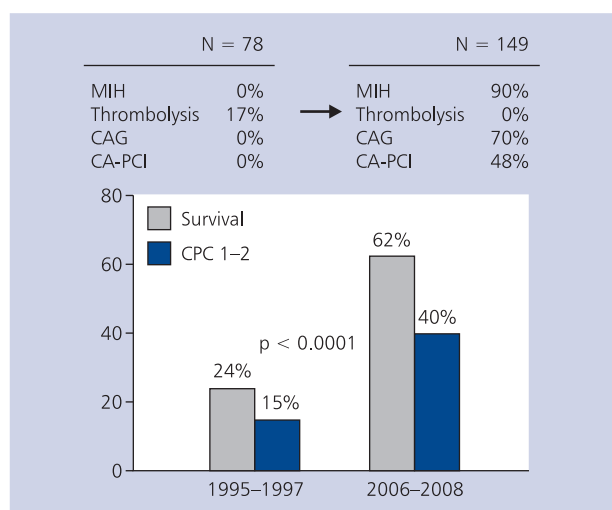


Figure 2. Survival of consecutive comatose patients after resuscitated out-of-hospital cardiac arrest before and after 'heart and brain' oriented post-resuscitation care at University Medical Centre, Ljubljana, Slovenia [11]; CA — cardiac arrest; CAG — coronary angiography; CPC 1-2 — cerebral performance category indicating good neurological recovery; MIH — mild induced hypothermia; PCI — percutaneous coronary intervention

Our protocol for the post-resuscitation treatment of comatose survivors of cardiac arrest is 'heart and brain' oriented and has as its cornerstones, hypothermia and immediate coronary intervention. This protocol is in this respect in accordance with the 2012 ESC guidelines on the management of acute myocardial infarction in patients presenting with ST-segment elevation [12]. It is very important to emphasise that the diagnosis and treatment of a coronary problem should never delay

the initiation and maintenance of hypothermia, because both interventions can be safely performed simultaneously [13, 14].

MILD INDUCED HYPOTHERMIA

There are several methods of inducing and maintaining post cardiac arrest hypothermia, including external cooling, cold fluid infusion, intravascular cooling and the recently introduced peritoneal lavage. These methods differ significantly in terms of their complexity, cooling rates and costs. Since none of the methods have been demonstrated to be superior in terms of clinical outcomes, we routinely use a very simple and cheap protocol which includes sedation/relaxation, cold fluid infusion and external cooling with ice packs (Fig. 3) [13]. We advise that the cooling protocol should be started when patients are on their way to our hospital.

IMMEDIATE CORONARY ANGIOGRAPHY

There is growing evidence on immediate coronary angiography after aborted SCA in the literature, concerning as many as 2,500 patients [10]. We have learned that immediate coronary angiography is feasible and safe also in the setting of resuscitated cardiac arrest. In the presence of STEMI in an early post-resuscitation electrocardiogram (ECG), acute thrombotic lesions may be found in up to 90% [4]. However, the absence of ST-elevation does not exclude obstructive or even thrombotic stenosis which may be present in 25% to 58% [2, 4, 15, 16]. Importantly, also a finding of normal coronary arteries or non-obstructive coronary disease is very useful because it triggers a search for alternative causes of cardiac arrest. We have developed an algorithm for the selection of patients for immediate coronary angiography, with a short stop at the emergency department for patients without ST elevation aimed to exclude obvious non-coronary causes

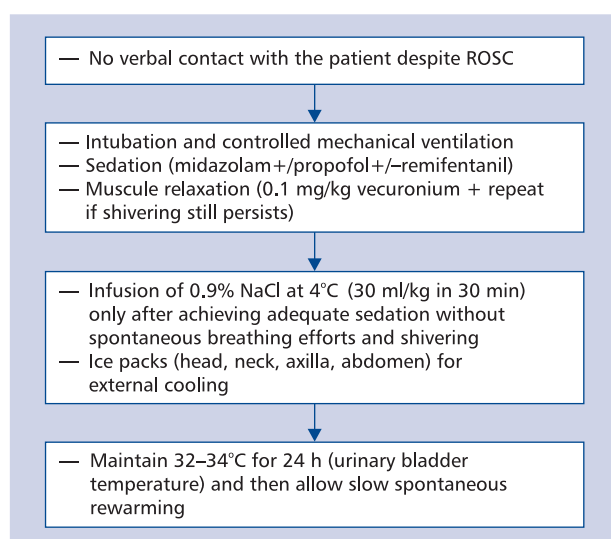


Figure 3. Protocol for mild induced hypothermia in comatose survivors of cardiac arrest at University Medical Centre, Ljubljana, Slovenia; ROSC — re-establishment of spontaneous circulation [12]

such as drowning, intoxication, cerebrovascular accident, pulmonary embolism and primary respiratory failure [4]. If this is not the case, we advise coronary angiography in the absence of unfavourable settings of cardiac arrest indicating very little likelihood of subsequent neurological recovery and in the absence of significant pre-arrest comorbidities (Fig. 4).

CARDIAC ARREST PCI

Immediate coronary angiography may be followed by what we call ‘cardiac arrest PCI’ (CA-PCI). Despite the fact that several registries [2, 8, 15] and a meta-analysis [10] have shown a sur-

vival benefit of CA-PCI, there has been no randomised trial and also no clear strategy of revascularisation. In most studies, the decision for CA-PCI has been based on the identification of obstructive stenosis which presumably caused the cardiac arrest without providing further angiographic information.

We believe that such information is very important when considering the heterogeneity of coronary artery disease ranging from stable obstructive to typical ACS lesions. An ACS lesion obviously represents a cause of cardiac arrest and successful CA-PCI. If we extrapolate major interventional ACS studies without preceding cardiac arrest, this will decrease the likelihood of recurrent cardiac arrest, improve haemodynamic stability, and reduce infarct size. Significant but angiographically stable obstructive stenosis may also be responsible for cardiac arrest by causing transient ischaemia and thereby triggering cardiac arrest. Hypothetical mechanisms, which may include plaque thrombosis with spontaneous reperfusion, coronary spasm or a decrease in perfusion pressure across the lesion or collaterals in case of sudden arterial hypotension, usually cannot be documented at coronary angiography. On the other hand, such lesions may also be only an ‘innocent bystander’ without a direct cause-and-effect relationship to cardiac arrest, which may have been triggered by another pathology such as post-infarction myocardial scarring [1]. Again, if we extrapolate knowledge from patients with stable coronary disease, PCI is mainly associated with symptom improvement without reduction in myocardial infarction and survival benefit compared to optimal medical therapy only. Since we are left with limited scientific evidence, we believe immediate CA-PCI should be primarily reserved for ACS lesions [4]. CA-PCI of additional obstructive lesions beyond the culprit may be reasonable if the patient remains haemodynamically unstable despite successful culprit intervention

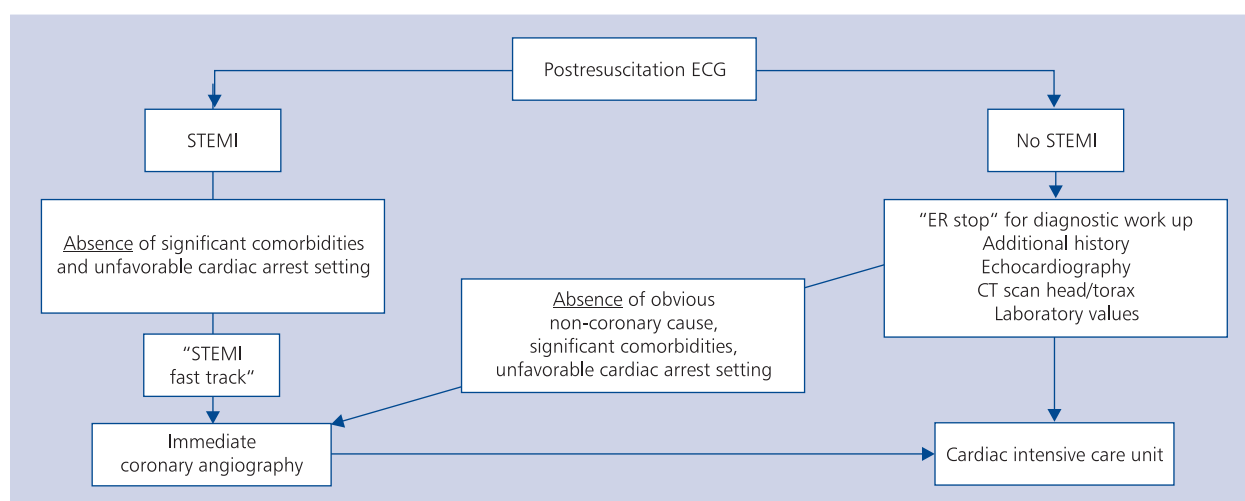


Figure 4. Selection of patients after resuscitated cardiac arrest for the strategy with immediate coronary angiography at University Medical Centre, Ljubljana, Slovenia; CT — computed tomography; ECG — electrocardiogram; ER — emergency room; STEMI — ST segment elevation myocardial infarction [4]

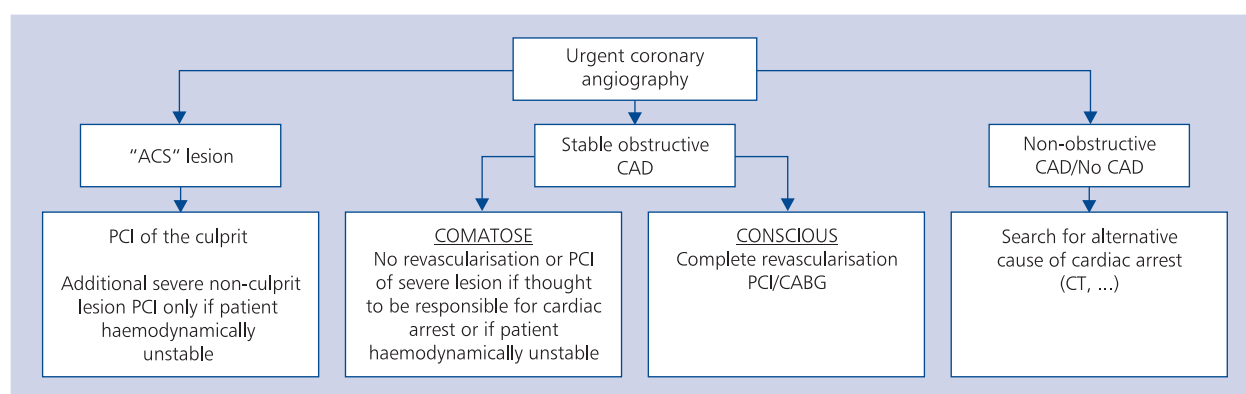


Figure 5. Revascularisation strategy after immediate coronary angiography in patients resuscitated from cardiac arrest at University Medical Centre, Ljubljana, Slovenia; ACS — acute coronary syndrome; CAD — coronary artery disease; CT — computed tomography; CABG — coronary artery bypass grafting; PCI — percutaneous coronary intervention [4]

and supportive treatment if we extrapolate findings from the landmark SHOCK trial which again excluded patients with cardiac arrest [17]. If this is not the case, we tend to postpone intervention to a more elective setting if the patient regains neurological function. To guide interventionalists, we have developed a simplified algorithm for revascularisation strategy which considers the extent of coronary disease, angiographic characteristics of lesions, haemodynamics, and the degree of post-resuscitation brain injury (Fig. 5) [4].

It is very important to emphasise that the angiographic success of CA-PCI is comparable to PCI in ACS without cardiac arrest, and is not likely to be compromised by ongoing hypothermia in comatose survivors of cardiac arrest [10, 13, 14]. Because of the significant proportion of patients with haemodynamic instability after ROSC, haemodynamic support with intraaortic balloon counterpulsation, and even with more effective assistance devices, is increasingly used also in comatose survivors if short time delays to ROSC argue for good neurological recovery. With successful CA-PCI and haemodynamic stabilisation of comatose survivors, we can ‘buy’ precious time for the completion of 24-hour hypothermia and possible neurological recovery during the subsequent days.

CALL FOR TEAMWORK AND SPECIALISED CARDIAC ARREST CENTRES

‘Heart and brain’ oriented post-resuscitation treatment is a team enterprise which includes prehospital emergency physicians, acute cardiac care physicians and interventional cardiologists. This is best achieved by upgrading the existing ‘24/7’ primary PCI network with ‘hypothermia-CA-PCI’ fast track for patients with resuscitated cardiac arrest and concentrating these patients in highly specialised tertiary centres. The results of those who have done this [4, 7–10] should also be seen as a ‘wake up call’ for the interventional cardiologist to become an essential part of the post-resuscitation team.

Conflict of interest: none declared

References

- Davies MJ. Anatomic features in victims of sudden coronary death: coronary artery pathology. *Circulation*, 1992; 85 (suppl. 1): 19–24.
- Spaulding CM, Joly LM, Rosenberg A et al. Immediate coronary angiography in survivors of out-of hospital cardiac arrest. *N Engl J Med*, 1997; 336: 1629–1633.
- Gorjup V, Radsel P, Kocjancic ST et al. Acute ST-elevation myocardial infarction after successful cardiopulmonary resuscitation. *Resuscitation*, 2007; 72: 379–385.
- Radsel P, Knafelj R, Kocjancic S et al. Angiographic characteristics of coronary disease and postresuscitation electrocardiograms in patients with aborted cardiac arrest outside a hospital. *Am J Cardiol*, 2011; 108: 634–638.
- The Hypothermia After Cardiac Arrest (HACA) study group. Mild therapeutic hypothermia to improve the neurological outcome after cardiac arrest. *N Engl J Med*, 2002; 346: 549–556.
- Bernard SA, Gray TW, Buist MD et al. Treatment of comatose survivors of out-of-hospital cardiac arrest with induced hypothermia. *N Engl J Med*, 2002; 346: 557–563.
- Sunde K, Pytte M, Jacobsen D et al. Implementation of a standardized treatment protocol for post resuscitation care after out of hospital cardiac arrest. *Resuscitation*, 2007; 73: 29–39.
- Stub D, Hengel C, Chan W et al. Usefulness of cooling and coronary catheterization to improve survival in out-of-hospital cardiac arrest. *Am J Cardiol*, 2011; 107: 522–527.
- Tomte O, Andersen GO, Jacobsen D et al. Strong and weak aspects of an established post-resuscitation treatment protocol: a five year observational study. *Resuscitation*, 2011; 82: 1186–1193.
- Kern KB. The importance of invasive interventional strategies in resuscitated patients following sudden cardiac arrest. *Interv Cardiol*, 2011; 3: 649–661.
- Tadel Kocjancic S, Radsel P, Knafelj R et al. Improved hospital outcome of comatose survivors of cardiac arrest of presumed cardiac origin. *Eur Heart J*, 2010; 12: F123–F123 (abstract).
- Steg PG, James SK, Atar D et al. ESC Guidelines for the management of acute myocardial infarction in patients presenting with ST-segment elevation: the Task Force on the management of ST-segment elevation acute myocardial infarction of the European Society of Cardiology (ESC). *Eur Heart J*, 2012 [Epub ahead of print].
- Knafelj R, Radsel P, Ploj T et al. Primary percutaneous coronary intervention and mild induced hypothermia in comatose survivors of ventricular fibrillation with ST-elevation acute myocardial infarction. *Resuscitation*, 2007; 74: 227–234.
- Wolfrum S, Pierau C, Radke PW et al. Mild therapeutic hypothermia in patients after out-of-hospital cardiac arrest due to acute ST-segment elevation myocardial infarction undergoing immediate percutaneous coronary intervention. *Crit Care Med*, 2008; 36: 1780–1786.
- Anyfantakis ZA, Baron G, Aubry P et al. Acute coronary angiographic findings in survivors of out-of-hospital cardiac arrest. *Am Heart J*, 2009; 157: 312–318.
- Dumas F, Cariou A, Manzo-Silberman S et al. Immediate percutaneous coronary intervention is associated with better survival after out-of-hospital cardiac arrest. Insights from the PROCAT registry. *Circ Cardiovasc Interv*, 2010; 3: 200–207.
- Hochman JS, Sleeper LA, Webb JG et al. Early revascularization in acute myocardial infarction complicated with cardiogenic shock. SHOCK Investigators. Should we emergently revascularize occluded coronaries for cardiogenic shock. *N Engl J Med*, 1999; 341: 625–634.