

# Incidental diagnosis of unicuspid aortic valve in an asymptomatic adult

Przypadkowe rozpoznanie jedнопłatkowej zastawki aortalnej u bezobjawowego dorosłego

Marcin Fijałkowski<sup>1</sup>, Miłosz Jaguszewski<sup>1,4</sup>, Joanna Pieńkowska<sup>2</sup>, Jadwiga Fijałkowska<sup>2</sup>, Jan Rogowski<sup>3</sup>, Andrzej Rynkiewicz<sup>1</sup>

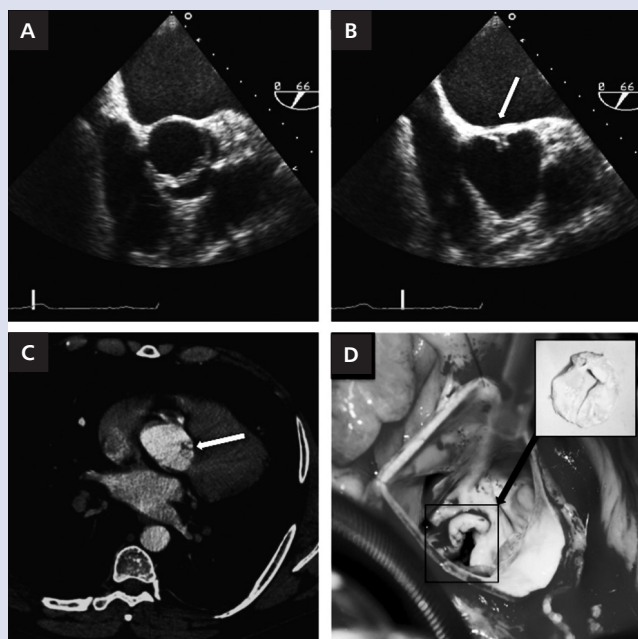
<sup>1</sup>First Department of Cardiology, Medical University of Gdansk, Gdansk, Poland

<sup>2</sup>Department of Radiology, Medical University of Gdansk, Gdansk, Poland

<sup>3</sup>Department of Cardiosurgery, Medical University of Gdansk, Gdansk, Poland

<sup>4</sup>Cardiovascular Centre Cardiology, University Hospital of Zurich, Zurich, Switzerland

A 38 year-old male with no cardiovascular history was referred for computed tomography (CT) of chest aorta due to prominence of the right cardiac contour in prophylactic chest X-ray examination required by his employer. Initially, transoesophageal echocardiography (TEE) was performed and revealed abnormal aortic valve morphology with a posteriorly positioned commissural attachment and ascending aorta aneurysm coupled by a moderate aortic regurgitation without valve orifice stenosis (Fig. 1A, B). With the suspicion of unicuspid aortic valve (UAV) and the diagnosis of ascending aorta aneurysm, he was referred for further cardiovascular evaluation. Physical examination revealed a regular heart rate with a mild diastolic murmur at the right upper sternal border, blood pressure of 125/83 mm Hg and heart rate 68 bpm. Scheduled 64-slice multi-detector CT (MDCT) confirmed dilatation of ascending aorta up to 53 mm and UAV with only one distinctive commissure (Fig. 1C). The Bentall de Bono procedure was performed and a size 29 ATS aortic valved conduit was implanted (ATS Medical, Minneapolis, MN, USA). During surgery, the valve was found to be unicommisural and unicuspid without significant calcification and thickening (Fig. 1D). There were no postoperative complications and the patient made a full recovery. UAV is mainly discovered during surgery or autopsy and can be easily mistaken for a more common bicuspid aortic valve. Morphologic similarities between unicuspid and bicuspid valves in TEE can often provide diagnostic difficulties. The incidental finding in TEE or MDCT substantially affects further management, including Bentall procedure, ascending aorta surgery and aortic valve replacement, with the need for endocarditis prophylaxis.



**Figure 1.** Transoesophageal echocardiography: aortic valve in systole (A) and diastole (B), arrow indicates commissural attachment; Computed tomography picture, arrow indicates commissural attachment (C); Perioperative view after aortomy: unicommisural and unicuspid aortic valve (D)

#### Address for correspondence:

Marcin Fijałkowski, MD, PhD, 1<sup>st</sup> Department of Cardiology, Medical University of Gdansk, ul. Dębinki 7, 80-291 Gdańsk, Poland, tel: +48 58 349 25 04, e-mail: mfijałkowski@gumed.edu.pl

**Conflict of interest:** none declared