

Hemoptysis as the first sign of angiosarcoma — an extremely aggressive cardiac tumor

Aleksandra Cieplucha¹, Aleksandra Różycka², Deanna Rudiak², Supasin Watcharintrawut², Mehul Sharma², Aneta Klotzka¹, Adrian Gwizdała¹, Daria Keller¹, Agnieszka Katarzyńska-Szymańska¹, Przemysław Mitkowski¹

¹1st Department of Cardiology, Poznan University of Medical Sciences, Poznań, Poland

²1st International Student Scientific Group on Cardiovascular Medicine, Poznan University of Medical Sciences, Poznań, Poland

Correspondence to:

Aleksandra Cieplucha,
MD, PhD, FESC,
1st Department of
Cardiology,
Poznan University of
Medical Sciences,
Długa 1/2, 61-848 Poznań,
Poland,
phone: (+48) 618 549 146,
e-mail:
ola.cieplucha@gmail.com

Copyright by the
Author(s), 2021

Kardiologia Polska. 2021;
79 (5): 589-590;
DOI: 10.33963/KP.15920

Received:

February 3, 2021

Revision accepted:

March 16, 2021

Published online:

March 30, 2021

A 19-year-old male was admitted to the hospital with a two-month history of hemoptysis. Previously healthy, with no significant family history, he was initially examined for lung pathology. On admission, a chest X-ray showed disseminated consolidations in the lungs. Computed tomography showed subpleural opacities and multiple, bilateral solid nodules with ground-glass opacities (Figure 1A, 1B). The nodules were more dispersed in the peripheral lobules, which is suggestive of neoplastic spread [1]. The chest scans also showed an irregular mass in the right atrium. The patient was transferred to the cardiac surgery department. Transthoracic echocardiography (TTE) revealed a 70 × 45 mm heterogeneous lobulated tumor in the right atrium infiltrating the free wall of the right atrium, right ventricle, and tricuspid valve, suggestive of malignancy. Cardiac magnetic resonance demonstrated inhomogeneous late gadolinium enhancement of the mass infiltrating the pericardium (Figure 1C, 1D). Laboratory tests showed elevated D-dimer concentration, liver enzymes, and fibrinogen. Cancer biomarkers were within reference ranges. The most probable diagnosis was a primary cardiac neoplasm with metastatic spread; pulmonary lesions were highly suggestive of metastases of angiosarcoma. Surgical treatment was precluded due to the anatomical location and infiltration of the tumor. Biopsy of the lesion was necessary to implement any systemic treatment. Nevertheless, the patient refused this procedure and asked for discharge.

The patient was readmitted to the cardiology department two weeks later with severe dyspnea, weakness, and excessive hemoptysis. TTE confirmed enlargement of the tumor to 80 × 70 mm (Figure 1E, 1F). Due to hemoptysis

the patient required numerous blood transfusions and intensified pain therapy. Biopsy of the tumor was eventually performed and poorly differentiated angiosarcoma cells classified as G3 were found. The patient was immediately transferred to the oncological center to undergo palliative chemotherapy. During transport, his condition got worse and he was admitted directly to the Intensive Care Unit with a suspicion of pulmonary embolism. After 2 days the patient died due to multiple organ dysfunction and septic shock.

Cardiac angiosarcomas are a rare pathology with an average survival period of 7 months if diagnosed in the metastatic stage [2]. Lesions of the right heart have a poorer prognosis compared to those on the left. They are described as infiltrative, bulky, heterogeneous lobulated masses with areas of hemorrhage and necrosis on echocardiography [3]. Surgical resection is essential, and both complete and partial resection contribute to longer survival. Adjuvant chemotherapy is used due to frequent metastases and their efficacy in reducing tumor tissue. Combining surgical resection, chemotherapy and radiotherapy can extend survival time up to 3 years [4].

If the tumor is not resectable, biopsy and histopathological analysis are crucial to implementing systemic treatment. This case exemplifies that if angiosarcoma is suspected, the biopsy must not be postponed. The course of the disease is very aggressive with extensive progression in tumor mass seen after two weeks. A prompt diagnostic workup is of vital importance for the rapid implementation of targeted therapy and requires the involvement of a multi-specialist team [4, 5].

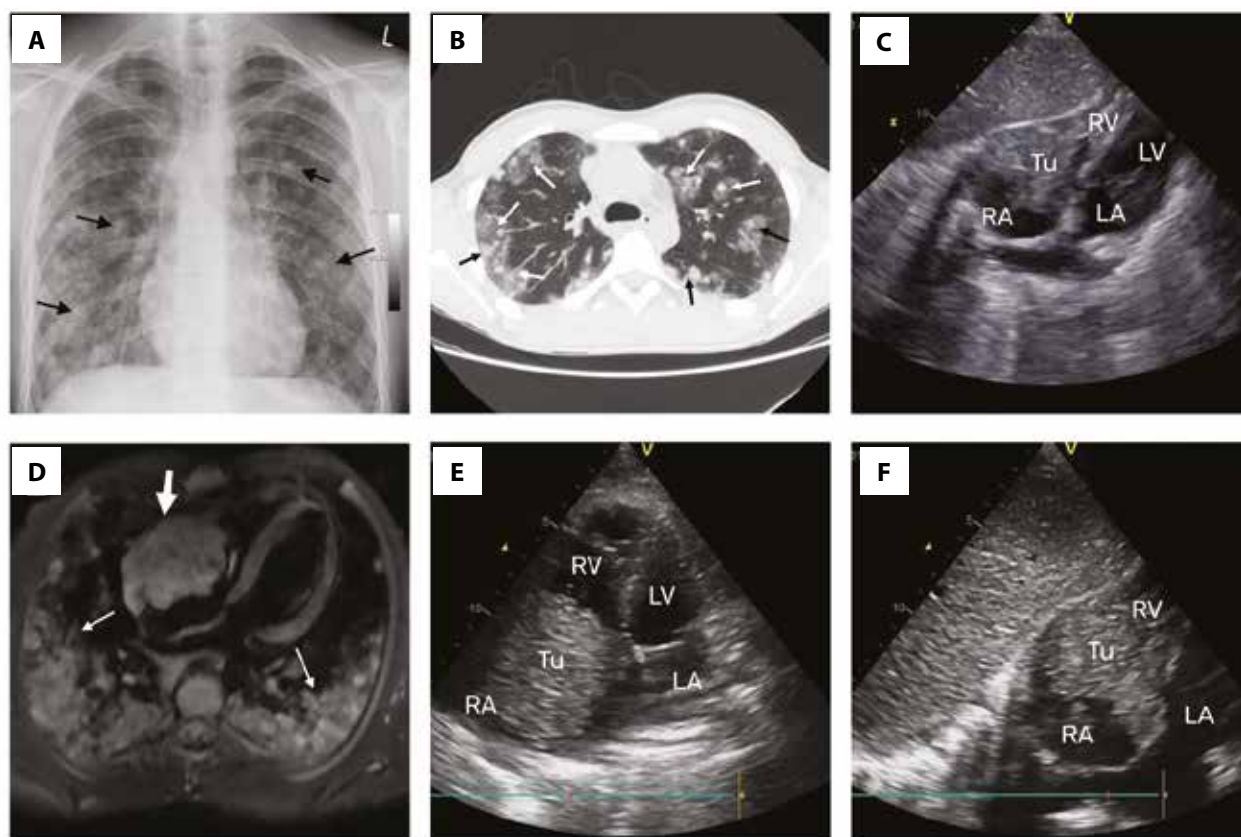


Figure 1. Multimodality imaging of cardiac angiosarcoma. **A.** X-ray of the lungs showing diffuse ground-glass opacities (black arrows). **B.** Computed tomography of the lungs showing ground-glass opacities in the center and periphery (white arrows) and subpleural opacifications (black arrows). **C.** Initial TTE, subcostal view showing a large right atrial tumor with a possible thrombus on the periphery. **D.** T1-weighted magnetic resonance imaging showing lesion in the right atrium of the heart (thick arrow) and metastatic lesions in both lungs (thin arrows). **E.** TTE after 2 weeks, apical 4-chamber view showing the tumor mass encroaching RA and infiltrating the free wall. **F.** TTE after 2 weeks, subcostal view, showing the enlargement of the tumor mass.

Abbreviations: LA, left atrium; LV, left ventricle; RA, right atrium; RV, right ventricle; TTE, transthoracic echocardiogram

Article information

Conflict of interest: None declared.

Open access: This article is available in open access under Creative Commons Attribution-Non-Commercial-No Derivatives 4.0 International (CC BY-NC-ND 4.0) license, allowing to download articles and share them with others as long as they credit the authors and the publisher, but without permission to change them in any way or use them commercially. For commercial use, please contact the journal office at kardiologiapolska@ptkardio.pl.

How to cite: Cieplucha A, Różycka A, Rudiak D, et al. Hemoptysis as the first sign of angiosarcoma — an extremely aggressive cardiac tumor. *Kardiol Pol.* 2021; 79(5): 589–590, doi: 10.33963/KP.15920.

REFERENCES

1. Wang H, Shi J, Liu H, et al. Clinical and diagnostic features of angiosarcoma with pulmonary metastases: A retrospective observational study. *Medicine (Baltimore)*. 2017; 96(36): e8033, doi: 10.1097/MD.0000000000008033, indexed in Pubmed: 28885371.
2. Truong PT, Jones SO, Martens B, et al. Treatment and outcomes in adult patients with primary cardiac sarcoma: the British Columbia Cancer Agency experience. *Ann Surg Oncol.* 2009; 16(12): 3358–3365, doi: 10.1245/s10434-009-0734-8, indexed in Pubmed: 19830494.
3. Mankad R, Herrmann J. Cardiac tumors: echo assessment. *Echo Res Pract.* 2016; 3(4): R65–R77, doi: 10.1530/ERP-16-0035, indexed in Pubmed: 27600455.
4. Patel SD, Peterson A, Bartczak A, et al. Primary cardiac angiosarcoma — a review. *Med Sci Monit.* 2014; 20: 103–109, doi: 10.12659/MSM.889875, indexed in Pubmed: 24452054.
5. Nartowicz S, Cieplucha A, Olasińska-Wiśniewska A, et al. Heartburn as the first symptom of rare cardiac tumor localization: is multimodality imaging a helpful approach? *Kardiol Pol.* 2021; 79(2): 211–212, doi: 10.33963/KP.15759, indexed in Pubmed: 33463995.