

# Surgical revascularization in STEMI patient after failed percutaneous coronary interventions with broken angioplasty wire protruding into the aortic root

Tomasz Urbanowicz<sup>1</sup>, Bartłomiej Perek<sup>1</sup>, Anna Ołasińska-Wiśniewska<sup>1</sup>, Włodzimierz Skorupski<sup>2</sup>, Marek Jemielity<sup>1</sup>

<sup>1</sup>Cardiac Surgery and Transplantology Department, Poznan University of Medical Sciences, Poznań, Poland

<sup>2</sup>Cardiology Department, Poznan University of Medical Sciences, Poznań, Poland

## Correspondence to:

Tomasz Urbanowicz,  
MD, PhD,  
Cardiac Surgery  
and Transplantology  
Department,  
Poznan University of  
Medical Sciences,  
Długa 1/2, Poznań, Poland,  
e-mail: tomasz.urbanowicz  
@skpp.edu.pl

Copyright by the  
Author(s), 2021

Kardiologia Pol. 2021;  
79 (5): 579–580;  
DOI: 10.33963/KP.15880

Received:  
December 7, 2020

Revision accepted:  
March 2, 2021

Published online:  
March 16, 2021

Percutaneous coronary interventions (PCI) have an established position in the management of patients presenting with acute coronary syndromes [1]. Rare, but serious adverse events may be related to stents/wire distortions [2, 3].

We present a case of a 67-year-old male who was admitted to a hospital with anterior wall ST-elevation myocardial infarction. Urgent coronary catheterization revealed left anterior descending artery (LAD) occlusion close to diagonal branch origin (Figure 1A). Middle segments of circumflex (CX) and right coronary (RCA) arteries were also significantly stenotic (Figure 1B). The heart team decided to perform emergent LAD angioplasty.

The bolus of 7.9 ml of INN-eptifibatid was administered and followed by continuous infusion with a 14 ml/h rate. The drug-eluting stent (Xience 3.0 × 28 mm) was implanted into LAD. The drug-eluting stent (Xience 3.0 × 28 mm) was implanted into LAD. After stent implantation, a part of the wire was entrapped in the coronary artery. The metallic coil covering the core of the angioplasty wire was left in the proximal part of LAD and protruded into the aortic root.

The patient was referred for emergency surgery. The procedure was performed through median sternotomy in cardiopulmonary bypass. After transverse aortotomy, the aortic root lumen was inspected, and the metallic coil was localized (Figure 1C). As the foreign body of 7 cm in length was irremovable, it was transected and

left in the proximal portion of the left main coronary artery (Figure 1D). The operators decided to perform revascularization of LAD, CX, and RCA. The saphenous vein bypass grafts (SVBG) were performed into CX and RCA and the left internal mammary (LIMA) was anastomosed into LAD with continuous 7-0 monofilament suture. The estimated blood flow was 7 ml/min with pulsation index (PI) of 3.4 in LIMA-to-LAD 39 ml/min with PI 1.3 in SVBG-to-CX and 43 ml/min with PI 1.1 in SVBG-to-RCA grafts, respectively.

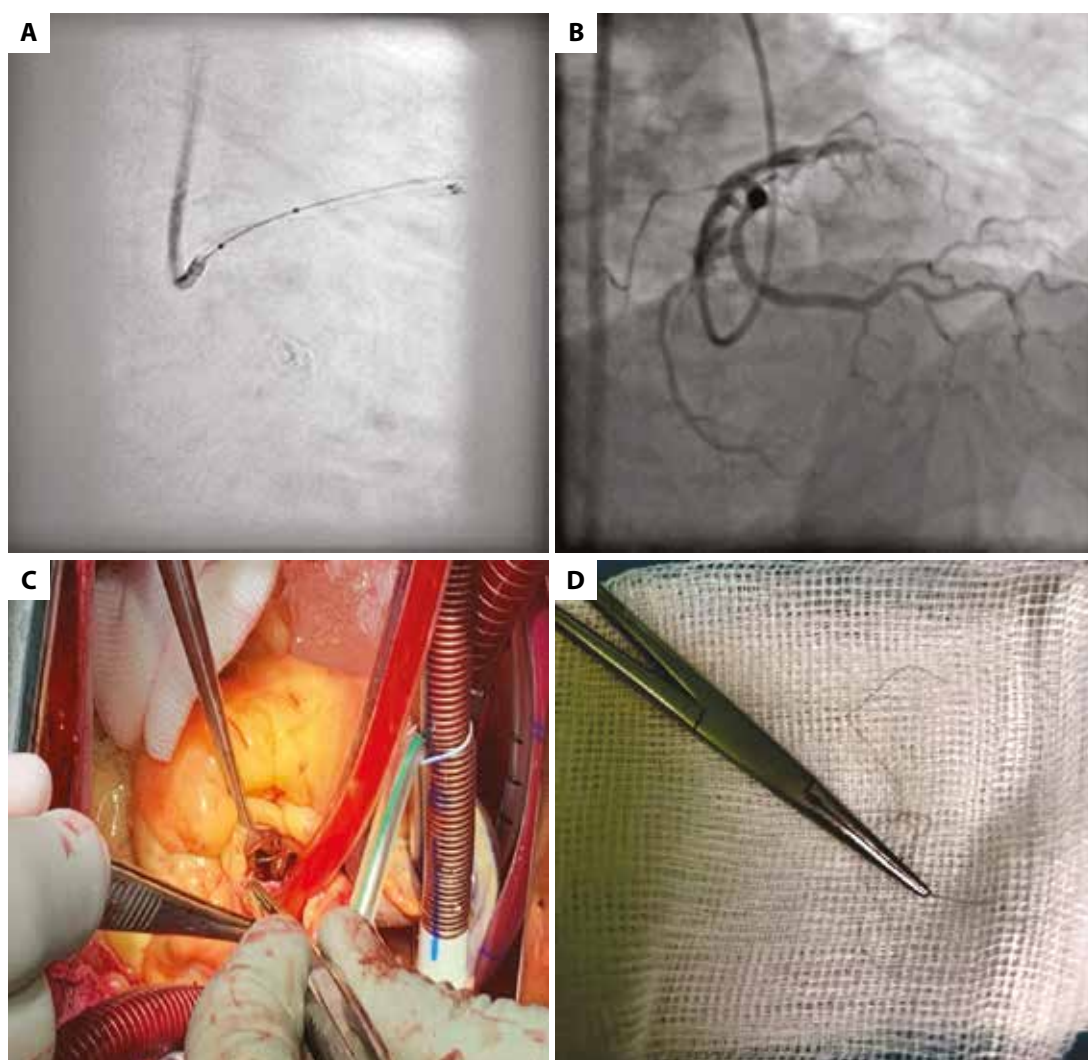
The surgical approach allows achieving complete revascularization in acute coronary syndromes. Postoperative bypass blood flow measurements provide significant information about the quality of performed anastomoses.

## Article information

**Conflict of interest:** None declared.

**Open access:** This article is available in open access under Creative Commons Attribution-Non-Commercial-No Derivatives 4.0 International (CC BY-NC-ND 4.0) license, allowing to download articles and share them with others as long as they credit the authors and the publisher, but without permission to change them in any way or use them commercially. For commercial use, please contact the journal office at [kardiologiapolska@ptkardio.pl](mailto:kardiologiapolska@ptkardio.pl).

**How to cite:** Urbanowicz T, Perek B, Ołasińska-Wiśniewska A, et al. Surgical revascularization in STEMI patient after failed percutaneous coronary interventions with broken angioplasty wire protruding into the aortic root. *Kardiologia Pol.* 2021; 79(5): 579–580, doi: 10.33963/KP.15880.



**Figure 1.** **A.** Angiography of acute left descending artery occlusion with metallic coil of the guidewire left in the proximal part. **B.** Right coronary artery angiography. **C.** Intraoperative view into aortic root with metallic coil. **D.** 7 cm long metallic coil removed from the aortic lumen

## REFERENCES

1. Ibanez B, James S, Agewall S, et al. 2017 ESC Guidelines for the management of acute myocardial infarction in patients presenting with ST-segment elevation. *Kardiol Pol.* 2018; 76(2): 229–313, doi: [10.5603/kp.2018.0041](https://doi.org/10.5603/kp.2018.0041).
2. Kadohira T, Schwarcz AI, De Gregorio J. Successful retrieval of an entrapped guide wire between a deployed coronary stent and severely calcified vessel wall using excimer laser coronary atherectomy. *Catheter Cardiovasc Interv.* 2015; 85(2): E39–E42, doi: [10.1002/ccd.25664](https://doi.org/10.1002/ccd.25664), indexed in Pubmed: [25195662](https://pubmed.ncbi.nlm.nih.gov/25195662/).
3. Gziut AI, Seweryniak P. Dissection of coronary artery during primary PCI in a patient with rheumatoid arthritis. *Kardiol Pol.* 2007; 65(11): 1389–1390.