

Acute myocardial infarction due to paradoxical embolism in a young man with ostium secundum atrial septal defect

Wojciech Skorupski¹, Olga Trojnaraska¹, Agnieszka Bartczak-Rutkowska¹, Wiesław Sikora², Maciej Lesiak¹, Marek Grygier¹

¹ 1st Department of Cardiology, Poznan University of Medical Sciences, Poznań, Poland

² Department of Cardiology, Specialist Hospital in Piła, Piła, Poland

A 37-year-old man was admitted to the hospital with typical severe retrosternal pain. He did not have any risk factors for coronary heart disease or a family history of cardiovascular diseases. Electrocardiography showed a sinus rhythm of 60 bpm, high T waves in leads V₃–V₆, with inverted T waves in leads III and V₁. Laboratory tests revealed significantly elevated troponin levels (417 pg/ml [reference range, 0–14 pg/ml]) and elevated creatine kinase–MB levels (21.53 ng/ml [reference range, 0–4.87 ng/ml]). Acute myocardial infarction without ST-segment elevation was diagnosed. Immediate coronary angiography was performed. It showed embolic material causing almost subtotal occlusion (95%) with slowed flow in the first septal branch of the left anterior descending artery (FIGURE 1A). Other arteries were normal without significant stenoses.

Balloon angioplasty of the septal artery with Mini TREK 1.5 × 15 mm 14 atm (Abbott) was performed, with good angiographic result (FIGURE 1B and 1C). Echocardiography showed no contraction abnormalities of the left ventricle with good ejection fraction, but it also revealed right ventricular enlargement with a suspected atrial septal defect (ASD). Transesophageal echocardiography confirmed the presence of ostium secundum ASD with dimensions of 11 × 13 mm and left-to-right leak (FIGURE 1D and 1E).

The patient was discharged from the hospital in stable clinical condition without angina. He was recommended the use of zofenopril and atorvastatin. Due to embolic, nonatherosclerotic cause of myocardial infarction, a decision to start the anticoagulant warfarin instead of

antiplatelet therapy was made. Laboratory tests did not show any coagulation abnormalities. The patient was referred for percutaneous closure of the defect. After 1 month, he was readmitted to the hospital, and a successful ASD closure procedure was performed with 14-mm Amplatzer septal occluder (Abbott) (FIGURE 1F).

One of the indications for interventional treatment of ASD is the presence of paradoxical embolism. Most often, it manifests itself in the form of a stroke or an embolism in other peripheral vessels.¹ We present a rare case (probably the first in Polish literature) of paradoxical embolism that caused a myocardial infarction in a young patient without any cardiovascular risk factors. In such a case, percutaneous closure of ASD should be indicated and is believed to be associated with a reduction in the recurrence of not only cerebrovascular events but also peripheral embolism.^{2–4} A suspicion of paradoxical embolism should be raised in young patients with acute myocardial infarction, without cardiovascular risk factors, and without current atherosclerotic disease.

ARTICLE INFORMATION

CONFLICT OF INTEREST None declared.

OPEN ACCESS This is an Open Access article distributed under the terms of the Creative Commons Attribution-NonCommercial-NoDerivatives 4.0 International License (CC BY-NC-ND 4.0), allowing third parties to download articles and share them with others, provided the original work is properly cited, not changed in any way, distributed under the same license, and used for noncommercial purposes only. For commercial use, please contact the journal office at kardiologiapolska@ptkardio.pl.

HOW TO CITE Skorupski W, Trojnaraska O, Bartczak-Rutkowska A, et al. Acute myocardial infarction due to paradoxical embolism in a young man with ostium secundum atrial septal defect. *Kardiol Pol.* 2019; 77: 645–646. doi:10.33963/KP.14833

Correspondence to:

Wojciech Skorupski, MD,
1st Department of Cardiology,
Poznan University of Medical
Sciences, Poznań, Poland,
ul. Długa 1/2, 61-848 Poznań,
Poland, phone: +48 61 854 9222,
email: wojtek.skorupski@wp.pl
Received: March 4, 2019.

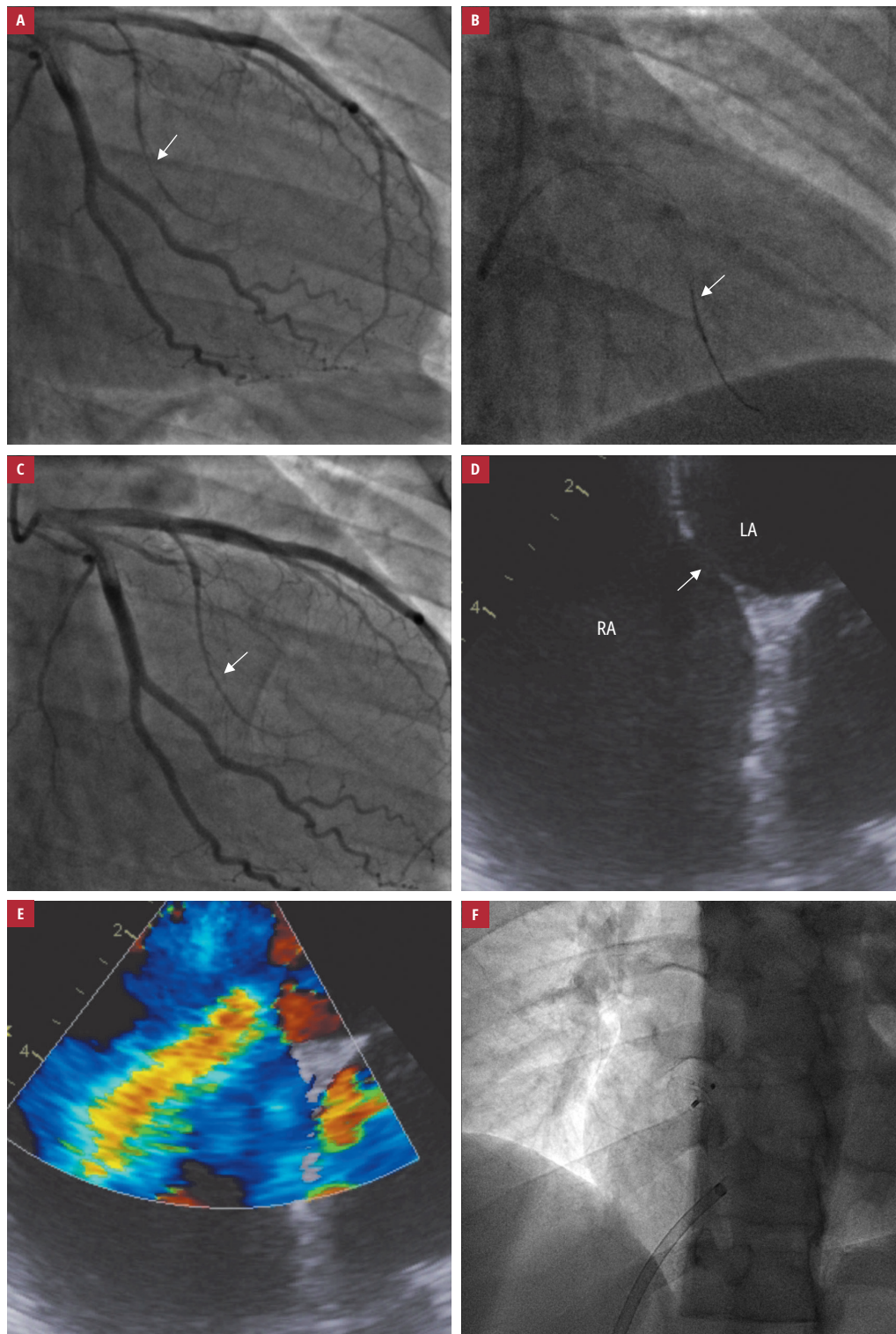
Revision accepted: April 4, 2019.

Published online: May 17, 2019.
Kardiol Pol. 2019; 77 (6): 645–646
doi:10.33963/KP.14833

Copyright by Polskie Towarzystwo
Kardiologiczne, Warszawa 2019

FIGURE 1 **A** – coronary angiography: right anterior oblique caudal view of the left coronary artery, showing subtotal occlusion in the first septal branch of the left anterior descending artery (arrow); **B** – coronary angiography: balloon angioplasty of the septal artery (arrow); **C** – coronary angiography showing the first septal artery after balloon angioplasty (arrow); **D** – transesophageal echocardiography showing atrial septal defect (arrow); **E** – transesophageal echocardiography: color Doppler assessment of atrial septal defect; **F** – atrial septal defect after closure with an Amplatzer septal occluder

Abbreviations: LA, left atrium; RA, right atrium



REFERENCES

- 1 Windecker S, Stortecky S, Meier B, et al. Paradoxical embolism. *J Am Coll Cardiol.* 2014; 64: 403-415.
- 2 Bartz PJ, Cetta F, Cabalka AK, et al. Paradoxical emboli in children and young adults: role of atrial septal defect and patent foramen ovale device closure. *Mayo Clin Proc.* 2006; 81: 615-618.
- 3 Witzke CF, Rengifo-Moreno P, Morris DL, et al. Patent foramen ovale transcatheter closure vs. medical therapy on recurrent vascular events: a systematic review and meta-analysis of randomized controlled trials. *Eur Heart J.* 2013; 34: 3342-3352.
- 4 Andreas W, Peter J, Marie-Luise M, et al. Long-term propensity score-matched comparison of percutaneous closure of patent foramen ovale with medical treatment after paradoxical embolism. *Circulation.* 2012; 125: 803-812.