

False-positive episodes detected by an implantable loop recorder

Maciej Grymuza, Aleksandra Ciepłucha, Agnieszka Katarzyńska-Szymańska, Romuald Ochotny, Maciej Lesiak, Przemysław Mitkowski

1st Department of Cardiology, Poznan University of Medical Sciences, Poznań, Poland

The use of implantable loop recorders (ILRs) has gained increasing importance in the diagnostic workup of unexplained syncope. The current guidelines recommend ILR implantation in patients with recurrent syncope of uncertain origin and no high-risk factors (according to those guidelines) as well as in patients with high-risk factors in whom diagnostic workup did not indicate any cause of syncope.¹ Implantable loop recorders can detect and record episodes of bradycardia, asystole, high ventricular rate, atrial fibrillation, and patient-triggered events. Data are either stored in device memory until the next visit or transmitted to remote monitoring systems.

We report the case of a patient with episodes of inappropriate detection of long-lasting asystole. A 63-year-old man was admitted to our department because of a history of infrequent syncope. Previous cardiac and neurological evaluation did not reveal the underlying cause. An ILR (BIOMONITOR III, Biotronik SE & Co, Berlin, Germany) was implanted, and the R wave amplitude at implantation was 1.47 mV. The Home Monitoring System (Biotronik) was activated. A few weeks after implantation, 5 episodes of asystole lasting from 6 to 50 seconds within 2 weeks were recorded by the Home Monitoring System. After each event, a phone call was performed, but the patient did not report any symptoms during episodes. Moreover, episodes occurred at different times of the day, while performing various activities like watching television, driving, or riding a stationary bicycle. An exemplary episode recorded at 7:28 while driving is illustrated in **FIGURE 1**. We regarded those events as cases of false-positive asystole detection. Several

premises lead to this conclusion: the onset and the end of the supposed asystole (**FIGURE 1A** and **1C**), the waveform after an episode (**FIGURE 1C**), and, finally, completely asymptomatic episodes despite lasting for almost a minute. Such a long asystole is very unlikely to be asymptomatic. Moreover, artifacts at the onset and the end of subcutaneous electrocardiogram (SECG) are suggestive of amplifier saturation by direct current flow. Unfortunately, in-depth investigation did not clarify the cause of the event. Despite those artifacts, the ILR was left in its previous location, and each episode was evaluated in light of reported symptoms. In this aspect, implementing remote monitoring was crucial, because fast episode reporting facilitates communication with the patient to confirm the relationship between symptoms and an SECG finding. Previous studies have reported false arrhythmia detection by ILRs due to: sudden reductions in the R wave signal amplitude, undersensing by loss of signal caused by device amplifier saturation, oversensing, myopotential, and noises.^{2,3} However, case reports rarely describe such long-lasting false-positive asystole events found in Biotronik ILRs.^{4,5} In conclusion, episodes recorded by ILRs should be carefully interpreted considering the SECG waveform and clinical manifestations of detected events.

ARTICLE INFORMATION

CONFLICT OF INTEREST None declared.

OPEN ACCESS This is an Open Access article distributed under the terms of the Creative Commons Attribution-Non Commercial-No Derivatives 4.0 International License (CC BY-NC-ND 4.0), allowing third parties to download articles and share them with others, provided the original work is properly cited, not changed in any way, distributed under the same license, and used for non-commercial purposes only. For commercial use, please contact the journal office at kardiologiapolska@ptkardio.pl.

Correspondence to:
Maciej Grymuza, MD,
Department of Cardiology,
Poznan University of Medical
Sciences, ul. Długa 1/2,
61-848 Poznań, Poland,
phone: +48 61 854 9146, email:
maciej.grymuza@skpp.edu.pl
Received: June 8, 2020.
Revision accepted: July 17, 2020.
Published online: July 24, 2020.
Kardiol Pol. 2020; 78 (11): 1171-1173
doi:10.33963/KP.15531
Copyright by the Author(s), 2020

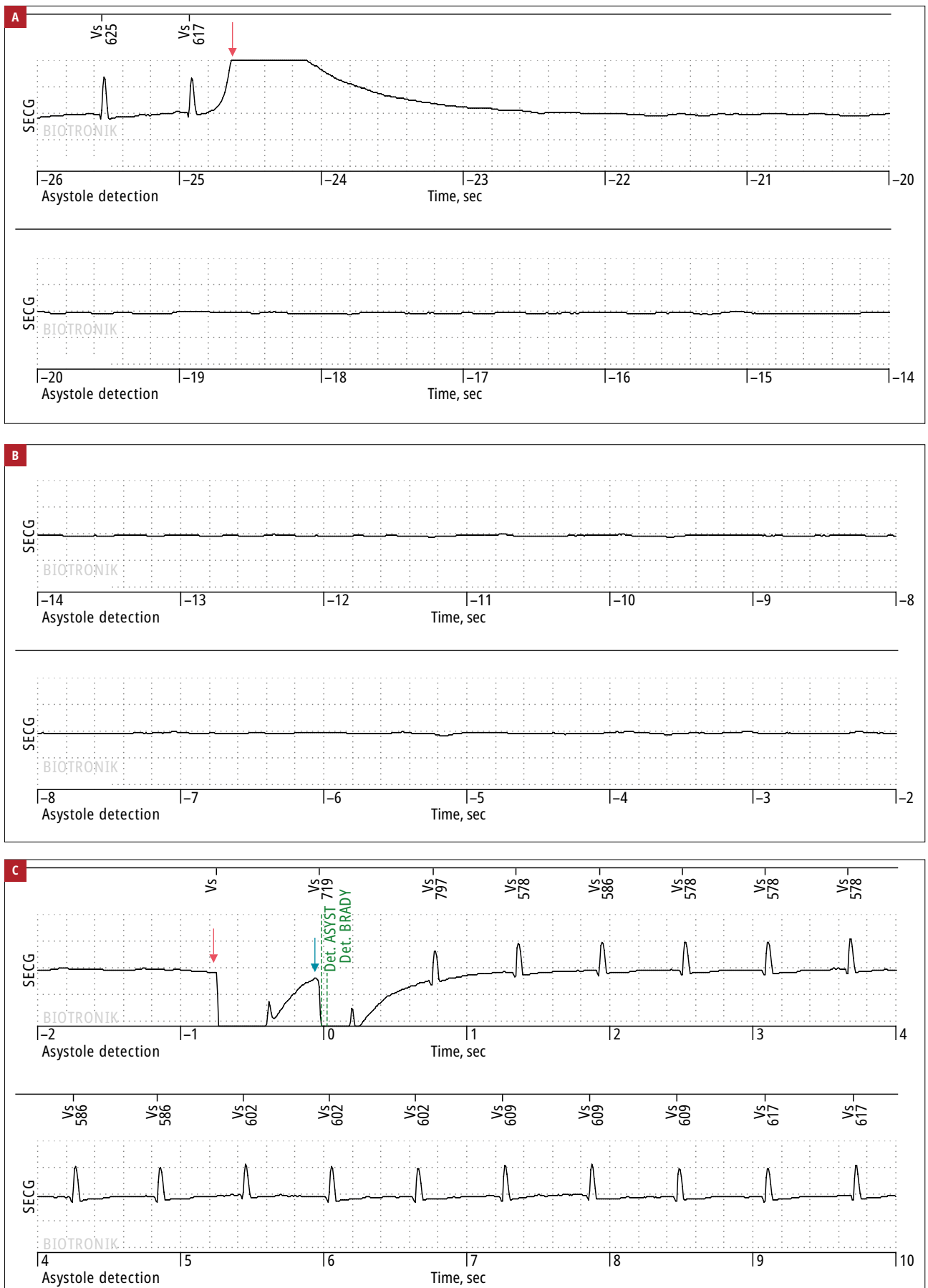


FIGURE 1 Subcutaneous electrocardiogram (SECG) of an episode inappropriately qualified as an asystole by an implantable loop recorder (the red arrow indicates the atypical beginning and end of the supposed asystole, and the blue arrow shows the course of the curve following the episode)
 Abbreviations: Det. ASYST, detected asystole; Det. BRADY, detected bradycardia

HOW TO CITE Grymuza M, Cieplucha A, Katarzyńska-Szymańska A, et al. False-positive episodes detected by an implantable loop recorder. *Kardiol Pol.* 2020; 78: 1171-1173. doi:10.33963/KP.15531

REFERENCES

- 1 Brignole M, Moya A, de Lange FJ, et al. 2018 ESC Guidelines for the diagnosis and management of syncope. *Kardiol Pol.* 2018; 76: 1119-1198.
- 2 Brignole M, Black CLB, Thomsen PEB, et al. Improved arrhythmia detection in implantable loop recorders. *J Cardiovasc Electrophysiol.* 2008; 19: 928-934.
- 3 Chrysostomakis SI, Simantirakis EN, Marketou ME, et al. Implantable loop recorder undersensing mimicking complete heart block. *Europace.* 2002; 4: 211-213.
- 4 Bortnik M, Occhetta E, Magnani A, et al. Inappropriate asystole detection in early postoperative phase after loop recorder implantation. *ISRN Cardiol.* 2011; 2011: 146062.
- 5 Ali H, Sorgente A, Daleffe E, Cappato R. Asystole detected by implantable loop recorders: true or false? *Ann Noninvasive Electrocardiol.* 2014; 19: 595-597.