

# A novel electrogram (EGM)-based algorithm for assessing the location of the critical isthmus in complex atrial re-entry

Grzegorz Ciszewski<sup>1</sup>, Patrycja Pruszkowska<sup>2</sup>, Oskar Kowalski<sup>2,3</sup>

1 Boston Scientific Poland, Warsaw, Poland

2 1st Department of Cardiology, Congenital Heart Disease and Electrotherapy, Silesian Centre for Heart Diseases, Zabrze, Poland

3 Department of Dietetics, School of Public Health in Bytom, Medical University of Silesia, Katowice, Poland

Atypical atrial flutter (AFL) is an organized supraventricular macroreentrant tachycardia often originating from the left atrium (LA) after previous cardiac interventions such as pulmonary vein isolation.<sup>1,2</sup> Common therapeutic strategy is to identify the critical isthmus and apply radiofrequency energy to break the re-entry circuit,<sup>3</sup> which can be challenging due to the complexity of activation.

A 73-year-old woman with a documented history of atrial fibrillation and atrial flutter had undergone pulmonary vein isolation cryoablation and 3 months later was diagnosed with atypical AFL. The patient was admitted to the electrophysiology unit and scheduled for radiofrequency ablation. During the electrophysiological study, AFL with the cycle length (CL) of 460 milliseconds was easily inducible by programmed pacing protocol.

Tachycardia was mapped using the Orion multipolar (64 electrodes with an area of 0.4 mm<sup>2</sup>; 2.5 mm spacing) basket catheter and the Rhythmia HDx mapping system (Boston Scientific, Marlborough, Massachusetts, United States). Automated acquisition mapping mode was used with default beat acceptance criteria: cycle length, propagation reference ( $\Delta R$ ), respiration phase.

The voltage map showed a very low voltage area in the anterior wall and an extensive scarred area (<0.1 mV) on the posterior wall (FIGURE 1A). The activation map (12 300 points; confidence level, 0.15 mA) revealed the re-entry circuit around the scar in the posteroseptal part of the LA. (FIGURE 1B; Supplementary material, Video S1)

A novel intelligent electrogram (EGM)-based algorithm LUMIPOINT (Boston Scientific) is a set of

software features in the Rhythmia mapping system that detects all activations present in every electrogram irrespective of local activation time. The SKYLINE graph value (FIGURE 1E) represents the area activated at each point of the tachycardia cycle.<sup>4</sup>

The peaks on the SKYLINE histogram correspond to the large areas of atrial activation whereas the valleys correlate with the narrower, usually slow conducting zones, which makes SKYLINE suitable in assessment of the location of the re-entry isthmus.

The LUMIPOINT activation window was placed at the SKYLINE lowest point (FIGURE 1E) highlighting the upper borderline of the scar as the potential isthmus (FIGURE 1D).

Highly fractionated low-voltage signals were found in the highlighted area (FIGURE 1C) and radiofrequency ablation was performed (30 W) with a 7.5-F navigated irrigated ablation catheter (IntellaNav MiFi OI, Boston Scientific). Tachycardia terminated abruptly after 11 seconds of radiofrequency with recorded local impedance drop of 8 $\Omega$ . Further 540 seconds of radiofrequency were delivered in the area to solidify the lesion.

Pacing protocol induced another tachycardia with the CL of 420 milliseconds and a different activation pattern of the coronary sinus catheter indicating the presence of an independent circuit. The second activation map (13 312 points) demonstrated the LA was activated through a double loop pattern with smaller loop around the interior wall scar and the large loop encircling the mitral valve (Supplementary material, Figure S1A and Video S2).

The SKYLINE histogram (Supplementary material, Figure S1D) was again used to identify

## Correspondence to:

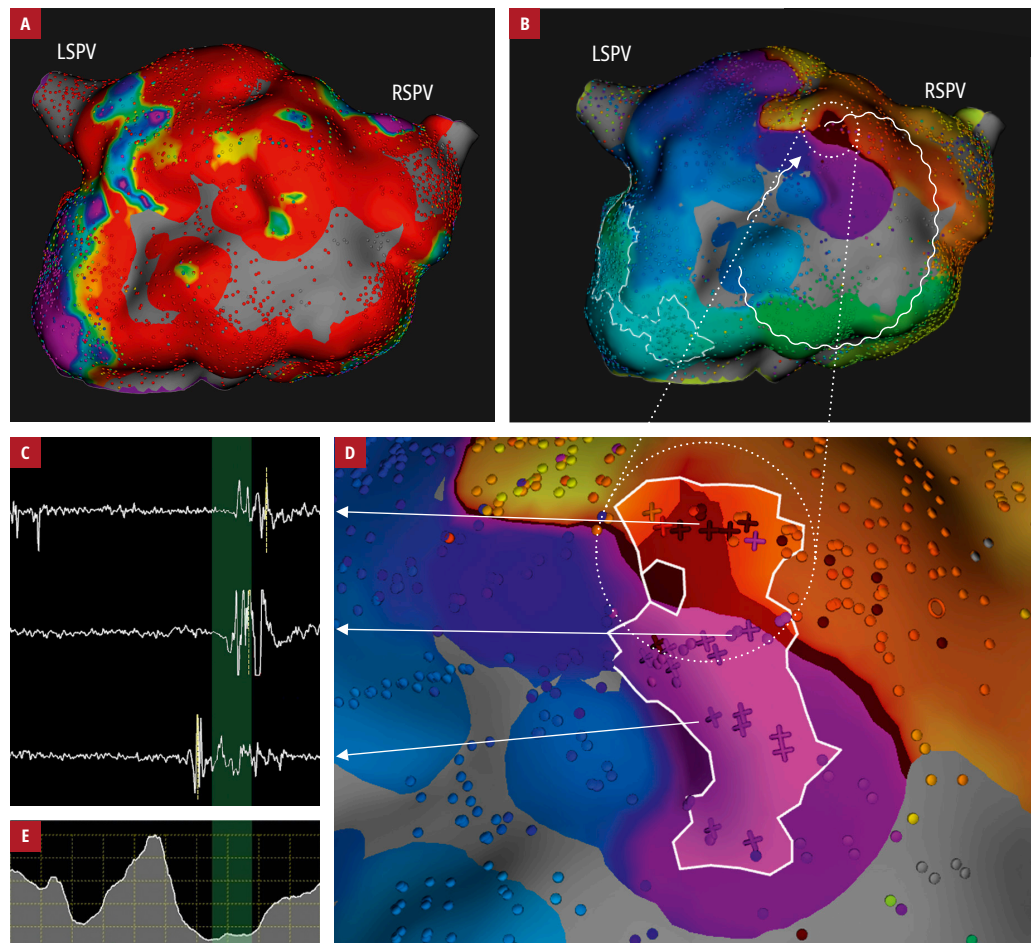
Grzegorz Ciszewski, MS, IBHRE  
CEPS, Boston Scientific Poland  
Electrophysiology, al. Jana Pawła  
II 22, 00-133 Warszawa, Poland,  
phone: +48 608 444 457, email:  
grzegorz.ciszewski@bsci.com  
Received: April 2, 2020.

Revision accepted: June 16, 2020.

Published online: June 23, 2020.

Kardiol Pol. 2020; 78 (9): 941-942  
doi:10.33963/KP.15445

Copyright by the Author(s), 2020



**FIGURE 1** **A** – voltage map; color range: red  $< 0.1\text{ mV}$ – $0.5\text{ mV}$  < purple; **B** – left atrial activation map during first tachycardia (cycle length, 460 ms) acquired using the Rhythmia HDx Mapping System; posterior view; confidence mask  $> 0.15\text{ mV}$ ; **C** – local fractionated electrograms recorded in the isthmus area; **D** – critical isthmus area in the posteroseptal part of the left atrium highlighted by LUMIPOINT; ablation target 1; **E** – SKYLINE graph. LUMIPOINT activation window (green bar) covers the lowest histogram value highlighting the potential isthmus.

Abbreviations: LSPV, left superior pulmonary vein; RSPV, right superior pulmonary vein

the common isthmus. Highly fractionated electrograms (Supplementary material, *Figure S1B*) in the area highlighted by the algorithm (Supplementary material, *Figure S1C*) confirmed the location of the common isthmus in the anterior wall. Targeted radiofrequency ablation (35 W) terminated tachycardia in 9 seconds with local impedance drop of  $10\Omega$ . Further 360 seconds of radiofrequency were delivered to solidify the lesion. No arrhythmia was inducible at that moment. 24-hour postprocedure Holter monitoring recorded sinus rhythm 49 to 101 bpm with no episodes of arrhythmia and the patient was discharged from the hospital the next day. In the 3-month follow-up (telemedicine interview due to coronavirus disease 2019), she remained asymptomatic.

In our case, the LUMIPOINT, an intelligent EGM-analyzing algorithm, used with the Ultra-HD mapping system was useful in understanding the underlying mechanism of the complex re-entry and accelerated the decision regarding the ablation strategy.

## SUPPLEMENTARY MATERIAL

Supplementary material is available at [www.mp.pl/kardiologiapolska](http://www.mp.pl/kardiologiapolska).

## ARTICLE INFORMATION

**CONFLICT OF INTEREST** GC is an employee of Boston Scientific Poland.

**OPEN ACCESS** This is an Open Access article distributed under the terms of the Creative Commons Attribution-NonCommercial-NoDerivatives 4.0 International License (CC BY-NC-ND 4.0), allowing third parties to download articles and share them with others, provided the original work is properly cited, not changed in any way, distributed under the same license, and used for noncommercial purposes only. For commercial use, please contact the journal office at [kardiologiapolska@ptkardio.pl](mailto:kardiologiapolska@ptkardio.pl).

**HOW TO CITE** Ciszewski G, Pruszkowska P, Kowalski O. A novel electrogram (EGM)-based algorithm in the assessment of critical isthmus location in complex atrial re-entry. *Kardiologia Polska*. 2020; 78: 941-942. doi:10.33963/KP.15445

## REFERENCES

- 1 Cosío FG. Atrial flutter, typical and atypical: a review. *Arrhythm Electrophysiol Rev*. 2017; 6: 55-62.
- 2 Sághy L, Tutuianu C, Szilágyi J. Atrial tachycardias following atrial fibrillation Ablation. *Curr Cardiol Rev*. 2015; 11: 149-156.
- 3 Orczykowski M, Borowiec K, Biernacka E, et al. Ablation of atrial tachyarrhythmias late after surgical correction of tetralogy of Fallot: long-term follow-up. *Kardiologia Polska*. 2018; 76: 1097-1105.
- 4 Takigawa M, Martin CA, Derval N, et al. Insights from atrial surface activation throughout atrial tachycardia cycle length: a new mapping tool. *Heart Rhythm*. 2019; 16: 1652-1660.